RADIOLOGY
HONG KONG 2026

34th Annual Scientific Meeting of Hong Kong College of Radiologists



AI in the Era of Personalised Medicine

21-22
November 2026
(SAT & SUN)
Hong Kong Academy of Medicine
Jockey Club Building,
Hong Kong SAR, China

Subspecialty Focus:
Gynaecological Malignancies
Women & Fetal Imaging

Multidisciplinary Symposium:
Breast Cancer

KSR-HKCR Conjoint Session:
Interventional Radiology

For details
WWW.HKCR-ASM.ORG

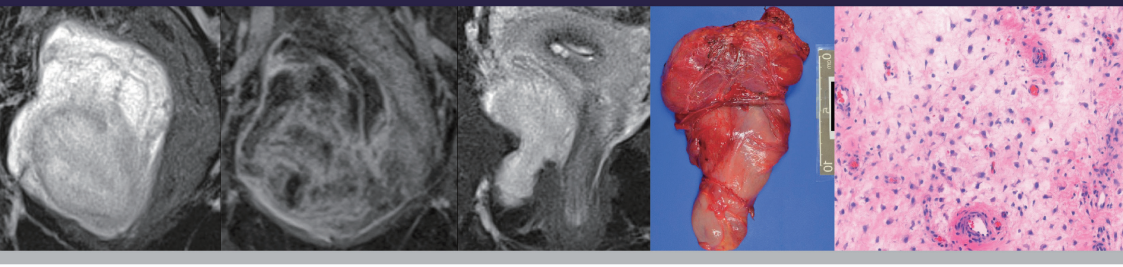

2027 AIRP Course in Hong Kong

21st – 23rd May 2027 (Friday to Sunday)
Hong Kong Academy of Medicine Jockey Club Building
Hong Kong SAR, China

Subspecialty Focus:

Genitourinary Radiology
Gastrointestinal Imaging
Breast Imaging

The renowned, unique training course for the pathophysiologic understanding of disease as the basis for radiologic interpretation

Learn more at www.hkcr.org and www.airp.org for more updates !!

HONG KONG COLLEGE OF RADIOLOGISTS 香港放射科醫學院

American College of Radiology™
Institute for Radiologic Pathology

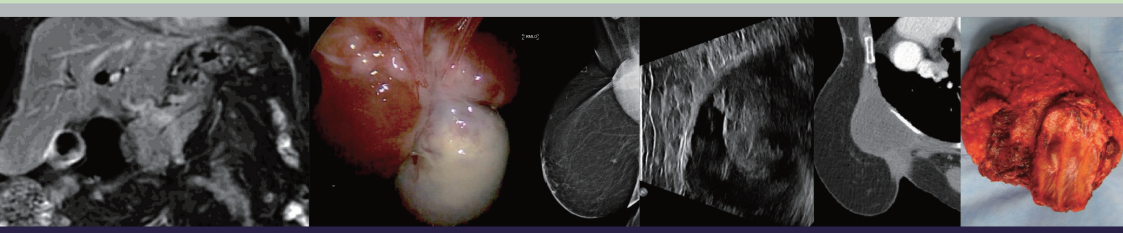

34th Annual Scientific Meeting of Hong Kong College of Radiologists

21ST- 22ND November 2026 (Saturday & Sunday)

Hong Kong Academy of Medicine Jockey Club Building
Hong Kong SAR, China

Welcome Message	2
Organising Committee	3
Faculty	6
HKCR Distinguished Contribution Award	12
Conference Information	14
CME/CPD Accreditation	17
Venue Maps	18
Acknowledgement	20
Programme-at-a-Glance	22
Scientific Programme	24
Abstracts Index - Lectures	35
Abstracts Index - Proffered Papers	39
Abstracts Index - Electronic Posters	43
Abstracts of Lectures	53
Abstracts of Proffered Papers	111
Abstracts of Electronic Posters	136
Technical Exhibitions	202
Supporting Organisations' Information	205
Acknowledgement for Supporting Organisations	225
Disclaimer	227



Message from President of Hong Kong College of Radiologists

It is my great honor to welcome you to the **34th Annual Scientific Meeting of the Hong Kong College of Radiologists**. This year's event once again provides a dynamic forum for exchanging expertise and advancing knowledge across **Radiology, Clinical Oncology, and Nuclear Medicine.**

Over the course of these two days, we will feature lectures centered on **Gynaecological Malignancies** and **Women & Fetal Imaging**. The program also includes a **Multidisciplinary Symposium on Breast Cancer**, a **KSR-HKCR Conjoint Session on Interventional Radiology**, and a **Global AI Symposium exploring AI in the Era of Personalised Medicine**, each underscoring the importance of cross-disciplinary collaboration in delivering comprehensive, high-quality patient care. In addition, the meeting offers a **Young Fellows Forum, proffered paper sessions, an electronic poster exhibition, a film quiz, and a technical exhibition**. As always, this annual gathering offers a valuable opportunity to connect with local and international experts, industry representatives, and exhibitors, enriching our professional networks.

Finally, on behalf of the **Hong Kong College of Radiologists**, I would like to express my sincere gratitude to the **Organizing Committee, our Secretariat, helpers, and corporate partners** for their steadfast support over the years.

Dr. Ivan Yiu Chung WONG

President, Hong Kong College of Radiologists

HKCR COUNCIL

Founding President & Senior Advisor	Dr. Lilian LEONG	
President	Dr. Ivan Yiu Chung WONG	
Immediate Past President	Dr. Chun Key LAW	
Senior Vice-President	Dr. Kwok Keung YUEN	
Vice-President	Dr. Danny Hing Yan CHO	
Warden	Dr. Wai Lun POON	
Honorary Treasurer	Dr. Ka On LAM	
Honorary Secretary	Dr. Kevin Kin Fen FUNG	
Council Members	Dr. James Chung Hang CHOW	Dr. Billy Ming Hei LAI
	Dr. Charles Tsz Kit CHOW	Dr. Hector Tin Ging MA
	Dr. Chi Yeung CHU	Dr. Inda Sung SOONG
	Dr. Wai Yin HO	Dr. San Ming YU
	Dr. Kai Yan KWOK	
Honorary Legal Advisor	Mrs. Mabel LUI	
Honorary Auditor	Mr. Charles CHAN	

ORGANISING COMMITTEE

Chairman	Dr. Danny Hing Yan CHO	
Honorary Secretary	Dr. Kenneth Chun Wai WONG	
Members	Dr. Kelvin King Hei BAO	Dr. Shiobhon Yiu LUK
	Dr. Adrian Wai CHAN	Dr. Florence Siu Ting MOK
	Dr. Keith Wan Hang CHIU	Dr. Kwok Sing NG
	Dr. Wesley Yuen Lum CHOI	Dr. Ming Yen NG
	Dr. Kevin Kin Fen FUNG	Dr. Keith Nin Yuan PAN
	Dr. David Ryan JOHNSON	Dr. Wai Lun POON
	Dr. Elaine Yee Ling KAN	Dr. Sunny Kin Sun TSE
	Dr. Billy Ming Hei LAI	Dr. Barry Bar Wai WO
	Dr. Barry Siu Ting LEUNG	Dr. Edwin Chun Yin WONG
	Dr. Angela On Chee LI	

GLOBAL AI SYMPOSIUM ORGANISING COMMITTEE

Chairman Dr. Lilian LEONG

Members

Dr. Keith Wan Hang CHIU
Dr. Danny Hing Yan CHO
Dr. Kevin Kin Fen FUNG
Dr. Neeraj Ramesh MAHBOOBANI
Dr. Wai Lun POON

SCIENTIFIC SUBCOMMITTEE

Chairman Dr. Kevin Kin Fen FUNG

Members

Dr. Kelvin King Hei BAO
Dr. Adrian Wai CHAN
Dr. Danny Hing Yan CHO
Dr. Wesley Yuen Lum CHOI
Dr. Charles Tsz Kit CHOW
Dr. Eliza Po Yan FUNG
Dr. David Ryan JOHNSON
Dr. Elaine Yee Ling KAN
Dr. Kenneth Hoi Ming KWOK
Dr. Billy Ming Hei LAI
Dr. Jeremy Hugh Yen-hey LAU
Dr. Neeraj Ramesh MAHBOOBANI
Dr. Florence Siu Ting MOK
Dr. Kwok Sing NG
Dr. Keith Nin Yuan PAN
Dr. Wai Lun POON
Dr. Jacqueline Ching Man SITT
Dr. Tsz Him SO
Dr. Inda Sung SOONG
Dr. Sunny Kin Sun TSE
Dr. Barry Bar Wai WO
Dr. Amy Ho Ching WONG
Dr. Edwin Chun Yin WONG
Dr. Kenneth Chun Wai WONG

PROGRAMME SUBCOMMITTEE

Chairman Dr. Shiobhon Yiu LUK

Members

Dr. Adrian Wai CHAN
Dr. Kevin Kin Fen FUNG
Dr. Elaine Yee Ling KAN
Dr. Neeraj Ramesh MAHBOOBANI
Dr. Amy Ho Ching WONG
Dr. Edwin Chun Yin WONG

PUBLICATION SUBCOMMITTEE

Chairman Dr. Barry Siu Ting LEUNG

Members

Dr. Claudia CHEUNG
Dr. Yoyo Hiu Wah CHIU
Dr. Wesley Yuen Lum CHOI
Dr. Kevin Kin Fen FUNG
Dr. Luke Tin Yan LEE
Ms. Dorothy Ka Ying WONG
Dr. Gloria Ting WONG

FILM QUIZ ORGANISERS

Chairperson Dr. Keith Nin Yuan PAN

Coordinators

Dr. Florence Pui Yi WONG (General Radiology & Nuclear Medicine)
Dr. David Ryan JOHNSON (Clinical Oncology)

Contributors

Dr. Chau Kuen CHAN
Dr. Lok Yee CHAN
Dr. Alex Sik Chung CHING
Dr. Cheuk Sang HO
Dr. David Ryan JOHNSON
Dr. Pak Lun LAM
Dr. Eugene Sean LO
Dr. Chetan MOREY
Dr. Edmond King Nam WONG

PHOTOGRAPHY TEAM

Team Leader Dr. Billy Ming Hei LAI

Members

Dr. Chun Ho CHAN
Dr. Lok Yee CHAN
Dr. Richard Chun Kit CHAN
Dr. Stanley Kai-tung HAU
Dr. Cheuk Sang HO
Dr. Wing Hong JIM
Dr. Bo Yee LEE
Dr. Hiu Yung LEUNG
Dr. Andrew Man Kwun LI
Dr. Natalie Kar Yan MOK
Dr. Amrit PUN
Dr. Chun Lang TANG
Dr. Lok Hei TSE
Dr. Chun Ting WANG
Dr. Ching Tung WONG
Dr. Edmond King Nam WONG
Dr. Katherine WONG
Dr. Man Yee WONG
Dr. Lap Yin WU
Dr. Chin Hong YICK

INTERNATIONAL FACULTY

Dr. Hiok Yang CHAN
Associate Consultant Radiologist
Department of Radiology
Changi General Hospital
Singapore



Prof. Zhengyu JIN
Professor of Radiology
Radiology Department
Peking Union Medical College Hospital
China



Dr. Chamaree CHUAPETCHARASOPON
President
Asian Oceanian Society of Radiology
Thailand



Dr. Hye Doo JUNG
Chief Medical Director
Department of Radiology
Seoul 88 Clinic
South Korea



Dr. Rameysh DANOVANI
Senior Consultant Radiologist
Changi General Hospital
Singapore



Dr. Jihoon KIM
Professor
Department of Radiology and Research Institute of Radiology
University of Ulsan College of Medicine
Asan Medical Center
South Korea



Dr. Stephen HARDEN
President
The Royal College of Radiologists
United Kingdom



Prof. Sung-Bae KIM
Professor
Department of Oncology
University of Ulsan College of Medicine
South Korea



Dr. Clement HO
Clinical Assistant Professor
Department of Surgery
University of British Columbia
Canada



Prof. Curtis LANGLOTZ
Professor of Radiology, Medicine, and Biomedical Data Science
Senior Associate Vice Provost for Research
Director, Center for Artificial Intelligence in Medicine & Imaging
Stanford University
United States



Prof. Sungil HWANG
Secretary General
The Korean Society of Radiology
South Korea



Dr. Jae Hwan LEE
Professor
Department of Radiology
Seoul National University Bundang Hospital
South Korea



INTERNATIONAL FACULTY



Dr. Lester Chee Hao LEONG

Senior Consultant
Department of Diagnostic Radiology
Khoo Teck Puat Hospital
Singapore



Dr. Henry Chun Yip WONG

Proton Therapy Fellow
New York Proton Center
United States



Prof. Dong LIANG

Vice President
Shenzhen Institutes of Advanced Technology
Chinese Academy of Sciences
Research Center for Medical Artificial Intelligence
Institute of Biomedical and Health Engineering
China



Prof. Kei YAMADA

Professor and Chair
Department of Radiology
Kyoto Prefectural University of Medicine
Japan



Prof. Amaka OFFIAH

Vice-President
Clinical Radiology
The Royal College of Radiologists
United Kingdom



Dr. Nicky THORP

Vice-President
Clinical Oncology
The Royal College of Radiologists
United Kingdom



Prof. Yoshito TSUSHIMA

Professor and Chairman
Department of Diagnostic Radiology and Nuclear Medicine
Gunma University Graduate School of Medicine
Japan



Dr. Jyothirmayi VELAGA

Abdominal Radiologist
St Vincent's Health Network Sydney
Australia

LOCAL FACULTY

Prof. Albert Chi Yan CHAN
Clinical Professor
Department of Surgery, School of Clinical Medicine
The University of Hong Kong



Dr. Elki Sze Nga CHEUNG
Associate Consultant
Department of Clinical Oncology
Pamela Youde Nethersole Eastern Hospital



Dr. Gary Ka Wai CHAN
Associate Consultant
Nuclear Medicine Unit
Queen Mary Hospital



Dr. Ka Man CHEUNG
Associate Consultant
Department of Clinical Oncology
Queen Elizabeth Hospital



Dr. Samuel Ka Wai CHAN
Clinical Associate Professor
Centre of Cancer Medicine, School of Clinical Medicine
The University of Hong Kong



Dr. Ka Lun CHIU
Associate Consultant
Nuclear Medicine Unit
Tuen Mun Hospital



Dr. Wendy Wing Lok CHAN
Clinical Associate Professor of Practice
Department of Clinical Oncology
The University of Hong Kong



Dr. Keith Wan Hang CHIU
Consultant
Department of Diagnostic and Interventional Radiology
Queen Elizabeth Hospital



Dr. Amy Tien Yee CHANG
Honorary Consultant
Department of Clinical Oncology
Hong Kong Sanatorium & Hospital



Dr. Kelvin Kin Ho CHOI
Consultant
Department of Radiology
Queen Mary Hospital



Dr. Billy Ho Hung CHEUNG
Specialist in General Surgery
Department of Surgery
The University of Hong Kong



Prof. Aya EL HELALI
Clinical Assistant Professor
Department of Clinical Oncology
The University of Hong Kong



Dr. Claudia CHEUNG
Associate Consultant
Department of Radiology
Hong Kong Children's Hospital



Dr. Eliza Po Yan FUNG
Consultant
Department of Diagnostic and Interventional Radiology
Kwong Wah Hospital



LOCAL FACULTY

Prof. Yike GUO
Provost
Chair Professor, Department of Computer Science and Engineering
The Hong Kong University of Science and Technology



Dr. Elaine Yuen Phin LEE
Clinical Associate Professor
Department of Diagnostic Radiology
School of Clinical Medicine
The University of Hong Kong



Dr. Grace HO
Consultant
Department of Radiology
Queen Mary Hospital



Prof. Victor Ho Fun LEE
Clinical Professor and Department Chairperson
Department of Clinical Oncology
The University of Hong Kong



Prof. Rina Yee Man HUI
Director and Chi-Li Pao Foundation Professor in Cancer Medicine
Centre of Cancer Medicine
School of Clinical Medicine
The University of Hong Kong



Prof. Gilberto Ka Kit LEUNG
Director, School of Clinical Medicine, LKS Faculty of Medicine
Co-Director, Centre for Medical Ethics and Law
Tsang Wing-Hing Professor in Clinical Neuroscience
The University of Hong Kong &
Honorary Consultant Neurosurgeon, Queen Mary Hospital



Dr. Elaine Yee Ling KAN
Consultant
Department of Radiology
Hong Kong Children's Hospital



Dr. Wing Cheong LEUNG
Consultant
Department of Obstetrics & Gynaecology
Kwong Wah Hospital



Dr. Julio Sing Hon KWOK
Consultant In-charge
Nuclear Medicine & PET Centre
Hong Kong Baptist Hospital



Dr. Pan Pan NG
Associate Consultant
Department of Diagnostic and Interventional Radiology
Queen Elizabeth Hospital



Dr. Jacky Chun Yin LAU
Consultant
Department of Radiology
Pamela Youde Nethersole Eastern Hospital



Prof. Roger Kai Cheong NGAN
Honorary Clinical Professor, Department of Clinical Oncology
The University of Hong Kong &
Co-Director, Head and Neck Tumor Centre & Lung Cancer Centre
Honorary Consultant in Clinical Oncology, Gleneagles Hospital &
Honorary Consultant, Department of Clinical Oncology
Queen Elizabeth Hospital



Dr. Jessica Yun Pui LAW
Consultant
Department of Obstetrics and Gynaecology
Pamela Youde Nethersole Eastern Hospital



Dr. Jacqueline Ching Man SITT
Specialist in Radiology
Private Practice



LOCAL FACULTY



Dr. Gordon Cheuk Ho TANG
Specialist in Medical Oncology
Department of Clinical Oncology
Prince of Wales Hospital



Dr. William Ho Lim WONG
Consultant
Department of Diagnostic and Interventional Radiology
Princess Margaret Hospital



Dr. Terry Pak Lai TSOI
Associate Consultant
Department of Nuclear Medicine
Pamela Youde Nethersole Eastern Hospital



Dr. Philip Yuguang WU
Consultant
Department of Clinical Oncology
Pamela Youde Nethersole Eastern Hospital



Dr. Assumpta Sze Man WONG
Consultant
Department of Obstetrics and Gynecology
Queen Elizabeth Hospital



Dr. Winnie Wing Ling YIP
Consultant
Department of Clinical Oncology
Tuen Mun Hospital



Dr. Benny Siu Chun WONG
Specialist in Radiology in Private Practice
Honorary Associate Consultant
Department of Radiology
Princess Margaret Hospital



Dr. Ivan Yiu Chung WONG
President
Hong Kong College of Radiologists



Dr. Ken Ka Shing WONG
Associate Consultant, Department of Clinical Oncology
Pamela Youde Nethersole Eastern Hospital &
Honorary Clinical Assistant Professor, The University of Hong Kong &
Honorary Clinical Associate Professor, The Chinese University of Hong Kong



Dr. Richard Wing Cheuk WONG
Consultant
Department of Pathology
United Christian Hospital

SPECIAL OCCASIONS, 21st NOVEMBER 2026

Run Run Shaw Hall, 1/F, Hong Kong Academy of Medicine Jockey Club Building

Programme:

5:30pm	Reception
6:00pm	Joint Ceremonies for Admission of New Fellows The Royal College of Radiologists and Hong Kong College of Radiologists
7:00pm	The Fifth Lilian Leong Oration
7:30pm	Cocktail Reception
8:00pm	Dinner of the Colleges*

**By invitation and pre-registration is required.*

HIGHLIGHTS OF THE EVENING

The Fifth Lilian Leong Oration

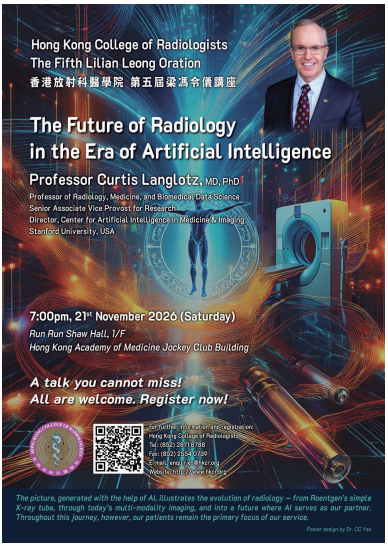

Dinner of the Colleges

Presentation of Distinguished Contribution Award of HKCR

The Distinguished Contribution Award is established to recognise and honour individuals who have rendered distinguished contribution to the College over a long period of time, and demonstrated tremendous influence on development and advancement of Radiology, Clinical Oncology, and Nuclear Medicine specialties.

The Award recipients in 2026 are



Dr. Stephen Chi-wai CHEUNG

MB BS (HK), MRCP (UK), FRCR, FHKCR, FHKAM (Radiology)



Prof. James Francis GRIFFITH

MB BCh BAO, MD (CUHK), MRCP (UK), FRCP (Edin), FRCR, FHKCR, FHKAM (Radiology)

Hong Kong College of Radiologists Distinguished Contribution Award

The Distinguished Contribution Award is established to recognise and honour individuals who have rendered distinguished contribution to the College over a long period of time and demonstrated tremendous influence on development and advancement of Radiology, Clinical Oncology, and Nuclear Medicine specialties.

The two Award recipients in 2026 are Dr. Stephen Chi-wai CHEUNG and Professor James Francis GRIFFITH.



Dr. Stephen Chi-wai CHEUNG had made tremendous and longstanding contributions towards the excellence of radiology development and the betterment of health care delivery in Hong Kong, His work at the Hong Kong College of Radiologists has been outstanding.

Dr. Cheung graduated from University of Hong Kong in 1992 and received his radiology training in Queen Mary Hospital in Hong Kong. He became Fellow of the Royal College of Radiologists in 2000, and Fellow of Hong Kong College of Radiologists in 2003. He is now Service Director of Radiology in the Hong Kong West Cluster of Hospital Authority, and Chief of Service and Head of Cardiovascular Imaging of the Department of Radiology in Queen Mary Hospital.

Dr. Cheung's expertise has led to him being elected to leadership roles of various Radiology societies, including Executive Council Member of Asian Oceanian Society of Radiology (2009-2016). His prime interest is in Cardiac Imaging. He obtained his European Diploma in Cardiac Radiology European Society of Cardiac Radiology (2014) and Cardiac MR Level 3 Certification EACVI from the European Society of Cardiac Radiology in 2015. He is the Immediate Past President of Asian Society of Cardiovascular Imaging (ASCI), having served as President from 2023 to 2025. He is currently a member of CMR Chapter of the Hong Kong College of Cardiology. At the Hospital Authority Head Office, Dr. Cheung is Chairman of Quality Assurance and Safety Subcommittee, COC Radiology and Co-Chairman of Working Group on Collaboration of Cardiac and Radiological Services, COC Radiology and CC Cardiac Service. He had numerous publications and presentations over the past many years.

Dr. Cheung had longstanding contributions to the College. He is dedicated to training, examination and continued professional development in Radiology.

He dedicated nearly two decades to the CME/CPD Subcommittee, having served as Member in 2005-2008, and as the Chairman for 18 years from 2008 to 2026. He served in the College as a Council Member from 2004 to 2008, and had been Honorary Secretary from 2008 to 2017.

He was an Examiner for Joint Final Examination of The Royal College of Radiologists & Hong Kong College of Radiologists (HKCR) in 2014-2017 & 2025 and the Assessor for Exit Assessment of HKCR since 2016. He has served as the Chairman of Examination Board since its establishment in 2017, Chairman of Education & Research Fund Sub-Committee since 2010 (as Member from 2007 to 2010), Member of Education Committee (2007-2021), Scientific Subcommittee (2002-2008), Training Course Subcommittee in Radiology (2003-2009), and Accreditation Subcommittee in Radiology (2011-12, 2015-2017).

He had organised numerous radiological meetings and conferences including AOCR 2006, ASCI 2011 as Congress Honorary Secretary, 9th CT Coronary Angiography Teaching Course 2013, and ASCI 2022 as Congress Vice-President, etc. He also supported the College in various capacities, including Member of the Finance Committee (2005-2008), Constitution Subcommittee as Chairman in 2015-2019 (as Member from 2010 to 2022). He has been the Reviewer of the College Journal since 2003, and as the Associate Editor from 2004 to 2022.

Dr. Cheung's outstanding, longstanding and immense contributions to our College, to Radiology and the medical profession are highly recognised.



Professor James GRIFFITH is an outstanding and enthusiastic radiologist. His longstanding contributions towards the excellence of radiology development as well as for his work in Hong Kong College of Radiologists over the past years are exemplary.

Professor Griffith graduated from University College Cork in 1983, and became a Fellow of the Royal College of Radiologists in 1992. He joined the Chinese University of Hong Kong and worked in Prince of Wales Hospital since 1995. He became Fellow of Hong Kong College of Radiologists in 1997. He is a Professor and former Chairman of the Department of Imaging and Interventional Radiology of The Chinese University of Hong Kong.

Professor Griffith is active academically and his prime interest is in Musculoskeletal Radiology.

Internationally recognised for his expertise as an academic radiologist in the field of Musculoskeletal Radiology, he is active in organisations in the field.

He has close ties with the International Skeletal Society (ISS), having been Chair of the Asian ISS Outreach Programme from 2017 to 2019, and Chair of the Global ISS Outreach Programme from 2019 to 2023. He has been a member of the ISS Annual Scientific Programme Committee for the past six years and is a panel member of the Don Resnick Visiting Professor Programme. He is also the instigator and current Chair of the ISS MSK Workshop Programme.

He was President of the Asian Musculoskeletal Society (AMS) between 2018 and 2022, and is currently the International Liaison Officer for the AMS.

He also instigated and co-coordinated the popular Actionable Reporting Education Programme at the European Congress of Radiology for the past few years. He is on the Editorial Board of Skeletal Radiology, Quantitative Imaging in Medicine and Surgery (QIMS), Ultrasonography, and Seminars in Musculoskeletal Radiology.

He has written 392 peer review scientific papers, delivered over 500 invited lectures, authored or co-authored over 200 book chapters, and has edited 10 textbooks. He is the Editor of the award-winning 994-page educational textbook, Diagnostic Ultrasound: Musculoskeletal, now in its 3rd Edition, and which is recognised as one of the top musculoskeletal ultrasound textbooks.

Professor Griffith contributed to the College tremendously in the past two decades. He is enthusiastic in the training of young radiologists in Hong Kong. Apart from being the General and MSK Subspecialty trainer for radiology trainees since 1995, he has been the lecturer of HKCR Fellowship Training Courses since 2001. He has served as reviewer for Hong Kong Journal of Radiology (HKJR) (formerly titled Journal of the Hong Kong College of Radiologists) since 2001. He has served as Member of the Working Group for Musculoskeletal Radiology Training Guidelines since 2021 and has also organised numerous joint scientific seminars and MSK courses for our College.

Professor Griffith's dedication and efforts have contributed to upholding the highest professional standards of competence and good practice in Radiology and the medical profession. His outstanding, longstanding and immense contributions to Radiology are highly recognised.

Venue

Hong Kong Academy of Medicine Jockey Club Building
99 Wong Chuk Hang Road, Aberdeen, Hong Kong SAR, China

Official Language

English

Registration Entitlement

Entitlement	Full Registration	Day Registration
Scientific Sessions including Lectures, Satellite Symposia and Proffered Paper Sessions on 21st – 22nd November 2026	**2 Days**	**Registered day only**
Technical Exhibitions on 21st – 22nd November 2026	✓	✓
Coffee Breaks and Lunches on 21st – 22nd November 2026	✓	✓
Access to E-Poster Exhibition up to 1 year from 21st November 2026	✓	✓
Electronic Programme Book	✓	✓
Online Film Quiz	✓	✓
Conference Kits (including a conference bag, an umbrella and insertions from industry support partners) which can be collected on-site during the meeting period	✓	
Extended access to all recorded sessions on demand, up to 1 year after the meeting	✓	

On-site registration is available on event dates: https://www.hkcr-asm.org

Cancellation Policy

In the interest of safety and in accordance with the guidelines of the Hong Kong Observatory, the meeting will be cancelled in the event of the following adverse weather conditions and no refund will be made:

- *if the black rainstorm or Typhoon Number 8 or above warning is still hoisted one hour prior to the commencement of the meeting.*

If the meeting is cancelled due to extenuating circumstances (i.e. outbreak of diseases including highly infectious diseases causing health hazard to human lives, or from other causes [apart from adverse weather conditions] which are beyond reasonable control and could not reasonably be expected by the Hong Kong College of Radiologists), **the registration fee, less the 10% bank charge and administration fee, would be reimbursed at the Hong Kong College of Radiologists' discretion**. Hong Kong College of Radiologists will announce if any refund is available in due course after the announcement of the cancellation of the meeting.

Electronic Posters

Electronic Poster (E-Poster) System is an online presentation submission and viewing application. This is freely accessible to all registrants of the 34th Annual Scientific Meeting of HKCR using the designated 55" touch screen TV located at the Foyer, First Floor. E-Poster can also be viewed with personal computers using the wireless network or outside the HKAM Jockey Club Building via internet: https://hkcr-asm.org/index/meeting-information/e-poster

Online Film Quizzes

Registrants could participate in the Online Film Quizzes (One Radiology & Nuclear Medicine Film Quiz and One Clinical Oncology Film Quiz) by logging in to the Event Management system: https://www.hkcr-asm.org and click the "Attend Event" tab. **1 Active (Cat. A) CME/CPD point per quiz** will be awarded to participants who have completed the quiz and answered more than 50% of the questions correctly.

The **first 50 participants** will each receive a souvenir upon completion of the Online Film Quiz **before 8:00am on Sunday, 22 November 2026**. Answers will be posted after answers submission deadline. **Prizes for the best 3 answers** — awarded to the participants with the highest scores in the fastest time — will be announced at the Prizes Presentation Session at 10:15am on Sunday, 22 November 2026 at Pao Yue Kong Auditorium (G/F).

Preview Room

Computers are provided for presentation preview at AV Centre (Fung Ying Seen Koon Meeting Room 1), Second Floor. Audiovisual technicians will be available during the operation hours as follows:

Saturday, 21 November 2026	08:00 – 13:00 13:45 – 17:30
Sunday, 22 November 2026	07:45 – 12:30 13:30 – 16:30

VIP Room

Invited guests and speakers are welcome to visit the VIP Room which is located at James Kung Meeting Room, Second Floor. A quiet lounge is available for preparation of presentations and networking.

Cell Phones / Pagers / Electronic Devices

As a courtesy to fellow attendees, please turn off cell phones / pagers / electronic devices, or set them to vibration mode. Phone conversations should not be conducted in the lecture rooms.

"No Food / Drink" Policy

In consideration of the environmental cleanliness and comfort of all registrants, food or drinks are not permitted inside the lecture rooms.

Green Policy

The following green measures are adopted:

- Electronic means, such as email, website, e-programme book & electronic display, are used, rather than printed materials for communications.
- Reusable dishes, cutlery, glassware and linens are prioritized over the use of disposable items.
- BYOB (Bring Your Own Bottle) – Water stations are available at the venue. The use of single use bottles for water is discouraged.
- Lanyards are collected upon participants' departure for recycling.

Social Event

Dinner of the Colleges

Date : 21st November 2026 (Saturday)

Time : 20:00 – 22:00

Venue : Run Run Shaw Hall, 1/F, Hong Kong Academy of Medicine Jockey Club Building

Fee : HK$600

Pre-registration is required. Please register at the Event Management System: www.hkcr-asm.org

HKCR Secretariat

Hong Kong College of Radiologists
Room 909, 9/F
Hong Kong Academy of Medicine Jockey Club Building
99 Wong Chuk Hang Road, Aberdeen
Hong Kong SAR, China
Tel: (852) 2871 8788 Fax: (852) 2554 0739
Email: asm@hkcr.org
URL: https://www.hkcr.org

Event Secretariat

Bonza Meetings & Events Limited
Unit B, 5/F
Wing Hong Centre, 18 Wing Hong Street
Lai Chi Kok, Kowloon
Hong Kong SAR, China
Tel: (852) 4425 4987
Email: info@hkcr-asm.org

	CME/CPD Points			
Academic Accreditations	21st November 2026	22nd November 2026*		Whole Function
The Royal College of Radiologists	7.5	AM	4.5	15.5
		PM	3.5	
Hong Kong College of Radiologists	7.5 (Cat. A)	AM	4.5 (Cat. A)	15.5 (Cat. A)
		PM	3.5 (Cat. A)	
The Hong Kong College of Anaesthesiologists	7.5 (RC-NA)	AM	4.5 (RC-NA)	15 (RC-NA)
		PM	3.5 (RC-NA)	
Hong Kong College of Community Medicine	6 (PP-PP)	AM	4.5 (PP-PP)	10 (PP-PP)
		PM	3.5 (PP-PP)	
The College of Dental Surgeons of Hong Kong	7.5 (PN-PB)	AM	4 (PN-PB)	15 (PN-PB)
		PM	3.5 (PN-PB)	
Hong Kong College of Emergency Medicine	6 (CME-PP)	AM	4.5 (CME-PP)	12 (CME-PP)
		PM	3.5 (CME-PP)	
The Hong Kong College of Family Physicians	5 (OEA-5.02)	AM	3 (OEA-5.02)	10 (OEA-5.02)
		PM	3 (OEA-5.02)	
The Hong Kong College of Obstetricians and Gynaecologists	2 (PP-PP)	AM	0.5 (PP-PP)	2.5 (PP-PP)
		PM	3.5 (PP-PP)	
The College of Ophthalmologists of Hong Kong	7 (CME-PP)	AM	4 (CME-PP)	14 (CME-PP)
		PM	3 (CME-PP)	
The Hong Kong College of Orthopaedic Surgeons	5 (PP-B)	AM	3 (PP-B)	8 (PP-B)
		PM	2 (PP-B)	
The Hong Kong College of Otorhinolaryngologists	4 (PP-2.2)	AM	2.5 (PP-2.2)	9 (PP-2.2)
		PM	2.5 (PP-2.2)	
Hong Kong College of Paediatricians	6 (A-PP)	AM	3 (A-PP)	12 (A-PP)
		PM	3 (A-PP)	
The Hong Kong College of Pathologists	7.5 (CME-PP)	AM	4.5 (CME-PP)	15.5 (CME-PP)
		PM	3.5 (CME-PP)	
Hong Kong College of Physicians	3 (PP-PP)	AM	1.5 (PP-PP)	6 (PP-PP)
		PM	1.5 (PP-PP)	
The Hong Kong College of Psychiatrists	6 (PP-OP)	AM	4.5 (PP-OP)	14 (PP-OP)
		PM	3.5 (PP-OP)	
The College of Surgeons of Hong Kong	6 (CME-PP)	AM	4.5 (CME-PP)	14 (CME-PP)
		PM	3.5 (CME-PP)	
MCHK CME Programme	5 (Passive)	AM	3 (Passive)	10 (Passive)
		PM	3 (Passive)	
Radiographer Board of Hong Kong	Pending			

CME/CPD accreditation is subject to change without prior notice.

Please remember to register for your CME/CPD points on both days of the meeting.

*** To claim full CME/CPD points on November 22, please register your attendance for both AM and PM sessions.**

GROUND FLOOR

Exhibition Hall

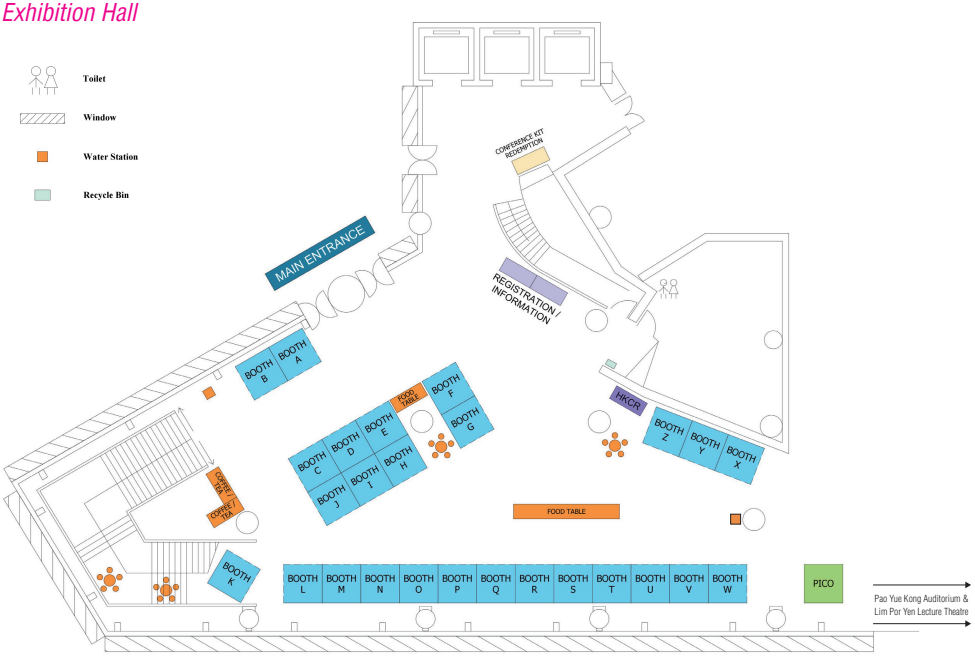

Wong Chuk Hang Road

Pao Yue Kong Auditorium

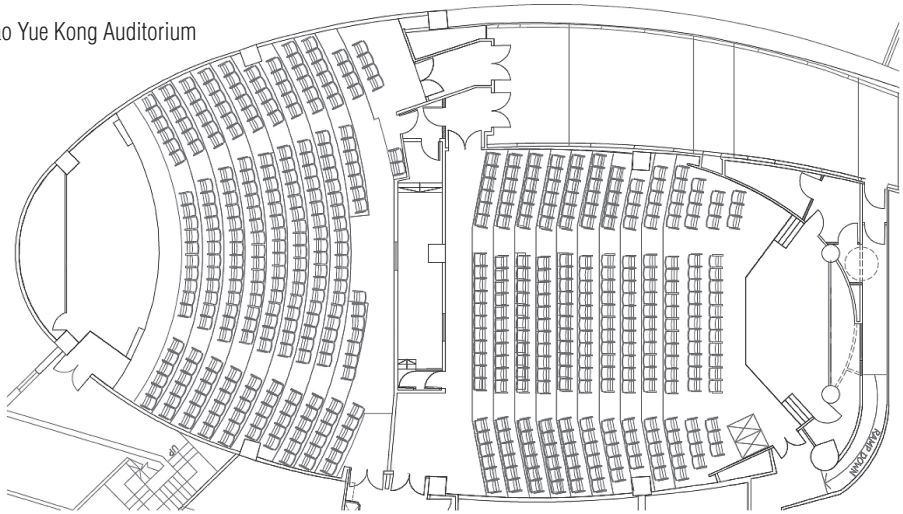

Lim Por Yen Lecture Theatre

FIRST FLOOR

Run Run Shaw Hall & Foyer

Chinese Knotting
21 Nov 19:00-21:00

Toilet

Window

Water Station

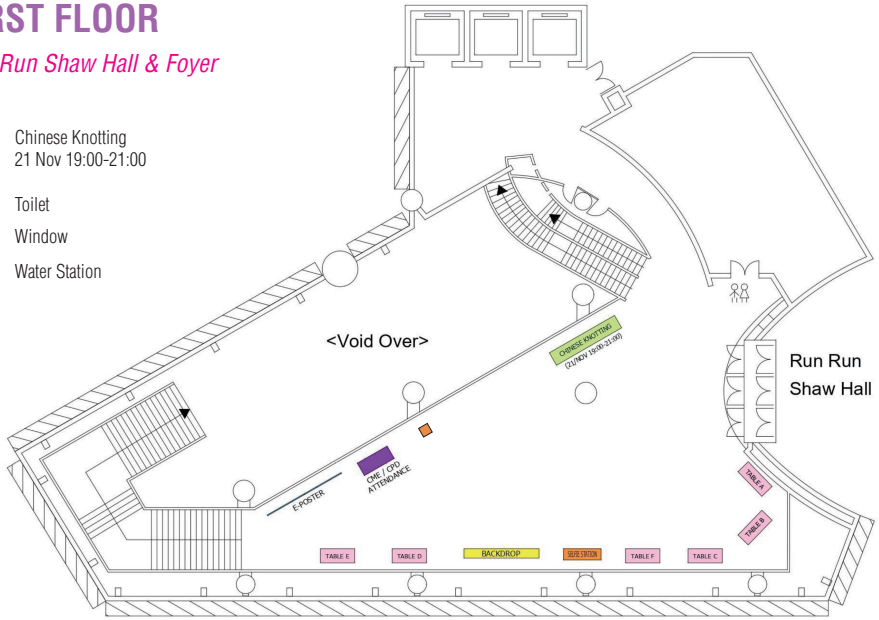

SECOND FLOOR

Fung Ying Seen Koon Meeting Room 1 (AV Centre)

Function Room 1 & 2

James Kung Meeting Room (VIP Room)

Recycle bin

Water Station

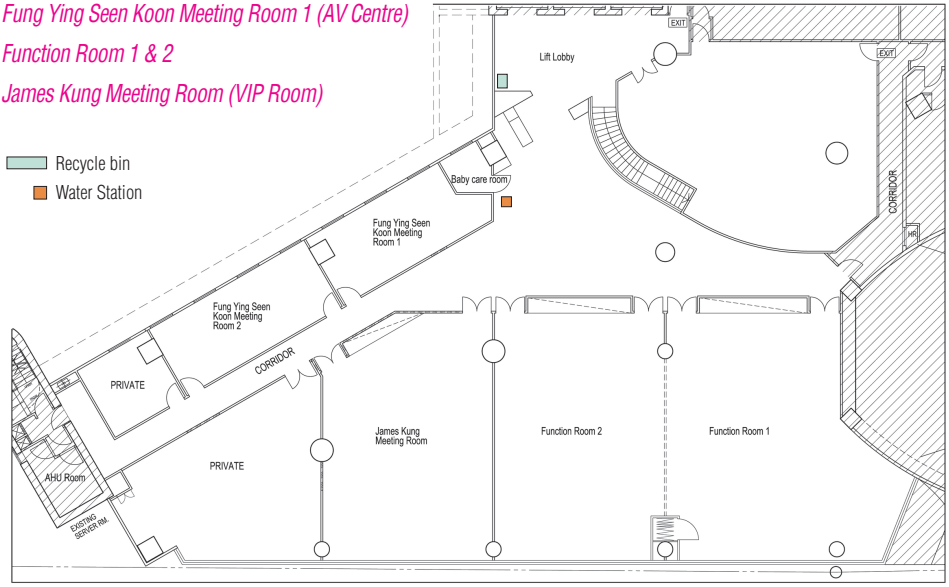

Wong Chuk Hang Road

The Organising Committee would like to thank the following abstract reviewers and judges of various awards:

Dr. Ting Kun AU YONG
Dr. Cherry Cheuk Yan CHAN
Dr. Kuen CHAN
Dr. Tak Kwong CHAN
Dr. Yu Leung CHAN
Dr. Kenneth King CHEUNG
Dr. Stephen Chi Wai CHEUNG
Dr. Leanne Han Qing CHIN
Dr. Keith Wan Hang CHIU
Dr. Carmen Chi Min CHO
Dr. Danny Hing Yan CHO
Dr. Frankie Pak Tat CHOI
Dr. Kelvin Kin Ho CHOI
Dr. Boris Chun Kei CHOW
Dr. Chi Yeung CHU
Dr. Edward Yin Lun CHU
Dr. Shirley Ka Man CHU
Prof. Winnie Chiu Wing CHU
Dr. Elaine Wing Shan FOK
Dr. William FOO
Dr. Eliza Po Yan FUNG
Dr. Kevin Kin Fen FUNG
Dr. King Him FUNG
Dr. Wai Yuk FUNG
Dr. Grace HO
Dr. Yan Ho HUI
Dr. Esther Hiu Yee HUNG
Dr. Kenneth Hoi Ming KWOK
Prof. Dora Lai Wan KWONG
Dr. Billy Ming Hei LAI
Dr. Jessica Wing Yu LAI
Dr. Daisy Chor Man LAM
Dr. Sonia Hiu Yin LAM
Dr. Jacky Chun Yin LAU
Dr. Elaine Yuen Phin LEE
Dr. Jonan Chun-Yin LEE
Dr. Philip Yat Sing LEE
Prof. Victor Ho Fun LEE
Dr. Dennis Kwok Chuen LEUNG
Dr. Hanson Ho Sang LEUNG
Dr. Angela On Chee LI
Dr. Caleb Shing Him LIU
Dr. Bill Archie LO
Dr. Sheung Yan LO
Dr. Shiobhon Yiu LUK
Dr. Vivian Wai Han MA
Dr. Carol Wing Kei NG
Dr. Fung Him NG
Dr. Kwok Sing NG
Dr. Pan Pan NG
Dr. Ting Ying NG
Prof. Roger Kai Cheong NGAN
Dr. Ka Wai SHEK
Dr. Jacqueline Ching Man SITT
Dr. Winnie Man Tak SOO
Dr. Godfrey Kwok Fai TAM
Dr. Christine TANG
Dr. Winnie Wing Yan TIN
Dr. Sunny Kin Sun TSE
Dr. Amy Ho Ching WONG
Dr. Charmaine Hing Ki WONG
Dr. Frank Chi Sing WONG
Dr. Frank Ho Yuen WONG
Dr. Gloria Ting WONG
Dr. Kin Hoi WONG
Dr. Sin Man WONG
Dr. Lena Lu XU
Dr. Tsz Wai YEUNG
Dr. Stefanie Wai Ying YIP
Dr. Peter San Ming YU
Dr. Ming Keung YUEN
Dr. Tsz Yau YUEN

We would also like to thank our trainees for their support and co-ordination of activities of the 34th Annual Scientific Meeting of HKCR, Joint Ceremonies for Admission of New Fellows and the Fifth Lilian Leong Oration and the Dinner of the Colleges:

Dr. Alina Ashok BHARWANI

Dr. Chun Ho CHAN

Dr. Jocelyn Wai-ling CHU

Dr. Natalie Iris Tze Ying HO

Dr. Jennie Ka Ching LAU

Dr. Ka Chun MOK

Dr. Shuk Mei OR

Dr. Amrit PUN

Dr. Ching SO

Dr. Peggy Bik Kei TANG

Dr. Man Lung TSANG

Dr. Timothy Teng Kit TSOI

Dr. Ho Ting Christie WONG

Dr. Yanny Wing Yan WONG

Dr. Ying YU

The programme is at Hong Kong Time (GMT+8).

Date	21 November 2026 (Saturday)				
Specialty	**Radiology**		**Clinical Oncology**		**Clinical Oncology / Nuclear Medicine / Radiology**
Time / Venue	*Pao Yue Kong Auditorium (G/F)*	Time / Venue	*Function Room 1 (2/F)*	Time / Venue	*Function Room 2 (2/F)*
0830 - 1000	**RAD Proffered Papers (Session A)**	0830 - 0930	**ONC Proffered Papers**		
				0850 - 0910	**Navigating First-line mTNBC: Positioning SG in Clinical Practice** (Prof. Sung-Bae KIM, P.105) *supported by* GILEAD
				0910 - 0930	**'LIVE Imaging' MRI: Innovative Applications** (Prof. Dong LIANG, P.106) *supported by* UNITED IMAGING
				0930 - 1000	**The Evolving Landscape of Gadolinium-based Contrast Agents (GBCAs): Clinical Evidence and Future Directions** (Prof. Yoshito TSUSHIMA, P.107)
1000 - 1030	**Coffee Break** *(Exhibition Hall, G/F)*				
	Pao Yue Kong Auditorium (G/F)				
1030 - 1230	***Multidisciplinary Symposium: Breast Cancer***				
1030 - 1045	**Ultrafast MRI in Management of Breast Cancers** (Dr. Eliza Po Yan FUNG, P.53)				
1045 - 1100	**BI-RADS v2025 Updates** (Dr. Jacqueline Ching Man SITT, P.54)				
1100 - 1115	**AI in Breast Cancer Imaging** (Dr. Lester Chee Hao LEONG, P.55)				
1115 - 1130	**Localization of Non-palpable Breast Tumors: A Surgeon's Perspective** (Dr. Billy Ho Hung CHEUNG, P.56)				
1130 - 1200	**Advances in Adjuvant Systemic and Radiotherapy in Early Breast Cancer** (Prof. Roger Kai Cheong NGAN, P.58)				
1200 - 1230	**Discussion**				
1230 - 1400			*Function Room 1 (2/F)*		*Function Room 2 (2/F)*
		1230 - 1300	**Metastatic Melanoma and inNE Management: Clinical Perspective and Updates in Management** (Prof. Aya EL HELALI, P.101) *supported by* Bristol Myers Squibb	1230 - 1300	**Optimizing Management of Endometrial Cancer with ID: When and How?** (Dr. Amy Tien Yee CHANG, P.108) *supported by* MSD
		1300 - 1330	**NEOTORCH: Expanding the Possibilities of Perioperative Immunotherapy in Resectable Stage III NSCLC** (Prof. Victor Ho Fun LEE, P.102) *supported by* TopAlliance	1300 - 1330	**Evolving Treatment Paradigms in First-Line EGFR-Mutated NSCLC: Advancing Outcomes through Combination Strategies, Treatment Innovation and Patient-Centred Care** (Dr. Samuel Ka Wai CHAN, P.109) *supported by* Johnson&Johnson
	Lunch Break *(Run Run Shaw Hall, 1/F)*				
1400 - 1420	**A Multidisciplinary Approach to Prenatal Diagnosis of Complex Fetal Structural Abnormalities - FMPRG** (Dr. Wing Cheong LEUNG, P.59)	1400 - 1420	**Late Effects of Childhood Cancer Treatment** (Dr. Nicky THORP, P.68)	1400 - 1420	**FAPI PET in 2026: Promise, Pitfalls, and a Reality Check** (Dr. Terry Pak Lai TSOI , P.77)
1420 - 1440	**Introduction to Fetal Imaging** (Dr. Claudia CHEUNG, P.60)	1420 - 1440	**Leadership in Oncology** (Dr. Nicky THORP, P.70)	1420 - 1440	**Amino Acid PET and PET RANO 1.0 in Neuro-oncology** (Dr. Gary Ka Wai CHAN , P.78)
1440 - 1500	**Post-mortem Imaging: The Present and Future of the Minimally Invasive Autopsy** (Prof. Amaka OFFIAH, P.61)	1440 - 1600	**The Tumour Board Chronicles: Case-based Dilemmas in Gyn-oncology** (Dr. Assumpta Sze Man WONG, Dr. Benny Siu Chun WONG, Dr. Richard Wing Cheuk WONG, Dr. Philip Yuguang WU, Dr. Winnie Wing Ling YIP, P.72)	1440 - 1500	**Molecular Imaging in Neurodegenerative Diseases: From Diagnosis to Therapeutic Decision-making** (Dr. Ka Lun CHIU, P.79)
1500 - 1520	**Imaging Beyond Life: Post-mortem Imaging in Perinatal Medicine** (Dr. Elaine Yee Ling KAN, P.62)			1500 - 1520	**The Expanding PET Toolkit in the Clinical Management of Breast Cancer: FDG, FES, and More** (Dr. Julio Sing Hon KWOK, P.81)
1520 - 1540	**Acute Female Pelvis on CT: What to Look for and What Not to Miss** (Dr. Jyothirmayi VELAGA, P.63)			1520 - 1600	**NM Proffered Papers**
1540 - 1600	**The Impact of Molecular Classification in Endometrial Cancer on Radiology Practice** (Dr. Elaine Yuen Phin LEE, P.64)				
1600 - 1630	**Coffee Break** *(Exhibition Hall, G/F)*				
1630 - 1650	**Imaging in Cervical Cancer Staging: The New Standard of Care** (Dr. Grace HO, P.65)	1630 - 1650	**Rethinking Immunotherapy Across the HCC Spectrum: A Surgical Perspective** (Prof. Albert Chi Yan CHAN, P.103) *supported by* AstraZeneca	1630 - 1730	**RAD Proffered Papers (Session B)**
1650 - 1710	**2D/4D Hysterosalpingo-Contrast-Sonography (HyCoSy) in Tubal Patency Assessment** (Dr. Jacky Chun Yin LAU and Dr. Jessica Yun Pui LAW, P.66)	1650 - 1710	**Addressing Unmet Needs in HER2m NSCLC: From Evidence to Practice** (Dr. Gordon Cheuk Ho TANG, P.104) *supported by* Boehringer Ingelheim		
1710 - 1730	**Pelvic Floor MRI: Technique and Interpretation** (Dr. Jyothirmayi VELAGA, P.67)				
1800 - 1900	*Run Run Shaw Hall (1/F)*				
	The Royal College of Radiologists & Hong Kong College of Radiologists The Twenty-sixth Joint Ceremonies for Admission of New Fellows ***[for invited guests only]***				
1900 - 1930	**The Fifth Lilian Leong Oration The Future of Radiology in the Era of Artificial Intelligence** Prof. Curtis LANGLOTZ ***[pre-registration is required]***				
1930 - 2000	**Reception** *(Foyer, 1/F)*				
2000 - 2200	**The Royal College of Radiologists & Hong Kong College of Radiologists Dinner of the Colleges** ***[pre-registration is required]***				

PROGRAMME-AT-A-GLANCE

** The programme is subject to change without prior notice.*

The programme is at Hong Kong Time (GMT+8).

Date	22 November 2026 (Sunday)				
Specialty	Radiology / Interventional Radiology		Clinical Oncology / Palliative Medicine		Radiology
Time \ Venue	*Function Room 1 (2/F)*			Time \ Venue	*Function Room 2 (2/F)*
0815 - 1000	***Young Fellows Forum***			0900 - 1000	**Hologic Mammography Reading Workshop** *supported by* HOLOGIC **[Both sessions are identical.]** **Session 1:** **Contrast-enhanced Mammography** Dr. Rameysh DANOVANI **&** **AI-driven Slices Tomosynthesis Viewing** Dr. Hiok Yang CHAN **[Seats are limited. Separate pre-registration is required.]**
0815 - 0920	**Young Fellows Forum**				
0920 - 0935	**Beyond Reporting: What's Next for a Radiologist?** Dr. Jyothirmayi VELAGA				
0935 - 1000	**Discussion**				
1000 - 1030	**Coffee Break *(Exhibition Hall, G/F)***				
	Pao Yue Kong Auditorium (G/F)		*Function Room 1 (2/F)*		*Function Room 2 (2/F)*
1015 - 1030	**Prizes Presentation**	1010 - 1130	***New Advances in Oncology / Dedicated Radiotherapy Session***	1030 - 1130	**Hologic Mammography Reading Workshop** *supported by* HOLOGIC **[Both sessions are identical.]** **Session 2:** **Contrast-enhanced Mammography** Dr. Rameysh DANOVANI **&** **AI-driven Slices Tomosynthesis Viewing** Dr. Hiok Yang CHAN **[Seats are limited. Separate pre-registration is required.]**
		1010 - 1030	**Proton Therapy in Breast Cancer: Where Might It Fit?** (Dr. Henry Chun Yip WONG, P.73)		
1030 - 1230	***KSR-HKCR Conjoint Session: Interventional Radiology***				
1030 - 1050	Catheter-directed Sclerotherapy of Ovarian Endometrioma: Current Evidences (Dr. Jae Hwan LEE, P.82)	1030 - 1050	**Precision Ablation Therapy in Gynecological Malignancies and Beyond** (Dr. Clement HO, P.74)		
1050 - 1110	**Uterine Fibroid Embolization: Evidence, Technique, and Practical Tips** (Dr. William Ho Lim WONG, P.83)	1050 - 1110	**Optimising Adjuvant Radiotherapy in Breast Cancer: Less Treatment, Same Outcomes?** (Dr. Wendy Wing Lok CHAN, P.75)		
1110 - 1130	**Prostatic Artery Embolization for Benign Prostatic Hyperplasia** (Dr. Hye Doo JUNG, P.84)	1110 - 1130	**Advancements in Systemic Therapies for Breast Cancer** (Prof. Rina Yee Man HUI, P.76)		
1130 - 1150	**MRI-guided Intervention: Renal Cell Carcinoma Cryoablation** (Dr. Pan Pan NG, P.85)	1130 - 1230	***Palliative Medicine***		
		1130 - 1150	Stereotactic Radiosurgery for Brain Metastases in Oncogene-addicted Non-small Cell Lung Cancer Patients Treated with Tyrosine Kinase Inhibitor (Dr. Elki Sze Nga CHEUNG, P.88)		
1150 - 1210	**Debulking with Rotarex: A Clinical Perspective** (Dr. Jihoon KIM, P.86)	1150 - 1210	Lutetium-177: An Emerging Palliative Treatment Option in the Chinese Population with Metastatic Castration-resistant Prostate Cancer (mCRPC) – Current Data and a Single Center Experience in Hong Kong (Dr. Ken Ka Shing WONG, P.89)		
1210 - 1230	**TEVAR: A Sunset Industry for Interventional Radiology?** (Dr. Kelvin Kin Ho CHOI, P.87)	1210 - 1230	**Prognostic Modeling - Conventional Statistics, AI and Beyond** (Dr. Ka Man CHEUNG, P.90)		
1230 - 1400			*Function Room 1 (2/F)*		
		1230 - 1300	**Advancing Breast Care with Contrast-enhanced Mammography and CEM-guided Biopsy** (Dr. Rameysh DANOVANI, P.110) *supported by* HOLOGIC		
	Lunch Break *(Banquet Rooms, 3/F)*				
1330 - 1400	**Reception *(Foyer, 1/F)***				
	Run Run Shaw Hall (1/F)				
1400 - 1730	***Global AI Symposium: Artificial Intelligence in the Era of Personalised Medicine***				
1400 - 1410	**Opening Remarks** Prof. Zhengyu JIN and Dr. Ivan Yiu Chung WONG				
1410 - 1430	**Keynote Lecture: The Effect of Artificial Intelligence on the Radiologist Workforce** (Prof. Curtis LANGLOTZ, P.91)				
1430 - 1450	**Keynote Lecture: Governance of Artificial Intelligence in Healthcare: A Glocal Perspective** (Prof. Gilberto Ka Kit LEUNG, P.92)				
1450 - 1510	**Keynote Lecture: The Next Frontier of AI-enabled Healthcare: From Bench to Practice** (Prof. Yike GUO, P.93)				
1510 - 1530	**Discussion**				
	AI Implementation - Challenges and Opportunities around the World				
1530 - 1540	**From Pilot to Practice: AI Deployment in Radiology in Hong Kong** (Dr. Keith Wan Hang CHIU, P.94)				
1540 - 1550	**The AI Application in Healthcare System of China** (Prof. Zhengyu JIN, P.95)				
1550 - 1600	**Scaling AI Safely: Lessons Learned from the NHS Experience** (Dr. Stephen HARDEN, P.96)				
1600 - 1610	**AI in Radiology Across Asia-Oceania: Building Capacity, Equity and Trust** (Dr. Chamaree CHUAPETCHARASOPON, P.97)				
1610 - 1620	**Vibe Coding and Agentic AI as a Radiologist** (Prof. Sungil HWANG, P.98)				
1620 - 1630	**Future of Radiology in Japan with AI** (Prof. Kei YAMADA, P.99)				
1630 - 1730	**Roundtable Panel Discussion and Open Forum**				

21st November 2026 (Saturday)

Pao Yue Kong Auditorium (G/F)

RADIOLOGY PROGRAMME

Chairpersons: *Christine Shing-yen LO, Thomas Ming Ho TONG*

0830-1000	**RAD Proffered Papers - Session A**		
0830-0840	PP-RAD A1	**Pretreatment DCE-MRI Spatial Ecological Signatures for Predicting Pathologic Complete Response in HER2-Positive Breast Cancer**	Tong SU
0840-0850	PP-RAD A2	**Anatomy-Aware Deep Learning with Tumour and Lymph Node Station Maps for CT-Based Nodal Metastasis Prediction in Lung Cancer**	Zhebing LIN
0850-0900	PP-RAD A3	**Anatomy-Informed 3D Deep Learning for Preoperative CT Prediction of Visceral Pleural Invasion**	Pengchong LI
0900-0910	PP-RAD A4	**Interpretable Intrasplenic Attenuation Phenotypes and Spatial Relationship Modelling for Early Identification of High-Grade Splenic Injury on Non-Contrast CT**	Yaning WANG
0910-0920	PP-RAD A5	**Bridging the Implementation Gap: A Cross-Sectional Study of Radiologist and Clinician Perspectives on Artificial Intelligence (AI) in Radiology.**	Alex MOK
0920-0930	PP-RAD A6	**Quantitative Ultrafast DCE-MRI Pharmacokinetic Analysis of Breast Lesions referred for MRI-Guided Biopsy**	Pak Lun LAM
0930-0940	PP-RAD A7	**Winning by Saving: Utility of Contrast-enhanced Mammography as a One-stop Problem-solving Tool**	Stefanie Wai Ying YIP
0940-0950	PP-RAD A8	**Implementation of Ultrasound-Guided Therapeutic Vacuum-Assisted Biopsy for High-Risk (B3) and Discordant Benign Breast Lesions: Effectiveness and Long-Term Outcomes**	Peggy Bik Kei TANG
0950-1000	PP-RAD A9	**Placental Vascularization-Flow Index on 3D Power Doppler Ultrasound as an Early Predictor for Gestational Diabetes Mellitus: A Prospective Cohort Study**	Bhumika DHAMIJA
1000-1030	**COFFEE BREAK *(Exhibition Hall, G/F)***		

Legend: Coffee Break

MULTIDISCIPLINARY SYMPOSIUM

Chairpersons: Kenneth Wing Sum LI, Chun Ying LUI, Gloria Ting WONG

1030-1230	**Multidisciplinary Symposium: Breast Cancer**		
1030-1045	MDS 1	**Ultrafast MRI in Management of Breast Cancers**	Eliza Po Yan FUNG
1045-1100	MDS 2	**BI-RADS v2025 Updates**	Jacqueline Ching Man SITT
1100-1115	MDS 3	**AI in Breast Cancer Imaging**	Lester Chee Hao LEONG
1115-1130	MDS 4	**Localization of Non-palpable Breast Tumors: A Surgeon's Perspective**	Billy Ho Hung CHEUNG
1130-1200	MDS 5	**Advances in Adjuvant Systemic and Radiotherapy in Early Breast Cancer**	Roger Kai Cheong NGAN
1200-1230		**Discussion**	
1230-1400	**LUNCH BREAK** ***(Run Run Shaw Hall, 1/F)***		

RADIOLOGY PROGRAMME

Chairpersons: Winnie Chiu Wing CHU, Grace HO

1400-1600	**Radiology Lectures**		
1400-1420	RAD 1	**A Multidisciplinary Approach to Prenatal Diagnosis of Complex Fetal Structural Abnormalities - FMPRG**	Wing Cheong LEUNG
1420-1440	RAD 2	**Introduction to Fetal Imaging**	Claudia CHEUNG
1440-1500	RAD 3	**Post-mortem Imaging: The Present and Future of the Minimally Invasive Autopsy**	Amaka OFFIAH
1500-1520	RAD 4	**Imaging Beyond Life: Post-mortem Imaging in Perinatal Medicine**	Elaine Yee Ling KAN
1520-1540	RAD 5	**Acute Female Pelvis on CT: What to Look for and What Not to Miss**	Jyothirmayi VELAGA

Legend: Lunch Break

1540-1600	RAD 6	**The Impact of Molecular Classification in Endometrial Cancer on Radiology Practice**	Elaine Yuen Phin LEE
1600-1630	**COFFEE BREAK *(Exhibition Hall, G/F)***		
Chairpersons:	*Elaine Yuen Phin LEE, Benny Siu Chun WONG*		
1630-1730	**Radiology Lectures**		
1630-1650	RAD 7	**Imaging in Cervical Cancer Staging: The New Standard of Care**	Grace HO
1650-1710	RAD 8	**2D/4D Hysterosalpingo-Contrast-Sonography (HyCoSy) in Tubal Patency Assessment**	Jacky Chun Yin LAU Jessica Yun Pui LAW
1710-1730	RAD 9	**Pelvic Floor MRI: Technique and Interpretation**	Jyothirmayi VELAGA

Legend: Coffee Break

Function Room 1 (2/F)

CLINICAL ONCOLOGY PROGRAMME

Chairperson: *Brian CHAN*

0830-0930 ONC Proffered Papers

0830-0840	PP-ONC 1	**Real-World Outcomes of Pre-emptive UGT1A1-Guided Irinotecan Dose Reduction in Asian Intermediate Metabolisers**	Ying CHAN
0840-0850	PP-ONC 2	**BLCA-RAPID: External Validation of Multimodal Recurrence Prediction in Non-Muscle-Invasive Bladder Cancer**	Xing LIU
0850-0900	PP-ONC 3	**Dosimetric Drivers of Cardiopulmonary NTCP and Risk Equalization: Implications for Proton Therapy Patient Selection in Breast Cancer**	Rosalyn TANG
0900-0910	PP-ONC 4	**The Reaudit of Monitoring of QT Interval in Cancer Patients using Methadone in the Department of Clinical Oncology, Tuen Mun Hospital**	Hiu Ching WONG
0910-0920	PP-ONC 5	**Real-World Outcomes of First-Line Taxane-Based Chemotherapy with Trastuzumab and Pertuzumab in Advanced HER2-Positive Breast Cancer: A Single-Centre Retrospective Cohort Study**	Edmond King Nam WONG
0920-0930	PP-ONC 6	**CDK4/6 Inhibitors In HR Positive, HER2 Negative Advanced Breast Cancer In Malaysia: Real World Outcome And Cost Analysis**	Uen Yea YEONG

1000-1030 COFFEE BREAK *(Exhibition Hall, G/F)*

Chairperson: *Timothy Tim Wai CHAN*

1230-1300 Lunch Symposium *supported by* Bristol Myers Squibb

1230-1300	SS 1	**Metastatic Melanoma and irAE Management: Clinical Perspective and Updates in Management**	Aya EL HELALI

Legend: Coffee Break

Chairperson:	*David Ryan JOHNSON*		
1300-1330	**Lunch Symposium** *supported by* TopAlliance Biosciences		
1300-1330	SS 2	**NEOTORCH: Expanding the Possibilities of Perioperative Immunotherapy in Resectable Stage III NSCLC**	Victor Ho Fun LEE
1230-1400	**LUNCH BREAK *(Run Run Shaw Hall, 1/F)***		
Chairpersons:	*Kuen CHAN, Timothy Tim Wai CHAN*		
1400-1440	**Clinical Oncology Lectures**		
1400-1420	ONC 1	**Late Effects of Childhood Cancer Treatment**	Nicky THORP
1420-1440	ONC 2	**Leadership in Oncology**	Nicky THORP
Chairpersons:	*Wesley Yuen Lum CHOI, Wesley Kin Yiu WONG*		
1440-1600	**Clinical Oncology Lecture**		
1440-1600	ONC 3	**The Tumour Board Chronicles: Case-based Dilemmas in Gyn-oncology**	Assumpta Sze Man WONG Benny Siu Chun WONG Richard Wing Cheuk WONG Philip Yuguang WU Winnie Wing Ling YIP
1600-1630	**COFFEE BREAK *(Exhibition Hall, G/F)***		
Chairperson:	*Eric Ka Ming LAM*		
1630-1650	**Satellite Symposium** *supported by* AstraZeneca 阿斯利康		
1630-1650	SS 3	**Rethinking Immunotherapy Across the HCC Spectrum: A Surgical Perspective**	Albert Chi Yan CHAN
Chairperson:	*Rina Yee Man HUI*		
1650-1710	**Satellite Symposium** *supported by* Boehringer Ingelheim		
1650-1710	SS 4	**Addressing Unmet Needs in HER2m NSCLC: From Evidence to Practice**	Gordon Cheuk Ho TANG

Legend: Coffee Break

Function Room 2 (2/F)

CLINICAL ONCOLOGY / NUCLEAR MEDICINE / RADIOLOGY PROGRAMME

Chairperson:	*Iris Ka Ming WONG*		
0850-0910	**Satellite Symposium** *supported by* GILEAD Creating Possible		
0850-0910	SS 7	**Navigating First-line mTNBC: Positioning SG in Clinical Practice**	Sung-Bae KIM
Chairperson:	*Yat Sing LEE*		
0910-0930	**Satellite Symposium** *supported by* UNITED IMAGING		
0910-0930	SS 8	**'LIVE Imaging' MRI: Innovative Applications**	Dong LIANG
0930-1000	**Satellite Symposium**		
0930-1000	SS 9	**The Evolving Landscape of Gadolinium-based Contrast Agents (GBCAs): Clinical Evidence and Future Directions**	Yoshito TSUSHIMA
1000-1030	**COFFEE BREAK** ***(Exhibition Hall, G/F)***		
Chairperson:	*Ka Chun LEUNG*		
1230-1300	**Lunch Symposium** *supported by* MSD		
1230-1300	SS 10	**Optimizing Management of Endometrial Cancer with IO: When and How?**	Amy Tien Yee CHANG
Chairperson:	*Florence Siu Ting MOK*		
1300-1330	**Lunch Symposium** *supported by* Johnson&Johnson		
1300-1330	SS 11	**Evolving Treatment Paradigms in First-line EGFR-Mutated NSCLC: Advancing Outcomes through Combination Strategies, Treatment Innovation and Patient-centred Care**	Samuel Ka Wai CHAN
1230-1400	**LUNCH BREAK** ***(Run Run Shaw Hall, 1/F)***		
Chairperson:	*Kwok Sing NG*		
1400-1520	**Nuclear Medicine Lectures**		
1400-1420	NM 1	**FAPI PET in 2026: Promise, Pitfalls, and a Reality Check**	Terry Pak Lai TSOI
1420-1440	NM 2	**Amino Acid PET and PET RANO 1.0 in Neuro-oncology**	Gary Ka Wai CHAN
1440-1500	NM 3	**Molecular Imaging in Neurodegenerative Diseases: From Diagnosis to Therapeutic Decision-making**	Ka Lun CHIU

Legends: Coffee Break Lunch Break

1500-1520	NM 4	**The Expanding PET Toolkit in the Clinical Management of Breast Cancer: FDG, FES, and More**	Julio Sing Hon KWOK
1520-1600	**NM Proffered Papers**		
1520-1530	PP-NM 1	**StratiFIVE: a pilot PROMISE V2-based score for early response assessment on post-therapy imaging after 177Lu-PSMA-617 radioligand therapy**	Michelle CHEUNG
1530-1540	PP-NM 2	**Impact of Different T-score Reference Databases on Osteoporosis Diagnosis and Treatment Eligibility in Hong Kong Chinese Adults: A Single-Centre Study**	Jocelyn CHU
1540-1550	PP-NM 3	**Efficacy of Personalised Dosimetry in Selective Internal Radiation Therapy for Palliative Treatment of Locally Advanced Hepatocellular Carcinoma**	Ho Ming CHEUNG
1550-1600	PP-NM 4	**From full-time full-dose to half-time half-dose in FDG PET imaging with digital PET scanner: A phantom study with Bayesian penalized likelihood image reconstruction**	Kin Keung KWAN
1600-1630	**COFFEE BREAK *(Exhibition Hall, G/F)***		
Chairpersons:	*Kenneth Hoi Ming KWOK, Zenas San Yu LEUNG*		
1630-1730	**RAD Proffered Papers - Session B**		
1630-1640	PP-RAD B1	**Percutaneous cryoablation of lung tumours – experience at a tertiary centre**	Jonan Chun-yin LEE
1640-1650	PP-RAD B2	**Initial Single-Centre Experience with the CARESTO Heal Carotid Stent in Symptomatic Carotid Stenosis: 30-Day Safety and Short-term CTA Findings**	Cherry CHAN
1650-1700	PP-RAD B3	**Development and Validation of a CT-Based Diagnostic Flowchart for Neuromuscular Diseases**	Takuto OKI
1700-1710	PP-RAD B4	**Toxic but Good: A 10-year Review of the Efficacy and Tolerability of Botox Injection for Muscle Spasticity in a Single Tertiary Centre**	Tsz Him WONG
1710-1720	PP-RAD B5	**Diagnostic performance of 3D T2-weighted sequence for local staging of endometrial carcinoma on magnetic resonance imaging (MRI)**	Oi Ling CHAN
1720-1730	PP-RAD B6	**Diagnostic Performance of Multiparametric MRI in the Characterization of Parotid Masses: A 2-Year Retrospective Local Center Experience**	Ching Tung WONG

Legend: Coffee Break

*Programme is subject to change without prior notice

22nd November 2026 (Sunday)

Function Room 1 (2/F)

YOUNG FELLOWS FORUM

Chairpersons: *Matthew Kin Liang CHIU, Pak Lun LAM*

0815-1000	**Young Fellows Forum** **Sustainability in Healthcare**		
0815-0820	YFF 2	**AI for Sustainable Emergency Care: From Precision Triage to Optimized Imaging and Clinical Decision-making**	Yaning WANG (China)
0820-0825	YFF 3	**From Innovation to Impact: Evidence-based Definitive Radiotherapy Strategies for Stage IV NSCLC**	Yichao GENG (PPRA-RTOG)
0825-0830	YFF 4	**From Healthcare Overuse to Green Practice**	Tzu-Hsiang WANG (Chinese Taipei)
0830-0835	YFF 5	**Smarter Imaging for Sustainable Healthcare: A CT-based Approach to Neuromuscular Diseases**	Takuto OKI (Japan)
0835-0840	YFF 6	**Green Radiology: Small Steps, Practical Sustainability**	Shafora Bibi binti SAMRI (Malaysia)
0840-0845	YFF 7	**Small Steps in the Angio Suite: Practice-based Approach to Sustainable Interventional Radiology**	Junho AN (South Korea)
0845-0850	YFF 8	**Sustainability Without Compromising Diagnostic Quality: A Radiologist's Perspective**	Bhumika DHAMIJA (India)
0850-0855	YFF 9	**Sustainable Radiology in Thailand: Less Waste, Better Access**	Puwitch CHAROENCHUE (Thailand)
0855-0900	YFF 10	**Sustainability in Healthcare: Green Radiology**	Serena Oi Ling CHAN (Hong Kong)
0900-0905	YFF 11	**Green Radiotherapy: Reducing the Carbon Footprint of Cancer Care**	Jenny Ching Hei TO (Hong Kong)
0905-0910	YFF 12	**From Late-stage Burden to Sustainable Care: Reimagining Oncology in Malaysia**	Uen Yea YEONG (Malaysia)
0910-0915	YFF 13	**Occupational Safety**	Chi Kun MOK (Macau)

0915-0920	YFF 14	**Chest CT Features of Pediatric MPP**	Sek Fai UN (Macau)
0920-0935	YFF 1	**Beyond Reporting: What's Next for a Radiologist?**	Jyothirmayi VELAGA (Australia)
0935-1000		**Discussion**	

CLINICAL ONCOLOGY / PALLIATIVE MEDICINE PROGRAMME

Chairpersons: *Adrian Wai CHAN, Winnie Wing Yan TIN*

1010-1130 New Advances in Oncology / Dedicated Radiotherapy Session

1010-1030	ONC 4	**Proton Therapy in Breast Cancer: Where Might It Fit?**	Henry Chun Yip WONG
1030-1050	ONC 5	**Precision Ablation Therapy in Gynecological Malignancies and Beyond**	Clement HO
1050-1110	ONC 6	**Optimising Adjuvant Radiotherapy in Breast Cancer: Less Treatment, Same Outcomes?**	Wendy Wing Lok CHAN
1110-1130	ONC 7	**Advancements in Systemic Therapies for Breast Cancer**	Rina Yee Man HUI

Chairpersons: *Jeannie Yin Kwan CHIK, Eva Wui Ming YEUNG*

1130-1230 Palliative Medicine

1130-1150	PM 1	**Stereotactic Radiosurgery for Brain Metastases in Oncogene-addicted Non-small Cell Lung Cancer Patients Treated with Tyrosine Kinase Inhibitor**	Elki Sze Nga CHEUNG
1150-1210	PM 2	**Lutetium-177: An Emerging Palliative Treatment Option in the Chinese Population with Metastatic Castration-resistant Prostate Cancer (mCRPC) – Current Data and a Single Center Experience in Hong Kong**	Ken Ka Shing WONG
1210-1230	PM 3	**Prognostic Modeling - Conventional Statistics, AI and Beyond**	Ka Man CHEUNG

Chairperson: *Leanne Han Qing CHIN*

1230-1300 Lunch Symposium *supported by* HOLOGIC

1230-1300	SS 12	**Advancing Breast Care with Contrast-enhanced Mammography and CEM-guided Biopsy**	Rameysh DANOVANI

1230-1400 LUNCH BREAK *(Banquet Rooms, 3/F)*

Legend: Lunch Break

Function Room 2 (2/F)

HANDS-ON MAMMOGRAPHY READING WORKSHOP

Chairperson: *Chun Ying LUI*

0900-1130	**Hands-on Mammography Reading Workshop** *supported by* HOLOGIC		
0900-1000	WS 1	**Session 1: Contrast-enhanced Mammography & AI-driven Slices Tomosynthesis Viewing [Seats are limited. Separate pre-registration is required.]**	Rameysh DANOVANI Hiok Yang CHAN
1000-1030	**COFFEE BREAK** ***(Exhibition Hall, G/F)***		
1030-1130	WS 2	**Session 2: Contrast-enhanced Mammography & AI-driven Slices Tomosynthesis Viewing [Seats are limited. Separate pre-registration is required.]**	Rameysh DANOVANI Hiok Yang CHAN

Pao Yue Kong Auditorium (G/F)

RADIOLOGY / INTERVENTIONAL RADIOLOGY PROGRAMME

Chairpersons: *Cherry Cheuk Yan CHAN, Stephen Ka Hon WONG*

1030-1230	**KSR-HKCR Conjoint Session: Interventional Radiology**		
1030-1050	IR 1	**Catheter-directed Sclerotherapy of Ovarian Endometrioma: Current Evidences**	Jae Hwan LEE
1050-1110	IR 2	**Uterine Fibroid Embolization: Evidence, Technique, and Practical Tips**	William Ho Lim WONG
1110-1130	IR 3	**Prostatic Artery Embolization for Benign Prostatic Hyperplasia**	Hye Doo JUNG
1130-1150	IR 4	**MRI-guided Intervention: Renal Cell Carcinoma Cryoablation**	Pan Pan NG
1150-1210	IR 5	**Debulking with Rotarex: A Clinical Perspective**	Jihoon KIM
1210-1230	IR 6	**TEVAR: A Sunset Industry for Interventional Radiology?**	Kelvin Kin Ho CHOI
1230-1400	**LUNCH BREAK** ***(Banquet Rooms, 3/F)***		

Legends: Coffee Break, Lunch Break

Run Run Shaw Hall (1/F)

GLOBAL AI SYMPOSIUM: ARTIFICIAL INTELLIGENCE IN THE ERA OF PERSONALISED MEDICINE

Chairpersons: James Chung Hang CHOW, Wai Lun POON

1400-1530		Keynote Lectures	
1400-1410		**Opening Remarks**	Zhengyu JIN Ivan Yiu Chung WONG
1410-1430	AI 1	**The Effect of Artificial Intelligence on the Radiologist Workforce**	Curtis LANGLOTZ
1430-1450	AI 2	**Governance of Artificial Intelligence in Healthcare: A Glocal Perspective**	Gilberto Ka Kit LEUNG
1450-1510	AI 3	**The Next Frontier of AI-enabled Healthcare: From Bench to Practice**	Yike GUO
1510-1530		**Discussion**	

Chairpersons: Stephen HARDEN, Lilian LEONG

1530-1730		Global Panel: AI Implementation – Challenges and Opportunities around the World	
1530-1540	AI 4	**From Pilot to Practice: AI Deployment in Radiology in Hong Kong**	Keith Wan Hang CHIU
1540-1550	AI 5	**The AI Application in Healthcare System of China**	Zhengyu JIN
1550-1600	AI 6	**Scaling AI Safely: Lessons Learned from the NHS Experience**	Stephen HARDEN
1600-1610	AI 7	**AI in Radiology Across Asia-Oceania: Building Capacity, Equity and Trust**	Chamaree CHUAPETCHARASOPON
1610-1620	AI 8	**Vibe Coding and Agentic AI as a Radiologist**	Sungil HWANG
1620-1630	AI 9	**Future of Radiology in Japan with AI**	Kei YAMADA
1630-1730		**Roundtable Panel Discussion and Open Forum**	

*Programme is subject to change without prior notice

Session Code	Speaker	Lecture Title	Page
Multidisciplinary Symposium: Breast Cancer			
MDS 1	Dr. Eliza Po Yan FUNG	Ultrafast MRI in Management of Breast Cancers	53
MDS 2	Dr. Jacqueline Ching Man SITT	BI-RADS v2025 Updates	54
MDS 3	Dr. Lester Chee Hao LEONG	AI in Breast Cancer Imaging	55
MDS 4	Dr. Billy Ho Hung CHEUNG	Localization of Non-palpable Breast Tumors: A Surgeon's Perspective	56
MDS 5	Prof. Roger Kai Cheong NGAN	Advances in Adjuvant Systemic and Radiotherapy in Early Breast Cancer	58
Radiology			
RAD 1	Dr. Wing Cheong LEUNG	A Multidisciplinary Approach to Prenatal Diagnosis of Complex Fetal Structural Abnormalities - FMPRG	59
RAD 2	Dr. Claudia CHEUNG	Introduction to Fetal Imaging	60
RAD 3	Prof. Amaka OFFIAH	Post-mortem Imaging: The Present and Future of the Minimally Invasive Autopsy	61
RAD 4	Dr. Elaine Yee Ling KAN	Imaging Beyond Life: Post-mortem Imaging in Perinatal Medicine	62
RAD 5	Dr. Jyothirmayi VELAGA	Acute Female Pelvis on CT: What to Look for and What Not to Miss	63
RAD 6	Dr. Elaine Yuen Phin LEE	The Impact of Molecular Classification in Endometrial Cancer on Radiology Practice	64
RAD 7	Dr. Grace HO	Imaging in Cervical Cancer Staging: The New Standard of Care	65
RAD 8	Dr. Jacky Chun Yin LAU Dr. Jessica Yun Pui LAW	2D/4D Hysterosalpingo-Contrast-Sonography (HyCoSy) in Tubal Patency Assessment	66
RAD 9	Dr. Jyothirmayi VELAGA	Pelvic Floor MRI: Technique and Interpretation	67

Session Code	Speaker	Lecture Title	Page
Clinical Oncology			
ONC 1	Dr. Nicky THORP	Late Effects of Childhood Cancer Treatment	68
ONC 2	Dr. Nicky THORP	Leadership in Oncology	70
ONC 3	Dr. Assumpta Sze Man WONG Dr. Benny Siu Chun WONG Dr. Richard Wing Cheuk WONG Dr. Philip Yuguang WU Dr. Winnie Wing Ling YIP	The Tumour Board Chronicles: Case-based Dilemmas in Gyn-oncology	72
New Advances in Oncology / Dedicated Radiotherapy Session			
ONC 4	Dr. Henry Chun Yip WONG	Proton Therapy in Breast Cancer: Where Might It Fit?	73
ONC 5	Dr. Clement HO	Precision Ablation Therapy in Gynecological Malignancies and Beyond	74
ONC 6	Dr. Wendy Wing Lok CHAN	Optimising Adjuvant Radiotherapy in Breast Cancer: Less Treatment, Same Outcomes?	75
ONC 7	Prof. Rina Yee Man HUI	Advancements in Systemic Therapies for Breast Cancer	76
Nuclear Medicine			
NM 1	Dr. Terry Pak Lai TSOI	FAPI PET in 2026: Promise, Pitfalls, and a Reality Check	77
NM 2	Dr. Gary Ka Wai CHAN	Amino Acid PET and PET RANO 1.0 in Neuro-oncology	78
NM 3	Dr. Ka Lun CHIU	Molecular Imaging in Neurodegenerative Diseases: From Diagnosis to Therapeutic Decision-making	79
NM 4	Dr. Julio Sing Hon KWOK	The Expanding PET Toolkit in the Clinical Management of Breast Cancer: FDG, FES, and More	81
KSR-HKCR Conjoint Session: Interventional Radiology			
IR 1	Dr. Jae Hwan LEE	Catheter-directed Sclerotherapy of Ovarian Endometrioma: Current Evidences	82
IR 2	Dr. William Ho Lim WONG	Uterine Fibroid Embolization: Evidence, Technique, and Practical Tips	83
IR 3	Dr. Hye Doo JUNG	Prostatic Artery Embolization for Benign Prostatic Hyperplasia	84

Session Code	Speaker	Lecture Title	Page
KSR-HKCR Conjoint Session: Interventional Radiology			
IR 4	Dr. Pan Pan NG	MRI-guided Intervention: Renal Cell Carcinoma Cryoablation	85
IR 5	Dr. Jihoon KIM	Debulking with Rotarex: A Clinical Perspective	86
IR 6	Dr. Kelvin Kin Ho CHOI	TEVAR: A Sunset Industry for Interventional Radiology?	87
Palliative Medicine			
PM 1	Dr. Elki Sze Nga CHEUNG	Stereotactic Radiosurgery for Brain Metastases in Oncogene-addicted Non-small Cell Lung Cancer Patients Treated with Tyrosine Kinase Inhibitor	88
PM 2	Dr. Ken Ka Shing WONG	Lutetium-177: An Emerging Palliative Treatment Option in the Chinese Population with Metastatic Castration-resistant Prostate Cancer (mCRPC) – Current Data and a Single Center Experience in Hong Kong	89
PM 3	Dr. Ka Man CHEUNG	Prognostic Modeling - Conventional Statistics, AI and Beyond	90
Global AI Symposium: Artificial Intelligence in the Era of Personalised Medicine			
AI 1	Prof. Curtis LANGLOTZ	The Effect of Artificial Intelligence on the Radiologist Workforce	91
AI 2	Prof. Gilberto Ka Kit LEUNG	Governance of Artificial Intelligence in Healthcare: A Glocal Perspective	92
AI 3	Prof. Yike GUO	The Next Frontier of AI-enabled Healthcare: From Bench to Practice	93
AI 4	Dr. Keith Wan Hang CHIU	From Pilot to Practice: AI Deployment in Radiology in Hong Kong	94
AI 5	Prof. Zhengyu JIN	The AI Application in Healthcare System of China	95
AI 6	Dr. Stephen HARDEN	Scaling AI Safely: Lessons Learned from the NHS Experience	96
AI 7	Dr. Chamaree CHUAPETCHARASOPON	AI in Radiology Across Asia-Oceania: Building Capacity, Equity and Trust	97

Session Code	Speaker	Lecture Title	Page
Global AI Symposium: Artificial Intelligence in the Era of Personalised Medicine			
AI 8	Prof. Sungil HWANG	Vibe Coding and Agentic AI as a Radiologist	98
AI 9	Prof. Kei YAMADA	Future of Radiology in Japan with AI	99
Satellite Symposium			
SS 1	Prof. Aya EL HELALI	Metastatic Melanoma and irAE Management: Clinical Perspective and Updates in Management	101
SS 2	Prof. Victor Ho Fun LEE	NEOTORCH: Expanding the Possibilities of Perioperative Immunotherapy in Resectable Stage III NSCLC	102
SS 3	Prof. Albert Chi Yan CHAN	Rethinking Immunotherapy Across the HCC Spectrum: A Surgical Perspective	103
SS 4	Dr. Gordon Cheuk Ho TANG	Addressing Unmet Needs in HER2m NSCLC: From Evidence to Practice	104
SS 7	Prof. Sung-Bae KIM	Navigating First-line mTNBC: Positioning SG in Clinical Practice	105
SS 8	Prof. Dong LIANG	'LIVE Imaging' MRI: Innovative Applications	106
SS 9	Prof. Yoshito TSUSHIMA	The Evolving Landscape of Gadolinium-based Contrast Agents (GBCAs): Clinical Evidence and Future Directions	107
SS 10	Dr. Amy Tien Yee CHANG	Optimizing Management of Endometrial Cancer with IO: When and How?	108
SS 11	Dr. Samuel Ka Wai CHAN	Evolving Treatment Paradigms in First-line EGFR-Mutated NSCLC: Advancing Outcomes through Combination Strategies, Treatment Innovation and Patient-centred Care	109
SS 12	Dr. Rameysh DANOVANI	Advancing Breast Care with Contrast-enhanced Mammography and CEM-guided Biopsy	110

Proffered Papers (RAD Session A)

08:30-10:00 Saturday, 21 November 2026 Pao Yue Kong Auditorium, G/F

		Page
1.	**Pretreatment DCE-MRI Spatial Ecological Signatures for Predicting Pathologic Complete Response in HER2-Positive Breast Cancer** Tong Su, Chengxin Kang, Kaidi Long Tian Xie, Wei Tang, Zhongxin Huang, Fajin Lv, Song Peng *Department of Radiology, Chongqing Health Center for Women and Children, Chongqing, 401147, China*	111
2.	**Anatomy-Aware Deep Learning with Tumour and Lymph Node Station Maps for CT-Based Nodal Metastasis Prediction in Lung Cancer** Zhebing Lin, Hanxiao Zhang, Pengchong Li, Xinghua Cheng *Department of Oncology, Shanghai Chest Hospital, Shanghai Jiao Tong University School of Medicine, Shanghai, China*	112
3.	**Anatomy-Informed 3D Deep Learning for Preoperative CT Prediction of Visceral Pleural Invasion** Pengchong Li, Zhonghe Liu, Fang Zhu, Zhebing Lin, Xinghua Cheng *Department of Oncology, Shanghai Chest Hospital, Shanghai Jiao Tong University School of Medicine, Shanghai, China*	113
4.	**Interpretable Intrasplenic Attenuation Phenotypes and Spatial Relationship Modelling for Early Identification of High-Grade Splenic Injury on Non-Contrast CT** Yaning Wang, Mingyang Li, Zheng Miao, Simin Yang, Han Xue, Huimao Zhang *Department of Radiology, the First Hospital of Jilin University*	114
5.	**Bridging the Implementation Gap: A Cross-Sectional Study of Radiologist and Clinician Perspectives on Artificial Intelligence (AI) in Radiology.** Mok Alex, Kwok Hoi Ming, Li Kwok Yan, Lee Bo Yee, Lo Phoebe Hiu Wai, Mahboobani Neeraj, Cheng Lik Fai *Department of Diagnostic and Interventional Radiology, Princess Margaret Hospital, Hong Kong*	115
6.	**Quantitative Ultrafast DCE-MRI Pharmacokinetic Analysis of Breast Lesions referred for MRI-Guided Biopsy** PL Lam, WP Cheung, LW Lo, WS Mak, KML Wong, PYE Fung *Department of Diagnostic and Interventional Radiology, Kwong Wah Hospital, Hong Kong SAR*	116
7.	**Winning by Saving: Utility of Contrast-enhanced Mammography as a One-stop Problem-solving Tool** Stefanie W.Y. Yip, H. L. Chau, Winnie C.W. Chu, Esther H.Y. Hung *Department of Imaging and Interventional Radiology, The Chinese University of Hong Kong, Prince of Wales Hospital, 30-32 Ngan Shing Street, Shatin, Hong Kong*	117

		Page
8.	**Implementation of Ultrasound-Guided Therapeutic Vacuum-Assisted Biopsy for High-Risk (B3) and Discordant Benign Breast Lesions: Effectiveness and Long-Term Outcomes** PBK Tang, EPY Fung, WP Cheung, LW Lo, LKM Wong, WS Mak, DHY Cho *Department of Diagnostic and Interventional Radiology, Queen Elizabeth Hospital, Hong Kong*	118
9.	**Placental Vascularization-Flow Index on 3D Power Doppler Ultrasound as an Early Predictor for Gestational Diabetes Mellitus: A Prospective Cohort Study** Dr Bhumika Dhamija, Dr Upasana Sinha, Dr Mukta Agarwal, Dr Sangam Kumari *Department of Diagnostic and Interventional Radiology, All India Institute of Medical Sciences, Rishikesh, India, and Department of Radiodiagnosis, All India Institute of Medical Sciences, Patna, India*	119

Proffered Papers (RAD Session B)

16:30-17:30 Saturday, 21 November 2026 Function Room 2, 2/F

1.	**Percutaneous cryoablation of lung tumours – experience at a tertiary centre** RK Mak, JCY Lee, BCK Chow, KWH Chiu, KK Li, HW Mok, J Chik, J Chow, WL Poon *Department of Diagnostic and Interventional Radiology, Queen Elizabeth Hospital*	120
2.	**Initial Single-Centre Experience with the CARESTO Heal Carotid Stent in Symptomatic Carotid Stenosis: 30-Day Safety and Short-term CTA Findings** Cherry Cheuk Yan Chan, Chun Kit Richard Chan, Danny Hing Yan Cho *Department of Diagnostic & Interventional Radiology, Kwong Wah Hospital*	121
3.	**Development and Validation of a CT-Based Diagnostic Flowchart for Neuromuscular Diseases** Takuto Oki, Hajime Yokota, Hiroki Miyazaki, Hiroki Mukai, Takashi Uno, Kei Yamada *Department of Radiology, Kyoto Prefectural University of Medicine*	122
4.	**Toxic but Good: A 10-year Review of the Efficacy and Tolerability of Botox Injection for Muscle Spasticity in a Single Tertiary Centre** T.H. Wong, Stefanie W.Y. Yip, Cina S.L. Tong, Esther H.Y. Hung, Griffith James Francis *Department of Imaging and Interventional Radiology, The Chinese University of Hong Kong, Prince of Wales Hospital, 30-32 Ngan Shing Street, Shatin, Hong Kong*	123
5.	**Diagnostic performance of 3D T2-weighted sequence for local staging of endometrial carcinoma on magnetic resonance imaging (MRI)** OL Chan, SCT Ling, WLW Yip, KW Lee, L Xiao, DLY Chow, WH Chong, KY Kwok *Department of Radiology and Nuclear Medicine, Tuen Mun Hospital, Hong Kong*	124

		Page
6.	**Diagnostic Performance of Multiparametric MRI in the Characterization of Parotid Masses: A 2-Year Retrospective Local Center Experience** Dr. WONG Ching Tung, Dr. CHU Ka Man, Dr. KO Wei Sum Koel, Dr. FUNG King Him *Department of Diagnostic & Interventional Radiology, Kwong Wah Hospital*	125

Proffered Papers (ONC)

08:30-09:30 Saturday, 21 November 2026 Function Room 1, 2/F

1.	**Real-World Outcomes of Pre-emptive UGT1A1-Guided Irinotecan Dose Reduction in Asian Intermediate Metabolisers** Ying Chan, Brian Chan, Natalie Sean Man Wong, Ka Chun Leung, Barry Bar Wai Wo, Chin Hong Yick, Ann Shing Lee *Department of Clinical Oncology, Tuen Mun Hospital, Hong Kong SAR, China*	126
2.	**BLCA-RAPID: External Validation of Multimodal Recurrence Prediction in Non-Muscle-Invasive Bladder Cancer** Xing Liu *Department of Urology, Xuzhou Central Hospital, School of Medicine, Southeast University, Xuzhou, Jiangsu, China*	127
3.	**Dosimetric Drivers of Cardiopulmonary NTCP and Risk Equalization: Implications for Proton Therapy Patient Selection in Breast Cancer** CHANG Tien Yee, Amy, TANG, Rosalyn Yuen Yim, YANG, Bin, WONG, Hiu Yi *LKS Faculty of Medicine, The University of Hong Kong, Hong Kong SAR*	128
4.	**The Reaudit of Monitoring of QT Interval in Cancer Patients using Methadone in the Department of Clinical Oncology, Tuen Mun Hospital** HC Wong, WY Tin *Department of Clinical Oncology, Tuen Mun Hospital*	129
5.	**Real-World Outcomes of First-Line Taxane-Based Chemotherapy with Trastuzumab and Pertuzumab in Advanced HER2-Positive Breast Cancer: A Single-Centre Retrospective Cohort Study** King Nam Edmond Wong, Sheona Sze Nga Leung, Kwan Ho Leung, Jessica Wing Yu Lai *Department of Oncology, Princess Margaret Hospital, Hong Kong SAR*	130
6.	**CDK4/6 Inhibitors In HR Positive, HER2 Negative Advanced Breast Cancer In Malaysia: Real World Outcome And Cost Analysis** Yeong Uen Yea, Adlinda Alip *Department of Clinical Oncology, Faculty of Medicine, Universiti Malaya, Kuala Lumpur, Malaysia*	131

Proffered Papers (NM)

15:20-16:00 Saturday, 21 November 2026 Function Room 2, 2/F

		Page
1.	**StratiFIVE: a pilot PROMISE V2-based score for early response assessment on post-therapy imaging after 177Lu-PSMA-617 radioligand therapy** MHY Cheung, PL Tsoi, WT Ngai *Department of Nuclear Medicine, Pamela Youde Nethersole Eastern Hospital, Hong Kong SAR*	132
2.	**Impact of Different T-score Reference Databases on Osteoporosis Diagnosis and Treatment Eligibility in Hong Kong Chinese Adults: A Single-Centre Study** J Chu, TK Chow *Department of Radiology & Nuclear Medicine, Tuen Mun Hospital, Hong Kong*	133
3.	**Efficacy of Personalised Dosimetry in Selective Internal Radiation Therapy for Palliative Treatment of Locally Advanced Hepatocellular Carcinoma** HM Cheung, WI Li, JHY Lau, WC Wong, KS Ng, KK Ng, BT Kung *Nuclear Medicine Unit, Queen Elizabeth Hospital, Hong Kong SAR*	134
4.	**From full-time full-dose to half-time half-dose in FDG PET imaging with digital PET scanner: A phantom study with Bayesian penalized likelihood image reconstruction** Martin Law, Keith Kwan, Judy Yu, Vivian Ma *Department of Clinical Oncology, Tuen Mun Hospital, HKSAR, China.*	135

ELECTRONIC POSTERS (E-POSTER)

All registrants of the 34th Annual Scientific Meeting of HKCR can view all Electronic Posters via internet: https://hkcr-asm.org/index/meeting-information/e-poster

E-Poster can be searched according to categories of papers, which are listed as follows:

- **Abdominal Radiology (GI, HBP and GU)** (Poster No. 01 – 04)
- **Artificial Intelligence** (Poster No. 06 – 10)
- **Breast Radiology** (Poster No. 11 – 13, 15 – 23)
- **Cardiovascular Imaging** (Poster No. 24, 26)
- **Clinical Oncology** (Poster No. 27 – 33)
- **Head & Neck Radiology** (Poster No. 34 – 36)
- **Musculoskeletal Radiology** (Poster No. 38 – 46)
- **Neuro-radiology** (Poster No. 47)
- **Nuclear Medicine** (Poster No. 48 – 49)
- **Obstetrics & Gynaecology Radiology** (Poster No. 50 – 52)
- **Oncologic Radiology** (Poster No. 53 – 54)
- **Physics** (Poster No. 55)
- **Thoracic Radiology** (Poster No. 56 – 57)
- **Vascular & Interventional Radiology** (Poster No. 58 – 60, 62 – 72)

		Page
01	**Introduction of Dual-Energy CT in the Characterisation of Abdominal Mass: Enhancing Lesion Conspicuity in Liver and Kidney with Dual-Energy CT** Maggie HY Leung, Amy HC Wong, Matthew KK Law, Shiobhon Y Luk *Department of Radiology, Pamela Youde Nethersole Eastern Hospital*	136
02	**When Inflammation Masks Infiltration: A Pictorial Review of Pancreatic Cancer Presenting as Acute Pancreatitis** KW Chan, KS Tam, KH Wong *Department of Radiology, North District Hospital, Hong Kong SAR*	137
03	**Tackle the Meckel's: Rare complications of Meckel's diverticulum** KS Tam, KW Chan, TY Yuen, KH Wong *Department of Radiology, North District Hospital, Hong Kong SAR*	138

		Page
04	**Hit and run by hidden culprits: Foreign bodies in gastrointestinal tract** KS Tam, CSJ Wong, TY Yuen, KH Wong *Department of Radiology, North District Hospital, Hong Kong SAR*	139
06	**Virtual Large Language Model Clinical Decision Support Improves Imaging Appropriateness and Guideline-Concordant Management of Incidental Pulmonary Nodules: A Proof-of-Concept Study** HM Kwok, Lewey CH Cheung, MC Chan, WT Kong, John TK Wong, Amy PM Chung, LF Cheng *Department of Diagnostic and Interventional Radiology, Princess Margaret Hospital*	140
07	**From Chatbot to Clinical Workflow: A Framework for AI in Radiology Practice** Kui Chiu YIP, Chung Wai WONG, Elaine Wing Shan FOK *Department of Radiology and Organ Imaging, United Christian Hospital*	141
08	**Fully Automated Pretreatment DCE-MRI Deep Learning for Three-Year Recurrence Risk Stratification in Breast Cancer** Tong Su, Kaidi Long, Rui Wang, Wei Tang, Zhongxin Huang, Fajin Lv, Song Peng *Department of Radiology, Chongqing Health Center for Women and Children, Chongqing, 401147, China*	142
09	**Artificial Intelligence Computer-Aided Diagnosis (AI-CAD) Performance in Mammographic Calcification-Only Lesions: Alignment with BI-RADS Risk Stratification, Histology, and Diagnostic Pitfalls** Wu Lap Yin, Ellen Lok-man YU, Chau Chi Man, Fung Wai Yuk, Leng Yong Mei, Stephanie Cheri Woo, Christine Tang, Chan En Hao, Wong Ka Wai, Wong Ting *Department of Radiology, Princess Margaret Hospital, Hong Kong SAR*	143
10	**Mind the AI Gap: Evaluation of Discrepancies Between Greulich-Pyle and Tanner-Whitehouse 3 Standards in Automated Bone Age Artificial Intelligence Reporting in a Local Hospital in Hong Kong** CW Choi, LH Li, HM Mok, WS Fok *Department of Radiology and Oran Imaging, United Christian Hospital, Hong Kong SAR*	144
11	**Thinking Beyond the Breast: Extra-Mammary Findings, Clinical Relevance, and Interpretation Pitfalls on Breast MRI** WH Jim, SH Lee, L Xu, C Yang, OC Li *Department of Radiology and Nuclear Medicine, Tuen Mun Hospital*	145

		Page
12	**Benign Mimickers of Male Breast Malignancy** Katherine Wong, Stefanie W.Y. Yip, H. L. Chau, Winnie C.W. Chu, Esther H.Y. Hung *Department of Radiology, North District Hospital, 9 Po Kin Road, Sheung Shui, Hong Kong*	146
13	**"404 Mass Not Found" - Unravelling the Diagnostic Spectrum of Non-mass Lesions in Breast Ultrasound** Pik Hey Lee, Yu Ting Wong, Cherry Cheuk Yan Chan, Wai Pan Cheung, Lai Wan Lo, Wing Sze Mak, Lily Ka Man Wong, Eliza Po Yan Eliza Fung *Department of Diagnostic and Interventional Radiology, Kwong Wah Hospital, Hong Kong SAR*	147
15	**Application of Echogenic Rind from BI-RADS 2025: Pearls and Pitfalls** FCT Yip, HF Wong, HC Wong, YK Wong, SH Lee *Department of Radiology, Pok Oi Hospital, Hong Kong SAR*	148
16	**FDG Uptake in Breast Nodules: A Spectrum from Benign to Malignant** MY Wong, SH Lee, KL Chiu, L Xu, C Yang, OC Li *Department of Radiology, Tuen Mun Hospital, Hong Kong SAR*	149
17	**Non-mass breast lesions: Unmasking the wide diagnostic spectrum** HF Wong, FCT Yip, SH Lee *Department of Radiology, Tuen Mun Hospital, Hong Kong SAR*	150
18	**Spectrum of "Non-Mass Lesions" in Breast Ultrasound: A Single-Center Retrospective Review and Pictorial Essay** JKC Lau, NITY Ho, YH Chan, CYM Young, HL Chau, HY Hung, WCW Chu *Department of Imaging and Interventional Radiology, Prince of Wales Hospital, Hong Kong SAR*	151
19	**Contrast-Enhanced Mammography–Guided Biopsy versus MRI-Guided Biopsy for MRI-Only Detected Breast Lesions: Initial Experience from a Hong Kong Centre** Dr. Janet Wong Hin Man, Dr. Leanne HQ Chin, Dr. Tina PW Lam, Dr. Grace Ho *Department of Radiology, Queen Mary Hospital, Hong Kong SAR*	152
20	**"Non-Mass Lesions" in Breast Ultrasound Scan - What are they and what's the implication on BI-RADS v2025?** Jacqueline Ching Man Sitt, Samantha Sum Yue Law, Julian Chun Yan Fong, Chun Ying Lui *Hong Kong Women's Imaging, Hong Kong SAR*	153
21	**USG-guided Non-wire localization technique: various options and how we do them.** Jacqueline Ching Man Sitt, Anna Yuen Ying Lam, Julian Chun Yan Fong, Chun Ying Lui *Hong Kong Women's Imaging, Hong Kong SAR*	153

		Page
22	**MRI Guided - SCOUT BX Localization of Breast Lesion (First Asian Experience)** CSY Lo, VHG Ai, KK Wong, WSY Yu, YS Lee, R Lee, BWH Ho, PSY Cheung, PPK Tsui, KKM Lai, JCH Wong and GG Lo *Department of Diagnostic and Interventional Radiology, Hong Kong Sanatorium & Hospital, Hong Kong SAR*	154
23	**Developing asymmetry - why is it still important in BI-RADS v2025?** Jacqueline Ching Man Sitt, Sherman Yin Man Chan, Julian Chun Yan Fong, Chun Ying Lui *Hong Kong Women's Imaging, Hong Kong SAR*	155
24	**From Promise to Practice: Real-World Data shows ~18% intraindividual Radiation Dose Reduction using PCD-CT in Aortoiliac CT Angiography** Tim Oechsner, Christopher Schuppert, Christopher L. Schlett *Department of Diagnostic and Interventional Radiology, Medical Center–University of Freiburg, Faculty of Medicine, University of Freiburg, Freiburg, Germany*	156
26	**Ultrasonographic Analysis of Effects of Seated Stretching on Popliteal Venous Haemodynamics after Prolonged Sitting** SYS Tin, HH Chan, YT Cheung, MY Chung, KCN Ho, KW Lai, WCW Chu and C Chiyanika *Department of Health Technology and Informatics, The Hong Kong Polytechnic University, Hong Kong SAR*	157
27	**Audit of Entecavir Discontinuation and Post-Treatment Monitoring in Oncology Patients** Ying Chan, Natalie Sean Man Wong, Winnie Wing Yan Tin, Ann Shing Lee *Department of Clinical Oncology, Tuen Mun Hospital, Hong Kong SAR*	158
28	**Salvage Image-Guided Interstitial Brachytherapy Using 3D-Printed Multichannel Applicator and Customized Perineal Template for Isolated Suburethral Vaginal Recurrence of High-Grade Endometrial Adenocarcinoma** Cheng Ngan Sum Jean, Wu Wing Shan, Leung Ka Chun, Chan Suet Nga, Wong Hiu Ching Ada, Chan Ngai Yui, Lee Wan Yan Venus, Yip Wing Ling Winnnie, Wong Chi Sing Frank, Tung Yuk *Department of Clinical Oncology, Tuen Mun Hospital, Hong Kong*	159
29	**Intervendor performance comparison of two commercial deformable image registration software systems in the head and neck region** Celina K W Li *Department of Clinical Oncology, Tuen Mun Hospital, Hong Kong*	160

		Page
30	**CT Radiomics Combined With Clinical and Imaging Features for Identifying High-Grade Serous Ovarian Carcinoma** Yoo Kyung Choi, MD, PhD; Sunmin Park, MD, PhD *Department of Radiation Oncology, Korea University Ansan Hospital, Ansan, Republic of Korea*	161
31	**Baseline Cardiac Assessment before Anthracycline-Based Chemotherapy for Early Breast Cancer** Vivian HM Tsang, Joyce JS Suen *Department of Clinical Oncology, Prince of Wales Hospital, Hong Kong SAR*	162
32	**Fractionated Stereotactic Radiotherapy for Vestibular Schwannoma: Five-Year Outcomes from a single institution** P Wong, WH Mui, NYV Chan, FCS Wong *Department of Clinical Oncology, Tuen Mun Hospital, Hong Kong SAR*	162
33	**Efficacy and Safety of Stereotactic Body Radiotherapy for Unresectable Liver Metastases** KY Lui, WL Chan *Department of Clinical Oncology, Prince of Wales Hospital, Hong Kong SAR*	163
34	**MRI Screening for Pulsatile Tinnitus: Initial Local Experience From Kowloon West Cluster** BY Lee, HM Kwok, LF Cheng *Department of Diagnostic and Interventional Radiology, Princess Margaret Hospital, Kowloon West Cluster, Hong Kong SAR, China*	164
35	**Medication-related osteonecrosis of the jaw: role of multimodality imaging assessment** ML Tsang, KY Li, SH Lee, Y Leng, WY Fung, HM Kwok *Department of Radiology, Tuen Mun Hospital, Hong Kong SAR*	165
36	**CT Assessment of Necrotizing Otitis Externa: From Early Canal Narrowing to Skull Base Destruction** CSJ Wong, KO Cheung, KH Wong *Department of Radiology, North District Hospital, Hong Kong SAR*	166
38	**Updating the Lexicon: A Pictorial Review of the 2026 SSR Standardized MRI Nomenclature for Knee Menisci** Jim WH, Wong YK, L Xu, A Pun, P Cheung, Chong WH *Department of Radiology & Nuclear Medicine, Tuen Mun Hospital, HKSAR*	167

		Page
39	**Role of MRI in Characterising Bicipitoradial Bursitis: A Pictorial Essay** Andrew Man Kwun Li, Yongmei Leng, Hing Ki Charmaine Wong, Nin-Yuan Pan *Department of Radiology, Queen Mary Hospital, Hong Kong*	168
40	**'Diagnosis by sight and sound': Utility of ultrasound at diagnosing the tumour type and malignant potential of soft tissue masses** Yee Ling Or, Cina Shin Loong Tong, Stefanie Wai Ying Yip, Esther Hiu Yee Hung, King Kenneth Cheung, Mohammadreza Kosari, James Griffith *Department of Imaging and Interventional Radiology, Prince of Wales Hospital*	169
41	**MR Neurography: Enhancing diagnostic precision through advanced imaging** Dr PM Chung, Dr ST Wong, Dr HM Kwok, Dr NY Pan *Department of Radiology, Princess Margaret Hospital, HKSAR*	170
42	**Ultrasound of median nerve swelling in carpal tunnel syndrome: proximal-only measurements may lead to underdiagnosis** Fran S.F Kwok, MBChB, FRCR, James F. Griffith, MD, FRCR *Department of Imaging and Interventional Radiology, Pamela Youde Nethersole Eastern Hospital, Hong Kong*	171
43	**Pictorial Essay of SAPHO Syndrome and Mimickers** FCT Yip, Y Leng, HK Wong, NY Pan *Department of Radiology & Nuclear Medicine, Tuen Mun Hospital, Hong Kong SAR*	172
44	**The Great Masquerader: Multifocal Pediatric Skeletal Tuberculosis Simulating Bone Malignancy** Shafora Bibi Samri *Department of Radiology, School of Medical Sciences, Universiti Sains Malaysia, 16150 Kubang Kerian, Kelantan, Malaysia*	173
45	**Pictorial Essay of Supraspinatus Tendon Tears and Associated Pathologies - Areas to Review** FCT Yip, HC Wong, SH Lee, YK Wong *Department of Radiology & Nuclear Medicine, Tuen Mun Hospital, Hong Kong SAR*	174
46	**Differentiating Insufficiency Fractures from Bony Metastases in Gynecologic Malignancies: An MRI Pitfall in Patients Undergoing Chemoradiation** YM Chong, G Ho *Department of Radiology, Queen Mary Hospital, Hong Kong SAR*	175

		Page
47	**MRI and Clinical Characteristics Associated with Growth or Complication of Cavernoma** SY Sze, HS Leung, WH Hui, WC Law, TY So, NR Mahboobani, MH Lai, JM Abrigo *Department of Imaging and Interventional Radiology, Prince of Wales Hospital, Hong Kong SAR*	176
48	**Quantitative 99mTc-PYP SPECT/CT at 180 Minutes: An Alternative Approach for Diagnostic Stratification in Transthyretin Cardiac Amyloidosis** Tong THC, Chan KWG, Hui YH *Nuclear Medicine Unit, Department of Radiology, Queen Mary Hospital, Hong Kong SAR*	177
49	**Comparison of radiation-induced cancer risks for Japan and Hong Kong adult patients from common whole-body PET/CT examinations in oncology** Celina K W Li, Martin Law *Department of Clinical Oncology, Tuen Mun Hospital, Hong Kong*	178
50	**IMAGING CLUES TO DETECTING GYNAECOLOGICAL LYMPHOMA** Christina C.T. Ng, Elaine Y.P. Lee *Department of Radiology, Queen Mary Hospital*	179
51	**Ovarian teratoma: a pictorial review on imaging findings and complications** CK Chan, OL Chan, WH Chong, KY Kwok *Department of Radiology & Nuclear Medicine, Tuen Mun Hospital, Hong Kong SAR*	180
52	**Hidden in Plain Sight: Vaginal Metastasis as the Initial Manifestation of Renal Cell Carcinoma** CHEUNG Ka Yuet, HO Grace, LEE Elaine Yuen Phin *Department of Radiology, Queen Mary Hospital*	181
53	**The Role of Whole-Body MRI in Multiple Myeloma – A Single-institution Experience** Muhammad Izzat Bin Mohd Hayazi, Chern Yue Glen Ong *Department of Radiology, Tan Tock Seng Hospital, Singapore*	182
54	**Sonographic Evaluation of Testicular Masses: Pictorial Review of Primary Testicular Tumour and Benign Mimics** Pui Man Yeung, Oi Ling Chan, Wing Ho Chong, Kai Yan Kwok *Department of Radiology and Nuclear Medicine, Tuen Mun Hospital, Hong Kong SAR*	183

		Page
55	**Multivendor comparison of quantification accuracy of effective atomic number between fast kVp-switching and twin-beam dual-energy computed tomography scanners: A phantom study** KW Li, OL Chan, MC Mau, CY Yeung, WH Chong *Department of Clinical Oncology, Tuen Mun Hospital, Hong Kong*	184
56	**Unfolded Rib Computed Tomography (URCT): A pictorial review of common rib pathologies, advantages, and technical limitations.** Ho Man To Jason, Yeung Tsz Wai, Fung Sin Yue Cindy, Wong Hei Tung Jamie, Archie Bill Lo, Hon Yu Wai, Chan Wai Yee, Lam Cheuk Kwan, Li Jing Woei *Department of Diagnostic Radiology, Tseung Kwan O Hospital, Hong Kong SAR*	185
57	**Three-Dimensional CT Volumetry for Predicting Node-Specific Pathological Response after Neoadjuvant Therapy in Lung Cancer** Zhebing Lin, Hanxiao Zhang, Mario Pezzella, Dominik V. Flury, Yuyao Zhu, Xinghua Cheng *Department of Oncology, Shanghai Chest Hospital, Shanghai Jiao Tong University School of Medicine, Shanghai, China*	186
58	**Artificial Ascites During Microwave Ablation of Hepatocellular Carcinoma: A Practical Guide from a Tertiary Interventional Oncology Centre** Yueyang Tian, Wa Cheung, Bruno Di Muzio *Department of Radiology, Alfred Hospital, Bayside Health, Melbourne, Victoria, Australia*	187
59	**Initial Local Experience with the Contour Neurovascular System for MCA Bifurcation Aneurysms** Chun Kit Richard Chan, Cherry Cheuk Yan Chan, Lok Hang Yeung, Danny Hing Yan Cho *Department of Radiology and Organ Imaging, United Christian Hospital, Hong Kong SAR*	188
60	**Lymphangiographic Anatomy for Intervention: A Practical Case-Based Pictorial Review** Dr. Janet Wong Hin Man, Dr. Alan YM Chong, Dr. Wisely HH Tang, Dr. John CY Chan, Dr. Dr. Kelvin KH Choi *Department of Raidology, Queen Mary Hospital, Hong Kong SAR*	189
62	**Straight to the Point: Techniques, Feasibility, and Safety of Single-Stick Tunneled Central Venous Catheter Insertion in Adults** Lester WH Shiu *Department of Radiology, Pamela Youde Nethersole Eastern Hospital, Hong Kong*	190

		Page
63	**Management of Lower Limb Pseudoaneurysms from an IR Perspective: A Single-Centre 6-Year Clinical Experience** CK Chan, James K Fung, SY Leung, CK Li, Lester WH Shiu, Kevin H Chin *Department of Radiology, Pamela Youde Nethersole Eastern Hospital, Hong Kong SAR*	191
64	**Splenic Artery Embolization in Blunt Splenic Trauma: A Review of Evidence and Experience at a High-Volume Australian Level 1 Trauma Centre** Yueyang Tian, Fatimath Zaha Ikram, Gerard S. Goh, Matthew Lukies *Department of Radiology, Alfred Hospital, Bayside Health, Melbourne, Victoria, Australia*	192
65	**Evaluation of Safety and Efficacy of Bronchial Artery Embolization Using NBCA-Glue for Patients with Hemoptysis: A Single Center Experience** Wu Lap Yin, Pan Nin Yuan, Ng Fung Him, Wong Ka Hon Stephen, Wong Ho Lim, Stephanie Cheri Woo, Kwok Hoi Ming Kenneth, Cheng Lik Fai *Department of Radiology, Princess Margaret Hospital, Hong Kong SAR*	193
66	**Central venous recanalisation: a pictorial review on tips and tricks** YM Chong, JCY Chan, K Choi *Department of Radiology, Queen Mary Hospital, Hong Kong SAR*	194
67	**Artificial Pleural Effusion for Microwave Ablation of Hepatic Dome Tumours: A Single-Centre Experience** CHAN Ka Yu, CHIN Hoi Kevin *Department of Radiology, Pamela Youde Nethersole Eastern Hospital, Hong Kong SAR*	195
68	**Treating Unicameral Bone Cysts under Fluoroscopy: A Technical Pictorial Review of Aspiration and Intralesional Steroid Injection** KDD Leung *Department of Diagnostic and Interventional Radiology, Queen Elizabeth Hospital, Hong Kong SAR*	196
69	**Beyond the Basics: A Pictorial Essay of Advanced Percutaneous Vertebral Augmentation Techniques** FCT Yip, HL Wong, NY Pan *Department of Radiology & Nuclear Medicine, Tuen Mun Hospital, Hong Kong SAR*	197

		Page
70	**Endovascular Embolization of Chest Wall Elastofibroma with Spontaneous Bleeding: Case Report & Literature Review** Wong Hei Tung Jamie, Salimin Lisley, Lo Bill Archie, Fung Sin Yue Cindy, Ho Man To Jason, Li Jing Woei, Lam Cheuk Kwan *Department of Radiology, Tseung Kwan O Hospital, Hong Kong SAR*	198
71	**A microfluidic system enhances the culture of biliary exfoliated tumor cells from PTCD drainage** Shenbo Zhang, Jie Tang, Kui Zhao, Zhonghe Zhao, Zhengyu Jin, Zhiwei Wang, Rui Chen, Sihang Cheng *Department of Radiology, Peking Union Medical College Hospital, Chinese Academy of Medical Sciences & Peking Union Medical College, Beijing 100730, China*	199
72	**A Novel Therapeutic Approach for Dialysis-Refractory Hypotension in Massive ADPKD via Salvage Renal Artery Embolization (RAE): A Case Report** JUNHO AN, MD *Division of Interventional Radiology, Department of Radiology, SMG Yeonse Hospital, Republic of Korea*	200

MDS 1 **10:30 - 10:45 [GMT+8]** **Saturday, 21 November 2026** **Pao Yue Kong Auditorium (G/F)**

Ultrafast MRI in Management of Breast Cancers

Dr. Eliza Po Yan FUNG
Department of Diagnostic and Interventional Radiology
Kwong Wah Hospital
Hong Kong SAR, China

Ultrafast dynamic contrast-enhanced (UF-DCE) MRI is a novel imaging sequence developed to capture contrast wash-in during the very early post-contrast period with high spatial and temporal resolution. This enables the acquisition of early kinetic parameters, facilitating more refined assessment of contrast dynamics.

Since June 2023, UF-DCE has been incorporated into the conventional breast MRI protocol at the redeveloped Kwong Wah Hospital. Notably, this implementation does not require additional contrast dosage or extra imaging time.

In this lecture, the following topics will be discussed :

1. The imaging protocol and scanning techniques for UF-DCE.

2. Using real-life examples to illustrate the interpretation of early wash-in kinetic parameters, including maximum slope (MS), time to enhancement (TTE), and arterial-venous interval (AVI).

3. An overview of the most recent international and local evidence regarding the clinical applications of UF-DCE. Emphasis will be placed on how current data support its role in improving lesion characterization and refining decision-making, while also addressing practical considerations and future directions for broader clinical implementation.

MDS 2 **10:45 - 11:00 [GMT+8]** **Saturday, 21 November 2026** **Pao Yue Kong Auditorium (G/F)**

BI-RADS v2025 Updates

Dr. Jacqueline Ching Man SITT
Private Practice
Hong Kong SAR, China

This talk aims to give an overview to audience on the major changes of the 6th Edition of the ACR BI-RADS (v2025), with a focus on aspects most relevant to the clinical practice in Asia-Pacific region especially for our local community. Summaries will be made to key changes in the lexicon in the Mammography, Ultrasound and MRI sections. The new section on Contrast Enhanced Mammography will also be introduced and discussed.

Instead of covering the entire booklet of BI-RADS, the presentation takes a "made-easy", flashcard approach to help audience navigate this updated version, and does encourage audience to extend their reading to the corresponding chapters that may draw their interests.

MDS 3 | 11:00 - 11:15 [GMT+8] | Saturday, 21 November 2026 | Pao Yue Kong Auditorium (G/F)

AI in Breast Cancer Imaging

Dr. Lester Chee Hao LEONG
Department of Diagnostic Radiology
Khoo Teck Puat Hospital
Singapore

Artificial intelligence (AI) is becoming an increasingly important adjunct in breast imaging, with potential applications spanning diagnostic support, workflow efficiency, breast cancer risk prediction, and image quality control. This lecture reviews current evidence on how AI is being used in breast imaging and highlights both its promise and its present limitations.

MDS 4 **11:15 - 11:30 [GMT+8]** **Saturday, 21 November 2026** **Pao Yue Kong Auditorium (G/F)**

Localization of Non-Palpable Breast Tumors: A Surgeon's Perspective

Dr. Billy Ho Hung CHEUNG
Department of Surgery
The University of Hong Kong
Hong Kong SAR, China

Introduction

Despite the absence of a universal screening program in Hong Kong, enhanced awareness and advanced imaging have significantly increased detection of impalpable breast disease. Alongside rising rates of breast-conserving surgery, demand for precise tumor localization has increased. Although wire-guided localization remains widely used, alternative techniques offer opportunities to improve surgical planning, patient experience, and coordination between radiology and surgery.

Objectives

The primary objective is to critically review contemporary localization techniques from a surgeon's perspective and to provide a practical framework for multidisciplinary selection.

Main Findings

Wire-guided localization remains an established reference technique, supported by extensive clinical experience and broad availability, but it has limitations in scheduling, patient comfort, and operative flexibility. Intraoperative ultrasound provides real-time guidance without an implanted localizer, but its effectiveness depends on visibility, operator expertise, and sustained visibility during dissection. Radioguided techniques offer reliable localization but require governance of radioactive material, and placement timing depends on the isotope and local regulations.

Non-radioactive wireless technologies, including magnetic seeds, radiofrequency identification tags, and radar reflectors, achieve high localization and retrieval success while allowing marker placement and surgery to be scheduled separately. Their practical limitations vary by device and include MRI artifacts, marker dimensions, detection depth, interference between markers or with surgical instruments, and cost. Selection should therefore reflect lesion characteristics, imaging requirements, and the planned operation.

When approved for prolonged implantation, selected devices can mark the primary tumor and a biopsy-proven metastatic lymph node before neoadjuvant systemic therapy, potentially avoiding an additional localization procedure before surgery. This approach requires consideration of subsequent response imaging and reliable target identification.

Despite consistently high technical success, evidence of superiority in margin clearance and re-excision remains heterogeneous. Successful marker retrieval should not be equated with adequate oncologic excision.

Conclusion

Optimal localization requires matching the technique to the clinical scenario. Close collaboration between radiologists and surgeons is essential. As technologies evolve, the goal remains accurate target removal with appropriate margins, supported by reliable imaging and an efficient patient pathway.

MDS 5 | 11:30 - 12:00 [GMT+8] | Saturday, 21 November 2026 | Pao Yue Kong Auditorium (G/F)

Advances in Adjuvant Systemic and Radiotherapy in Early Breast Cancer

Prof. Roger Kai Cheong NGAN
Gleneagles Hospital
Hong Kong SAR, China

RAD 1 14:00 - 14:20 [GMT+8] Saturday, 21 November 2026 Pao Yue Kong Auditorium (G/F)

A Multidisciplinary Approach to Prenatal Diagnosis of Complex Fetal Structural Abnormalities - FMPRG

Dr. Wing Cheong LEUNG
Department of Obstetrics & Gynaecology
Kwong Wah Hospital
Hong Kong SAR, China

Since April 2021, all pregnant women were eligible for publicly funded whole exome or genome sequencing (WES or WGS) during pregnancy or after a fetal demise or pregnancy termination when they had one or more fetal malformations with uninformative QF-PCR and CMA likely to have an underlying genetic etiology, evaluated by a multidisciplinary team. The multidisciplinary team, with the abbreviation **FMPRG**, was made up of 15 experts in the following specialties: **F**etal **M**edicine (8), **P**athology (1), **R**adiology (1), **G**enetics (3) and the Laboratory (2). Detailed prenatal phenotyping with ultrasound was done by fetal-medicine specialists in prenatal diagnostic clinics. **Additional fetal assessment by fetal magnetic resonance imaging (MRI) was performed in some cases**, depending on the available expertise in different hospitals. The upper gestational limit for termination of pregnancy in Hong Kong is 24 weeks. Further relevant information on the terminated or demised fetuses was gained at postmortem examination if couples agreed. The case summary with anonymous clinical information and radiological and pathological data/images were prepared by case managers in different units and put in the web-based platform via the webmaster for discussion among the panel members. This online platform, which was established by the Department of Pathology of Hong Kong Children's Hospital, could facilitate data sharing and multidisciplinary discussion. For any case submission, the web master notified all panel members via email. The testing criteria of the National Health Service (NHS, England) fetal whole exome service was used as a reference for our panel case selection. Patients were considered eligible for exome or genome sequencing if their fetus had a single major anomaly or multiple organ system anomalies on ultrasound suggestive of a possible genetic etiology after a multidisciplinary review with more than 7 members voting for the test before a pre-set deadline. The selected cases would have the genomic sequencing carried out by one of the two laboratories: the Prenatal Diagnostic Laboratory at Tsan Yuk Hospital using trios WES and the Prenatal Genetic Diagnosis Centre at the Chinese University of Hong Kong using trios WGS.

RAD 2 | 14:20 - 14:40 [GMT+8] | Saturday, 21 November 2026 | Pao Yue Kong Auditorium (G/F)

Introduction to Fetal Imaging

Dr. Claudia CHEUNG
Department of Radiology
Hong Kong Children's Hospital
Hong Kong SAR, China

Advances in prenatal diagnosis have transformed fetal care into a multidisciplinary endeavour involving maternal–fetal medicine, radiology, pathology, and genetics. As imaging, genomics and counseling services become more integrated, complex pregnancies increasingly require coordinated input from several specialties to support families through investigation, prognostication and planning.

In this context, fetal imaging is not simply about making a diagnosis, but about contributing to prognostication, counseling, and clinical decision-making. The place of imaging within the fetal care pathway, basic principles of fetal MRI, common indications, and the practical challenges of performing fetal MRI will be discussed, with emphasis on how radiology supports multidisciplinary management before and after birth.

RAD 3 | 14:40 - 15:00 [GMT+8] | Saturday, 21 November 2026 | Pao Yue Kong Auditorium (G/F)

Post-mortem Imaging: The Present and Future of the Minimally Invasive Autopsy

Prof. Amaka OFFIAH
Clinical Radiology
The Royal College of Radiologists
United Kingdom

When a child dies, families may be faced with difficult decisions about whether to consent to a post-mortem examination. Although conventional autopsy remains the gold standard for determining the cause of death and identifying underlying abnormalities, many parents decline it because of its invasive nature or because of personal, cultural, or religious beliefs. The resulting reduction in autopsy rates created a need for alternative approaches to provide answers while respecting parental wishes.

This talk will explore the development, current practice, strengths and limitations of post-mortem imaging as a minimally invasive alternative to traditional autopsy. It will review the evidence underpinning post-mortem imaging, including studies demonstrating a high level of agreement between imaging findings and conventional autopsy, particularly in sudden unexpected deaths. The presentation will draw on experience from the Sheffield post-mortem imaging service, established in 2012, which offers imaging-based investigations to families who decline a full autopsy and coronial cases.

This talk will discuss how post-mortem imaging can help identify conditions relevant to death, including in coronial cases, provide clinically meaningful information for healthcare professionals, and offer families valuable answers during bereavement. Clinical examples will illustrate situations in which imaging performs particularly well, as well as circumstances in which conventional tissue examination remains essential. Attention will be given to recognised limitations, including the inability of imaging to reliably detect some microscopic diseases and the challenge of distinguishing normal post-mortem change from pathology.

Looking to the future, the presentation will consider how post-mortem imaging is likely to evolve from an alternative offered when autopsy is declined to an integral component of post-mortem investigation pathways. Advances in imaging technology, increasing use of ancillary investigations, the emergence of techniques such as micro-CT, and multidisciplinary integration with genetics, microbiology and placental pathology are creating opportunities for more personalised and less invasive approaches to death investigation. The goal is not to replace conventional autopsy in all situations, but to develop a flexible, family-centred model that maximises diagnostic information while respecting parental choice and supporting legal investigations in coronial cases. In this evolving landscape, post-mortem imaging is poised to play an increasingly important role in fetal, perinatal and paediatric death investigation, providing a bridge between traditional pathology and the future of minimally invasive diagnostics.

RAD 4 **15:00 - 15:20 [GMT+8]** **Saturday, 21 November 2026** **Pao Yue Kong Auditorium (G/F)**

Imaging Beyond Life: Post-mortem Imaging in Perinatal Medicine

Dr. Elaine Yee Ling KAN
Department of Radiology
Hong Kong Children's Hospital
Hong Kong SAR, China

Post-mortem imaging has undergone remarkable growth over the past decade and is increasingly recognised as an important adjunct or alternative to conventional autopsy. It encompasses imaging of fetal losses, perinatal deaths, and unexpected paediatric deaths. This lecture will focus on the role of imaging in fetal and perinatal deaths, highlighting current evidence, practical applications, and international recommendations updates.

Although conventional autopsy remains the reference standard for post-mortem investigation, parental consent is frequently declined because of cultural, religious, or emotional concerns. This has driven the development of minimally invasive post-mortem investigations. Post-mortem magnetic resonance imaging (MRI) has demonstrated high diagnostic concordance with conventional autopsy, particularly for abnormalities of the central nervous system, cardiovascular system, and musculoskeletal system. Conventional radiography and computed tomography (CT) remain invaluable for evaluating skeletal dysplasias, congenital skeletal abnormalities, fractures, and disorders of mineralisation. Ultrasound complements these modalities by facilitating image-guided tissue sampling, targeted biopsies, and focused minimally invasive dissection, thereby improving diagnostic yield while reducing the extent of invasive examination. Recent international recommendations from organisations including the European Society of Paediatric Radiology (ESPR) support an imaging-led, multidisciplinary approach to perinatal death investigation.

This lecture will review the strengths and limitations of each imaging modality, recognise common diagnostic pitfalls, and appreciate the expanding role of post-mortem imaging in confirming prenatal diagnoses, guiding targeted tissue sampling, and supporting genetic counselling. As technology, evidence, and international standards continue to evolve, post-mortem imaging is becoming an indispensable component of modern perinatal medicine.

RAD 5 15:20 - 15:40 [GMT+8] Saturday, 21 November 2026 Pao Yue Kong Auditorium (G/F)

Acute Female Pelvis on CT: What to Look for and What Not to Miss

Dr. Jyothirmayi VELAGA
St Vincent's Health Network Sydney
Australia

Acute pelvic pain in women can be diagnostically challenging, particularly when a gynaecological cause is not initially suspected. This presentation explores the role of CT in identifying acute female pelvic emergencies, including both expected and unexpected gynaecological pathology, focusing on key imaging findings, important mimics and abnormalities that may be overlooked. Selected cases illustrate ovarian and adnexal emergencies, pelvic inflammatory disease, uterine emergencies, complications of endometriosis and other unexpected gynaecological pathology.

Through clinically correlated cases, the presentation provides a practical approach to interpreting the acute female pelvis, with emphasis on recognising direct and indirect signs, avoiding common pitfalls and identifying findings that may require urgent clinical or surgical management.

RAD 6 **15:40 - 16:00 [GMT+8]** **Saturday, 21 November 2026** **Pao Yue Kong Auditorium (G/F)**

The Impact of Molecular Classification in Endometrial Cancer on Radiology Practice

Dr. Elaine Yuen Phin LEE
Department of Diagnostic Radiology, School of Clinical Medicine
The University of Hong Kong
Hong Kong SAR, China

The Cancer Genome Atlas (TCGA) Research Network reclassified endometrial cancer (EC) based on their molecular and genomics profiles. The four molecular subtypes are: 1) POLE ultra-mutated, 2) microsatellite instability hypermutated, 3) copy-number low, and 4) copy-number high, which impact the disease prognosis and adjuvant therapy after surgery. The treatment landscape of EC is evolving based on these new molecular classifications. Specifically, the microsatellite instability hypermutated tumours, characterised by deficient mismatch repair (dMMR), have shown durable response to immunotherapy, prompting the use of immunotherapy combined with platinum-based chemotherapy as the first-line treatment in advanced or recurrent dMMR tumours.

Following the adoption of TCGA classification in clinical practice, the roles of radiologist are expanding when evaluating the pre-operative imaging examinations in EC. The shift away from pure descriptors of the conventional structural invasion, there is a move towards providing more biologically relevant information. Precise and accurate radiological confirmation will downstage POLE ultra-mutated EC and upstage copy-number high EC with abnormal p53 tumour profile. Furthermore, this paths the way to enhance radiogenomics research, where machine learning algorithms extract biologically relevant and high-dimensional data to predict molecular subtype pre-operatively.

During the session, I will walk you through the TCGA molecular classification in EC and its clinical impact on patient's management, and how this clinical shift impacts on daily radiology reporting and sharing local experiences.

RAD 7 **16:30 - 16:50 [GMT+8]** **Saturday, 21 November 2026** **Pao Yue Kong Auditorium (G/F)**

Imaging in Cervical Cancer Staging: The New Standard of Care

Dr. Grace HO
Department of Radiology
Queen Mary Hospital
Hong Kong SAR, China

Cervical cancer remains a significant global health burden, yet it is a disease where accurate staging is paramount for determining prognosis and guiding treatment. Traditionally reliant on clinical examination, the staging paradigm underwent a paradigm shift in 2018 with the FIGO (International Federation of Gynecology and Obstetrics) update, which formally integrated imaging into the staging algorithm. This 20-minute talk will provide a practical, case-based overview of the radiologist's crucial role in the modern staging of cervical cancer, moving beyond the speculum to the scanner.

This presentation will begin by establishing the clinical context, emphasizing the pivotal 2018 FIGO revision which acknowledged that imaging findings—specifically those indicating lymph node involvement (now Stage IIIC) or distant metastases (Stage IVB)—are powerful independent prognosticators. Consequently, the role of imaging has transitioned from a mere adjunct to clinical staging to an essential pillar of the multidisciplinary workup.

We will delve into the technical and practical aspects of the two cornerstone imaging modalities: MRI and PET/CT. The discussion will highlight why MRI, particularly with high-resolution T2-weighted and diffusion-weighted imaging (DWI), is the undisputed workhorse for local and regional assessment. Attendees will learn to identify the key features of primary tumor invasion, including the accurate measurement of tumor size and the critical assessment of parametrial invasion, vaginal extension, and pelvic sidewall involvement, all of which directly inform surgical versus chemoradiation treatment decisions.

Furthermore, we will explore the pivotal role and the complementary value of FDG-PET/CT as whole-body staging in detecting unsuspected nodal metastases in the para-aortic and supraclavicular regions, as well as ruling out distant organ metastases, thereby sparing patients from futile radical local therapy.

Finally, we will address common pitfalls and pearls, including the importance of a dedicated pelvic MRI protocol and the critical distinction between benign reactive nodes and malignant adenopathy. The integration of novel techniques like diffusion-weighted imaging for treatment response assessment will be discussed. Ultimately, this session aims to arm the radiologist with the tools and confidence to provide the precise staging information needed by our oncology colleagues to deliver personalized, life-saving care.

RAD 8 **16:50 - 17:10 [GMT+8]** **Saturday, 21 November 2026** **Pao Yue Kong Auditorium (G/F)**

2D/4D Hysterosalpingo-Contrast-Sonography (HyCoSy) in Tubal Patency Assessment

Dr. Jacky Chun Yin LAU
Department of Radiology
Pamela Youde Nethersole Eastern Hospital
Hong Kong SAR, China

Dr. Jessica Yun Pui LAW
Department of Obstetrics and Gynaecology
Pamela Youde Nethersole Eastern Hospital
Hong Kong SAR, China

We aim to evaluate the clinical utility, diagnostic performance, and share our technical application of hysterosalpingo-contrast-sonography (HyCoSy) as a first-line screening tool for fallopian tube patency among infertile women.

We utilized a sulfur hexafluoride microbubble contrast agent (SonoVue) to assess tubal patency. Imaging was performed using two-dimensional (2D) and/or four-dimensional (4D) ultrasound modalities. The clinical workflow integrated rigorous pre-procedure safety screening, including early follicular phase scheduling (day 7-12), β-hCG screening to exclude pregnancy, and cervical swabs to rule out active pelvic inflammatory disease (PID).

HyCoSy demonstrates high diagnostic accuracy, sensitivity and specificity across different literatures when compared to laparoscopic chromopertubation. While 2D-HyCoSy served as a reliable baseline tool, it remained highly operator-dependent and restricted to a single scanning plane. In contrast, 4D-HyCoSy provided real-time 3D volume imaging, enabling comprehensive spatial visualization of the entire tubal pathway.

Common technical challenges were successfully managed through specific intraoperative troubleshooting, which include uterine spasm, contrast leakage and intravasation.

In conclusion, both 2D and 4D-HyCoSy offer a simple, well-tolerated, and effective outpatient modality for evaluating tubal patency and pelvic anatomy. By eliminating ionizing radiation and the risks of iodinated contrast media, HyCoSy provides a safe, non-invasive alternative to traditional X-ray hysterosalpingography within modern fertility workups.

RAD 9 **17:10 - 17:30 [GMT+8]** **Saturday, 21 November 2026** **Pao Yue Kong Auditorium (G/F)**

Pelvic Floor MRI: Technique and Interpretation

Dr. Jyothirmayi VELAGA
St Vincent's Health Network Sydney
Australia

Pelvic floor MRI is increasingly used to assess pelvic organ prolapse and functional disorders, but obtaining and interpreting a high-quality examination requires more than following a standard protocol. Patient preparation, positioning, instruction and communication can significantly influence the quality and diagnostic value of the study.

This presentation provides a practical approach to pelvic floor MRI, covering patient preparation, positioning and MRI protocol. It explores common technical challenges with practical strategies to optimise patient preparation and examination quality.

A structured approach to interpretation is then presented, including assessment of pelvic organ descent, key anatomical landmarks and pelvic floor function, illustrated with selected clinical cases. Common pitfalls and practical lessons are highlighted throughout.

The presentation aims to demystify pelvic floor MRI by providing a structured and practical approach that can be applied in everyday practice, whether developing a new service or refining an existing one.

ONC 1 **14:00 - 14:20 [GMT+8]** **Saturday, 21 November 2026** **Function Room 1 (2/F)**

Late Effects of Childhood Cancer Treatment

Dr. Nicky THORP
Clinical Oncology
The Royal College of Radiologists
United Kingdom

Remarkable advances in the treatment of childhood and adolescent cancers have transformed survival outcomes, creating a rapidly growing population of long-term survivors. However, cure is increasingly recognised as only one measure of success. Many survivors experience late effects of cancer treatment that emerge months or years after completion of therapy, with significant impacts on physical health, psychological wellbeing, education, employment and quality of life.

This presentation will provide an overview of the spectrum and burden of late effects following childhood cancer treatment, drawing on evidence from major international survivorship cohorts and contemporary clinical practice. Key treatment-related toxicities associated with surgery, chemotherapy and radiotherapy will be discussed, including cardiovascular disease, endocrine dysfunction, neurocognitive impairment, infertility, second malignancies and psychosocial sequelae. Particular emphasis will be placed on radiotherapy-related late effects and factors influencing risk, including age at treatment, dose, fractionation and treatment volume.

The session will also explore strategies for reducing long-term toxicity while maintaining excellent oncological outcomes. Advances in treatment planning, highly conformal radiotherapy techniques and proton beam therapy will be highlighted as examples of approaches that may mitigate the risk of late complications for future survivors. Current international survivorship guidelines and risk-stratified follow-up models will be reviewed, emphasising the importance of lifelong, personalised surveillance and multidisciplinary care.

Through illustrative clinical case studies, attendees will gain insight into the complex medical, psychological and social challenges faced by childhood cancer survivors as they progress through adulthood. The presentation will conclude by considering the leadership role of clinical oncologists in survivorship care, including informed consent, treatment decision-making, long-term risk reduction and advocacy for systems that support lifelong survivor wellbeing. Effective clinical leadership is essential to ensuring that improving survival is matched by an equal commitment to preserving long-term health and quality of life.

Learning Objectives
1. Understand the epidemiology and clinical significance of late effects in childhood cancer survivors.
2. Recognise common organ-specific and psychosocial late effects associated with contemporary cancer therapies.

3. Review approaches to reducing treatment-related toxicity, including advances in radiotherapy techniques.
4. Appreciate the value of risk-based survivorship care and multidisciplinary follow-up.
5. Define the role of the clinical oncologist as a leader in improving long-term outcomes for cancer survivors.

ONC 2 **14:20 - 14:40 [GMT+8]** **Saturday, 21 November 2026** **Function Room 1 (2/F)**

Leadership in Oncology

Dr. Nicky THORP
Clinical Oncology
The Royal College of Radiologists
United Kingdom

Leadership is an essential component of modern oncology practice. As cancer care becomes increasingly complex, multidisciplinary and resource-intensive, oncologists are required not only to deliver excellent clinical care but also to lead teams, influence organisational culture, support colleagues and drive innovation. Effective leadership has a direct impact on patient outcomes, team performance, staff wellbeing and the successful implementation of change within healthcare systems.

This presentation provides a practical and personal perspective on leadership in oncology, exploring why leadership matters at every stage of a clinician's career. The session will examine key attributes of effective leaders, including integrity, self-awareness, empathy, communication skills, strategic thinking and sound decision-making. Particular emphasis will be placed on understanding personal values, motivations and leadership styles as foundations for authentic and effective leadership.

Topics will include managing workforce pressures, balancing competing priorities, supporting colleagues experiencing stress or burnout, addressing professional concerns, and making difficult decisions when resources are limited. These discussions will highlight the importance of compassionate, inclusive leadership in creating high-performing teams capable of delivering high-quality cancer care.

The presentation will also provide practical guidance for oncologists taking on leadership responsibilities. Key skills such as mentoring, developing business cases, leading multidisciplinary teams and chairing effective meetings will be discussed. Attendees will gain practical strategies for fostering engagement, facilitating productive discussions, managing conflict and ensuring that meetings translate into clear decisions and accountable actions.

Finally, the session will reflect on the ethical responsibilities of clinical leaders and the importance of professionalism, transparency and accountability in healthcare. Drawing on established principles of public service and clinical leadership, it will argue that leadership is not confined to formal managerial roles but is a responsibility shared by all oncologists. By developing leadership capabilities, clinicians can help create cultures that support innovation, improve staff experience and ultimately deliver better outcomes for patients with cancer.

Learning Objectives

1. Understand the importance of leadership in delivering safe, effective and patient-centred oncology care.
2. Identify the key characteristics and behaviours of effective clinical leaders.
3. Explore practical approaches to managing challenging leadership situations in oncology practice.
4. Develop skills in communication, team leadership, mentoring and chairing meetings.
5. Recognise the role of every oncologist in shaping organisational culture and improving patient outcomes through leadership.

ONC 3 **14:40 - 16:00 [GMT+8]** **Saturday, 21 November 2026** **Function Room 1 (2/F)**

The Tumour Board Chronicles: Case-based Dilemmas in Gyn-oncology

Dr. Assumpta Sze Man WONG
Department of Obstetrics and Gynaecology
Queen Elizabeth Hospital
Hong Kong SAR, China

Dr. Benny Siu Chun WONG
Department of Radiology
Princess Margaret Hospital
Hong Kong SAR, China

Dr. Richard Wing Cheuk WONG
Department of Pathology
United Christian Hospital
Hong Kong SAR, China

Dr. Philip Yuguang WU
Department of Clinical Oncology
Pamela Youde Nethersole Eastern Hospital
Hong Kong SAR, China

Dr. Winnie Wing Ling YIP
Department of Clinical Oncology
Tuen Mun Hospital
Hong Kong SAR, China

Managing gynecological malignancies demands a dynamic, collaborative approach that transcends individual medical specialties. This highly interactive, case-based educational session simulates a high-functioning multidisciplinary team meeting specifically designed to address complex, real-world clinical scenarios in gynecological oncology. Through a series of challenging patient histories, expert panelists from various clinical oncology disciplines will navigate intricate diagnostic dilemmas, discuss optimal treatment sequencing, evaluate modern surgical interventions, and debate controversial management strategies. Participants will actively engage in the collaborative decision-making process, analyzing how pathology, advanced radiology, and molecular profiling shape personalized patient care plans. By bridging current clinical evidence with diverse specialist perspectives, this session highlights the critical role of tumor boards in breaking down healthcare silos and optimizing long-term patient survival and quality of life outcomes. Ultimately, attending clinicians will gain practical, evidence-based strategies to enhance collaborative reasoning, improve interdisciplinary communication, and elevate the standard of care for individuals facing complex gynecological cancers.

ONC 4 **10:10 - 10:30 [GMT+8]** **Sunday, 22 November 2026** **Function Room 1 (2/F)**

Proton Therapy in Breast Cancer: Where Might It Fit?

Dr. Henry Chun Yip WONG
New York Proton Center
United States

The role of proton therapy in breast cancer remains debated. Its rationale centres on sparing the heart and lung, with the potential to reduce coronary events and pneumonitis, while a lower integral dose may also reduce the theoretical risk of radiation-induced second cancers. It is important to note that the magnitude of any gain is likely to vary with anatomy, laterality, and target volume, making case selection central. This talk explores which patients are most likely to benefit and what to consider when treating them.

Key treatment considerations will be discussed, including model-based selection, which compares predicted reductions in the risk of normal tissue complications between proton and photon plans, as well as baseline cardiopulmonary risk factors and age. Fractionation is then considered in the context of moderate and ultra-hypofractionation, with attention to the increased risk of skin and reconstruction toxicity from larger fraction sizes. Reirradiation for locoregional recurrence or new primary tumours in previously treated volumes is also addressed. Limiting cumulative dose to the heart, lung, chest wall, and brachial plexus may make protons suitable for selected patients, though current evidence is mainly from retrospective and single-arm studies.

Common concerns, including radiation dermatitis and rib fracture, are evaluated based on current evidence, distinguishing data-supported risks from those that may be overstated. The talk also summarises ongoing randomised trials, such as RADCOMP, DBCG Proton, and UK PARABLE, which are expected to report results in the next 5 to 10 years. Until then, an individualised multidisciplinary approach remains the most appropriate strategy.

ONC 5 **10:30 - 10:50 [GMT+8]** **Sunday, 22 November 2026** **Function Room 1 (2/F)**

Precision Ablation Therapy in Gynecological Malignancies and Beyond

Dr. Clement HO
Department of Surgery
University of British Columbia
Canada

Background:
Historically, recurrent and metastatic gynecological malignancies were managed primarily with systemic chemotherapy or low-dose palliative radiotherapy. Stereotactic Body Radiotherapy (SBRT) has emerged as a high-precision modality capable of delivering biologically ablative doses across four clinical scenarios: oligometastatic disease, oligoprogressive disease, salvage pelvic/para-aortic re-irradiation, and primary boosting for brachytherapy-ineligible patients. However, executing SBRT in the female pelvis presents formidable technical and radiobiological challenges due to steep dose gradients immediately adjacent to mobile, hollow, serial organs at risk.

Methods/Evidence Synthesis:
A clinical and dosimetric review of prospective Phase I/II trials and multicenter retrospective registries was conducted to define the therapeutic ratio, organ-specific $EQD2_3$ constraints, and patient selection criteria across these four gynecological SBRT indications.

Results:
In nodal oligometastatic ovarian cancer, the multicenter Phase II MITO-RT3/RAD trial in 2025 demonstrated a 94.4% overall response rate and 92.7% 12-month local control among complete responders, securing a 1-year chemotherapy-free interval for 52.7% of patients (58.4% in complete responders) with 0% Grade 3+ toxicity. For oligoprogression during PARP inhibitor maintenance, the multicenter Epimetheo study in 2025 achieved 86.5% 1-year local control, safely extending oral maintenance therapy and delaying cytotoxic chemotherapy switches in ~50% of patients without unexpected luminal radiosensitization. In salvage re-irradiation for isolated, unresectable pelvic sidewall or para-aortic relapses post-EBRT, 40–45 Gy in 5 fractions yields 65% 3-year local control and about 50% durable disease-free survival when guided by deformable image registration, cumulative $EQD2_3$ summation, and selective PTV underdosing at tethered visceral/neural interfaces. Conversely, while Image-Guided Adaptive Brachytherapy remains mandatory for locally advanced cervical cancer, recent Phase I/II boost studies demonstrate that preventing severe rectal toxicity requires excluding the uninvolved uterine fundus (PTV less than 60-80cm^3), utilizing daily soft-tissue image guidance with narrow margins (2–3 mm), and restricting cumulative rectal D_{2cc} below 80-81.2Gy $EQD2_3$.

Conclusion:
SBRT provides safe, durable local control and meaningfully extends systemic therapy-free intervals in oligometastatic and oligoprogressive gynecological malignancies. In salvage re-irradiation and brachytherapy-ineligible boost settings, strict volume restriction, cumulative $EQD2_3$ adherence, and online adaptive motion mitigation are mandatory to preserve the therapeutic ratio.

ONC 6 **10:50 - 11:10 [GMT+8]** **Sunday, 22 November 2026** **Function Room 1 (2/F)**

Optimising Adjuvant Radiotherapy in Breast Cancer: Less Treatment, Same Outcomes?

Dr. Wendy Wing Lok CHAN
Department of Clinical Oncology
The University of Hong Kong
Hong Kong SAR, China

Adjuvant radiotherapy (RT) remains a cornerstone of breast cancer management, substantially reducing local recurrence and contributing to improved long-term outcomes. However, advances in tumour biology, imaging, systemic therapy, and RT delivery have driven a paradigm shift toward treatment de-escalation, aiming to maintain oncological efficacy while minimising toxicity, treatment burden, and healthcare resource utilisation.

This presentation will review the contemporary evidence supporting RT de-escalation in early breast cancer. First, the evolution of hypofractionation from conventional schedules to ultra-hypofractionated regimens such as FAST-Forward will be discussed, highlighting how shorter treatment courses can achieve equivalent tumour control with acceptable toxicity. Second, the role of accelerated partial breast irradiation (APBI) will be examined, focusing on patient selection and long-term outcomes from trials such as IMPORT LOW and Florence that support reduced treatment volumes in appropriately selected low-risk patients. Third, emerging evidence for RT omission will be explored, including landmark studies such as PRIME II, LUMINA, and IDEA, which suggest that selected patients with favourable clinicopathological and biological features may experience very low recurrence rates without adjuvant RT when treated with endocrine therapy.

Importantly, de-escalation is not appropriate for all patients. The presentation will also discuss situations where treatment intensification remains necessary, including younger age, biologically aggressive disease, nodal involvement, high-risk pathological features, and indications for regional nodal irradiation or tumour bed boost. Current challenges and future directions, including biomarker-guided and genomics-driven RT individualisation, will be highlighted.

As breast cancer care moves toward precision oncology, the goal is no longer simply to deliver effective RT, but to identify the minimum treatment required to achieve optimal outcomes for each patient. This evolving evidence base supports a more personalised approach in which, for many patients, less treatment may indeed result in the same outcomes.

ONC 7 | 11:10 - 11:30 [GMT+8] | Sunday, 22 November 2026 | Function Room 1 (2/F)

Advancements in Systemic Therapies for Breast Cancer

Prof. Rina Yee Man HUI
Centre of Cancer Medicine, School of Clinical Medicine
The University of Hong Kong
Hong Kong SAR, China

NM 1 | 14:00 - 14:20 [GMT+8] | Saturday, 21 November 2026 | Function Room 2 (2/F)

FAPI PET in 2026: Promise, Pitfalls, and a Reality Check

Dr. Terry Pak Lai TSOI
Department of Nuclear Medicine
Pamela Youde Nethersole Eastern Hospital
Hong Kong SAR, China

Fibroblast activation protein inhibitor (FAPI) PET has attracted considerable interest as an imaging approach across multiple solid tumours and as a potential platform for theranostic development. Early enthusiasm was driven by high lesion conspicuity, favourable tumour-to-background contrast, and promising comparative data against other validated approaches in selected malignancies, particularly in stromal-rich gastrointestinal and hepatobiliary setting.

However, the clinical landscape has become more complex with increased experience with FAPI imaging. Accumulating evidence now shows that FAPI uptake is not confined to cancer-associated fibroblasts, but may also be seen in inflammation, fibrosis, wound healing, vascular disease, and a wide range of other benign conditions, complicating oncologic interpretation. As a result, FAPI in 2026 is better understood not as a universal replacement for existing tracers, but as an imaging biomarker of activated fibroblast biology whose value is likely to be indication-specific and context-dependent.

This lecture will review the biologic rationale for FAPI imaging, summarize the current oncologic evidence, and discuss major pitfalls, non-oncologic uptake patterns, and unresolved questions surrounding specificity, and clinical positioning. Attention will be given to tumour types in which FAPI may offer incremental value, as well as to emerging non-oncologic applications that have reshaped understanding of the tracer itself.

The talk will also highlight ongoing phase III FAPI trials in gastroesophageal cancer and pancreatic ductal adenocarcinoma, which may help determine whether FAPI can move from a promising investigational tool to a more clearly defined clinical role. This session aims to provide a pragmatic reality check on where FAPI is most likely to matter, where caution is warranted, and which upcoming evidence may meaningfully change the field.

NM 2 | 14:20 - 14:40 [GMT+8] | Saturday, 21 November 2026 | Function Room 2 (2/F)

Amino Acid PET and PET RANO 1.0 in Neuro-oncology

Dr. Gary Ka Wai CHAN
Nuclear Medicine Unit
Queen Mary Hospital
Hong Kong SAR, China

Conventional contrast-enhanced MRI is the standard for neuro-oncology but struggles to differentiate true glioma progression from treatment-related changes, such as pseudoprogression. This is because MRI primarily measures blood-brain barrier disruption rather than actual tumour cellularity.

Amino acid positron emission tomography (PET), particularly using ^{18}F-FET, overcomes this limitation by targeting L-type amino acid transporters that are highly upregulated in glioma cells. ^{18}F-FET PET has historically demonstrated high diagnostic accuracy using static tumour-to-background ratios and dynamic time-activity curves. Recently, these established kinetic metrics were globally standardized by the Response Assessment in Neuro-Oncology working group through the PET RANO 1.0 criteria. This new framework shifts tumour assessment to 3D volumetric mapping, explicitly defining metabolic tumour volume as any region with radiotracer uptake $\geq$ 1.6 times the healthy background.

By establishing objective thresholds for metabolic progression and response, PET RANO 1.0 provides a reliable tool that correlates strongly with patient survival. Furthermore, the clinical landscape expanded significantly in April 2026 when the U.S. FDA accepted the New Drug Application for the ^{18}F-FET tracer, Pixclara.

Combined with the standardized PET RANO 1.0 criteria, this regulatory milestone marks a major paradigm shift. Amino acid PET has evolved from a specialized research tool into a globally accessible standard for brain tumour characterization and monitoring.

NM 3 | 14:40 - 15:00 [GMT+8] | Saturday, 21 November 2026 | Function Room 2 (2/F)

Molecular Imaging in Neurodegenerative Diseases: From Diagnosis to Therapeutic Decision-making

Dr. Ka Lun CHIU
Nuclear Medicine Unit
Tuen Mun Hospital
Hong Kong SAR, China

Neurodegenerative diseases encompass diverse disorders characterized by progressive neuronal dysfunction, with overlapping clinical manifestations that can complicate diagnosis. Molecular imaging offers insights into their underlying pathology, supporting biological characterization beyond clinical syndromes. Among these disorders, Alzheimer's disease exemplifies how advances in imaging and disease-modifying therapies are reshaping clinical practice, with amyloid and tau biomarkers increasingly contributing to diagnosis, disease staging and therapeutic decisions alongside comprehensive clinical assessment and evaluation.

The development of amyloid positron emission tomography (PET), from carbon-11 Pittsburgh compound B to fluorine-18-labelled tracers, has enabled in vivo assessment of fibrillar amyloid deposition. Visual interpretation remains central to clinical reporting, while Centiloid quantification provides a standardized framework for comparing amyloid burden across validated tracers and analytical methods. Tau PET offers complementary information on the distribution and extent of Alzheimer's-related neurofibrillary pathology, which is more closely associated with clinical phenotype and disease severity. Together, these techniques illustrate the evolution from imaging downstream neurodegeneration towards characterizing the underlying molecular pathology.

Anti-amyloid monoclonal antibodies, including lecanemab and donanemab, have created new clinical indications for biomarker assessment in patients with early symptomatic Alzheimer's disease. Key applications include confirming amyloid pathology, supporting appropriate patient selection and assessing changes in plaque burden during treatment. Evidence from pivotal trials and appropriate use recommendations informs these applications, with particular attention to the distinction between trial eligibility criteria and clinical practice. Serial amyloid PET may also inform donanemab discontinuation after plaque clearance, although this approach should not be generalized to all anti-amyloid therapies. Imaging response must be distinguished from clinical benefit: reduction in amyloid burden does not imply reversal of established cognitive impairment.

Magnetic resonance imaging complements PET by supporting baseline risk assessment and surveillance for amyloid-related imaging abnormalities, including oedema, microhemorrhages and superficial siderosis. Integration of molecular imaging, structural imaging and clinical assessment is central to safe treatment delivery. Recent Hong Kong consensus recommendations provide a local context for applying these principles.

Beyond Alzheimer's disease, emerging tracers targeting non-Alzheimer's tau conformations, α-synuclein and TDP-43 may improve characterization of other neurodegenerative proteinopathies, although their clinical readiness varies considerably. Synaptic vesicle glycoprotein 2A imaging offers a complementary research approach to evaluating synaptic integrity and potentially assessing neuronal preservation beyond plaque removal.

The expanding contribution of molecular imaging lies in translating pathological information into clinically meaningful decisions. Appropriate interpretation, standardized quantification and multidisciplinary collaboration will be important as established biomarkers enter treatment pathways and emerging targets undergo further validation in research and clinical practice.

NM 4 | 15:00 - 15:20 [GMT+8] | Saturday, 21 November 2026 | Function Room 2 (2/F)

The Expanding PET Toolkit in the Clinical Management of Breast Cancer: FDG, FES, and More

Dr. Julio Sing Hon KWOK
Nuclear Medicine & PET Centre
Hong Kong Baptist Hospital
Hong Kong SAR, China

Breast cancer is a highly heterogeneous disease, characterized by distinct tumour biology that varies among or even within patients. Precision imaging is essential to guide effective clinical management.

While FDG PET is the established standard of care for initial staging and therapy response evaluation, its performance may be limited in specific histological subtypes, notably invasive lobular carcinoma.

FES (^{18}F-Fluoroestradiol) PET is valuable for non-invasive whole-body mapping of estrogen receptor (ER) expression. By assessing disease heterogeneity, it assists in decision-making on ER-targeted endocrine therapies and helps resolve diagnostic dilemmas in cases with equivocal results on other imaging.

Looking towards the future, FAPI (Fibroblast Activation Protein Inhibitor) PET tracers offer a novel approach by targeting the tumour microenvironment. They have shown initial promise in detecting metastatic disease that remains occult on FDG PET.

This presentation will focus on the current clinical roles of FDG and FES PET in breast cancer management, with a look into the potential of emerging PET tracers in enhancing precision.

IR 1 | 10:30 - 10:50 [GMT+8] | Sunday, 22 November 2026 | Pao Yue Kong Auditorium (G/F)

Catheter-directed Sclerotherapy of Ovarian Endometrioma: Current Evidences

Dr. Jae Hwan LEE
Department of Radiology
Seoul National University Bundang Hospital
South Korea

Introduction

Ovarian endometrioma affects 17–44% of women with endometriosis and poses a significant clinical challenge due to its association with pelvic pain, infertility, and diminished ovarian reserve. Laparoscopic cystectomy has long been the standard treatment; however, it is associated with a substantial decline in anti-Müllerian hormone (AMH) levels—up to 39.8% at 12 months in a recent randomized controlled trial—raising concerns about irreversible ovarian damage, particularly in women of reproductive age.

Ethanol sclerotherapy has emerged as a minimally invasive, fertility-preserving alternative. Needle-directed sclerotherapy (NDS), first standardized in the 2010s, demonstrated comparable recurrence rates and superior cost-effectiveness compared with surgery in the largest randomized trial to date (n = 167, 20 centres). Building on these results, catheter-directed sclerotherapy (CDS) was introduced in 2018, employing a pigtail drainage catheter via the Seldinger technique to overcome NDS limitations including poor aspiration of viscous cyst content, needle instability, and inability to treat multiloculated cysts.

Since its first description, a growing body of evidence—including prospective studies, retrospective analyses, meta-analyses, and the first pilot RCT (2026)—has demonstrated that CDS achieves 0% recurrence in pooled data, preserves ovarian reserve significantly better than cystectomy (AMH decline 14.9% vs. 39.8%, P = .02), and may improve IVF outcomes with cumulative live birth rates of 65% versus 29% for cystectomy.

This lecture provides a comprehensive overview of the current evidence on catheter-directed sclerotherapy for ovarian endometrioma. Topics include the historical evolution of sclerotherapy, technical comparison of NDS and CDS, evidence from randomized trials and meta-analyses, ovarian reserve preservation, IVF outcomes, safety profile, and future research directions. The target audience is interventional and diagnostic radiologists.

Learning Objectives

- Understand the rationale for sclerotherapy as an alternative to cystectomy for ovarian endometrioma
- Compare the technical features, advantages, and limitations of NDS versus CDS
- Review the current evidence base including the first CDS randomized controlled trial
- Evaluate the impact of CDS on ovarian reserve preservation and IVF outcomes
- Identify research gaps and future directions for catheter-directed sclerotherapy

IR 2 | 10:50 - 11:10 [GMT+8] | Sunday, 22 November 2026 | Pao Yue Kong Auditorium (G/F)

Uterine Fibroid Embolization: Evidence, Technique, and Practical Tips

Dr. William Ho Lim WONG
Department of Diagnostic and Interventional Radiology
Princess Margaret Hospital
Hong Kong SAR, China

Uterine fibroid embolization (UFE) is a minimally invasive, uterus-sparing treatment for symptomatic leiomyomas. This presentation reviews major evidence from the index studies in the field and discuss on common indications an contraindications to support appropriate patient selection. Practical technique is described, including pre-procedural workup, procedural tips, embolic choices and End-points. Practical tips and tricks for optimizing success, reducing radiation dose, and minimizing post-embolization complications are shared. Finally, follow-up imaging and protocols will also be discussed.

IR 3 | 11:10 - 11:30 [GMT+8] | Sunday, 22 November 2026 | Pao Yue Kong Auditorium (G/F)

Prostatic Artery Embolization for Benign Prostatic Hyperplasia

Dr. Hye Doo JUNG
Department of Radiology
Seoul 88 Clinic
South Korea

Background & Purpose
Benign prostatic hyperplasia (BPH) is a primary cause of lower urinary tract symptoms (LUTS) in aging men. While medical therapy and transurethral surgical interventions remain conventional mainstays, prostatic artery embolization (PAE) has emerged as a minimally invasive alternative—particularly for patients seeking to avoid surgical risks or preserve sexual function. This lecture provides a practical, comprehensive overview of PAE in contemporary clinical practice, emphasizing patient selection, procedural techniques, clinical outcomes, and its role in multidisciplinary management.

Patient Selection & Pre-Procedural Evaluation
Successful PAE relies on careful patient selection and a precise understanding of complex pelvic arterial anatomy. Pre-procedural evaluation requires a thorough assessment of LUTS severity, prostate volume, prostate-specific antigen (PSA) levels, urinary flow dynamics, and post-void residual volume. Pre-interventional imaging is essential to evaluate vascular anatomy and exclude alternative causes of urinary dysfunction.

Technical Execution
Executing PAE safely requires superselective catheterization of the prostatic arteries and diligent identification of collateral branches to prevent non-target embolization. Advanced imaging tools, including cone-beam CT (CBCT) and 3D angiography, facilitate accurate identification of variable prostatic arterial supply, optimizing technical success and procedural safety.

Clinical Outcomes & Practical Considerations
PAE consistently yields meaningful improvements in LUTS, overall quality of life, urinary flow parameters, and prostate volume reduction, with a low incidence of major complications. Key clinical advantages include its minimally invasive nature, avoidance of general anesthesia, short recovery period, and minimal risk of sexual dysfunction. However, practitioners must consider technical complexities, anatomical variations, radiation exposure, and the potential need for reintervention over time.

Conclusion
PAE represents a critical, minimally invasive therapeutic option for appropriately selected patients with symptomatic BPH. Understanding its indications, technical challenges, and limitations is vital for integrating PAE into multidisciplinary urological care. Practitioner experience and rigorous patient selection remain the key drivers of favorable clinical outcomes.

IR 4 | 11:30 - 11:50 [GMT+8] | Sunday, 22 November 2026 | Pao Yue Kong Auditorium (G/F)

MRI-guided Intervention: Renal Cell Carcinoma Cryoablation

Dr. Pan Pan NG
Department of Diagnostic and Interventional Radiology
Queen Elizabeth Hospital
Hong Kong SAR, China

Percutaneous cryoablation is an established nephron-sparing treatment option for selected patients with renal cell carcinoma (RCC), particularly those with small renal masses, significant comorbidity, a solitary kidney, hereditary tumour syndromes, or impaired renal function.

MRI guidance offers distinctive advantages for renal cryoablation. Its superior soft-tissue contrast can facilitate targeting of renal lesions that are poorly visualised on ultrasound or CT. MRI also enables visualisation of the cryoablation ice ball, allowing assessment of ablation-zone coverage and its relationship to adjacent vulnerable structures, without ionising radiation or contrast media. These advantages may be particularly relevant for endophytic, hilar-adjacent, or CT-occult lesions, where accurate targeting and confidence in treatment margins are important.

The technique requires a purpose-built workflow, MRI-compatible equipment, robust MR-safety practice, and close multidisciplinary coordination among the interventional radiologist, MRI radiographers, nursing staff, anaesthetists, and urology team. This lecture will provide an interventional radiology framework for MRI-guided RCC cryoablation, covering patient selection, pre-procedural assessment, procedural workflow, and key technical considerations.

IR 5 | 11:50 - 12:10 [GMT+8] | Sunday, 22 November 2026 | Pao Yue Kong Auditorium (G/F)

Debulking with Rotarex: A Clinical Perspective

Dr. Jihoon KIM
Department of Radiology and Research Institute of Radiology
University of Ulsan College of Medicine, Asan Medical Center
South Korea

Peripheral arterial occlusive disease often consists of a heterogeneous mixture of thrombus, neointimal tissue, and atherosclerotic plaque. In selected complex lesions, balloon angioplasty alone may restore luminal diameter without sufficiently reducing the underlying tissue burden. The Rotarex rotational excisional atherectomy system combines mechanical modification, excision, and continuous aspiration, providing simultaneous debulking and thrombus removal. This lecture will present a practical, case-based approach to Rotarex use in three major clinical scenarios: femoropopliteal in-stent restenosis (ISR), thrombosed bypass grafts, and acute limb ischemia (ALI).

In ISR, particularly long-segment restenosis or total in-stent occlusion, the procedural goal is not simply to create a channel but to reduce the intrastent tissue burden before definitive treatment. Effective debulking may improve luminal gain and facilitate subsequent drug-coated balloon angioplasty while potentially reducing the need for additional stent implantation. Careful device manipulation is essential, with controlled advancement and avoidance of aggressive drilling or excessive interaction with stent struts.

In bypass graft occlusion, Rotarex can rapidly remove thrombotic and organized material and restore flow through the graft. However, thrombus removal alone is rarely sufficient. After debulking, the underlying cause of graft failure should be systematically reassessed, including the inflow artery, graft body, anastomoses, and distal outflow. Particular caution is required when approaching anastomotic sites, where excessive mechanical stress should be avoided. Residual stenosis can then be treated selectively with balloon angioplasty or stenting when necessary.

In ALI, mechanical debulking offers the potential advantage of rapid thrombus reduction and early restoration of antegrade flow. This may reduce the need for prolonged catheter-directed thrombolysis in appropriately selected patients. Nevertheless, Rotarex thrombectomy should be considered one component of a complete revascularization strategy. Distal runoff should be carefully reassessed after debulking, and adjunctive aspiration, thrombolysis, angioplasty, or stenting may be required for residual thrombus or an underlying causative lesion.

Across all three indications, technical discipline is critical. Stable guidewire positioning, adequate sheath support, progressive short back-and-forth passes rather than forceful advancement, frequent saline flushing, and repeated angiographic assessment of inflow and runoff are key procedural principles.

Ultimately, Rotarex should be viewed not simply as a thrombectomy device, but as a vessel-preparation platform that converts a complex occlusive lesion into a simpler lesion for more precise definitive treatment.

IR 6 | 12:10 - 12:30 [GMT+8] | Sunday, 22 November 2026 | Pao Yue Kong Auditorium (G/F)

TEVAR: A Sunset Industry for Interventional Radiology?

Dr. Kelvin Kin Ho CHOI
Department of Radiology
Queen Mary Hospital
Hong Kong SAR, China

Historically, interventional radiology claimed its clinical territory in aortic interventions such as Thoracic Endovascular Aortic Repair (TEVAR) through the exclusive ownership of infrastructure, such as the angiography suite, and held exclusivity over image acquisition and interpretation. Today, this landscape is experiencing a massive paradigm shift as angiography labs rapidly transform into hybrid operating theatres, and imaging facilities are no longer exclusively owned by radiologists. As endovascular techniques are increasingly adopted across multiple specialties, standard aortic repairs are steadily migrating out of our clinical domain, raising a critical question: Is this procedure becoming a sunset industry for interventional radiology?

This presentation challenges the notion of interventional radiology obsolescence in aortic repair, demonstrating that while structural assets are shifting, the core necessity for specialized radiology expertise remains indispensable. While advanced imaging infrastructure and hybrid theatres can be readily acquired through capital-expenditure resources, endovascular experience and tactical intuition cannot be instantly replicated. Through a series of case studies, this talk will demonstrate that core competencies, including precise endovascular skills, advanced 3D anatomical case planning, and strategic troubleshooting like complex endoleak embolization, are entirely achievable skills that any interventional radiologist can master and bring to the table.

These high-tier technical skills can obviously be acquired by others through sustained clinical practice, interventional radiologists therefore cannot afford to be complacent. We must actively evolve and establish our value at both the personal and institutional levels. Ultimately, the goal is to cultivate a robust co-habitant model and a strong multidisciplinary partnership where teams are equally valued to provide the best possible care for the patient as a collaborative aortic team.

PM 1 | 11:30 - 11:50 [GMT+8] | Sunday, 22 November 2026 | Function Room 1 (2/F)

Stereotactic Radiosurgery for Brain Metastases in Oncogene-addicted Non-small Cell Lung Cancer Patients Treated with Tyrosine Kinase Inhibitor

Dr. Elki Sze Nga CHEUNG
Department of Clinical Oncology
Pamela Youde Nethersole Eastern Hospital
Hong Kong SAR, China

Background: For patients with advanced oncogene-addicted non-small cell lung cancer (NSCLC), the development of brain metastases represents a critical turning point, often accompanied by a significant symptom burden that profoundly impacts quality of life. The core goals of management in this palliative setting are to control neurological symptoms, preserve neurocognitive function, and extend meaningful survival. The advent of tyrosine kinase inhibitors (TKIs) and the increasing use of stereotactic radiosurgery (SRS) have transformed the therapeutic landscape, yet the optimal integration of these modalities to maximize palliative benefit remains an area of active investigation.

Objectives: This study aimed to evaluate intracranial progression-free survival (iPFS), overall survival (OS), local control (LC), distant brain failure-free survival (DFFS) and treatment-related toxicities in a cohort of oncogene-addicted NSCLC patients with brain metastases treated with SRS while on TKI treatment. We sought to identify predictive and prognostic factors for these outcomes, with a particular focus on the interaction between TKIs and SRS.

Methods: We retrospectively reviewed all consecutive patients with oncogene-addicted NSCLC who received SRS for brain metastases at Pamela Youde Nethersole Eastern Hospital (PYNEH) between December 2014 and June 2025. Patient, tumor, and treatment characteristics were collected. Survival outcomes were analyzed using the Kaplan-Meier method and Cox proportional hazards regression. Statistical analysis was performed using SPSS version 22 and GraphPad Prism version 10.6.1.

Results: A total of 75 patients who received a first course of SRS were included in the survival analysis. The median follow-up was 52.2 months. The 2-year rates for iPFS, OS, and LC were 53%, 61%, and 96%, respectively. In the multivariate analysis for iPFS, the presence of multiple brain metastases (HR 2.38, 95% CI 1.25-4.57, p=0.01) and progression on TKI (HR 2.17, 95% CI 1.14-4.12, p=0.02) were independent predictors of worse iPFS. For OS, only ECOG performance status ≥2 was an independent predictor of worse survival (HR 3.45, 95% CI 1.33-8.94, p=0.011). Symptomatic radionecrosis(RN) occurred in 9.6% of treated lesions.

Conclusion: SRS provides excellent local control for brain metastases in oncogene-addicted NSCLC, though distant intracranial progression remains the primary palliative challenge. Multiple lesions and progression while on TKI independently predict worse iPFS, a finding critical for prognostic counseling and shared decision-making. These findings underscore the need for integrated, multidisciplinary palliative care to preserve neurological function, minimize treatment-related harm, and maintain quality of life in this vulnerable population.

PM 2 | 11:50 - 12:10 [GMT+8] | Sunday, 22 November 2026 | Function Room 1 (2/F)

Lutetium-177: An Emerging Palliative Treatment Option in the Chinese Population with Metastatic Castration-resistant Prostate Cancer (mCRPC) – Current Data and a Single Center Experience in Hong Kong

Dr. Ken Ka Shing WONG
Department of Clinical Oncology
Pamela Youde Nethersole Eastern Hospital
Hong Kong SAR, China

Background: Metastatic castration-resistant prostate cancer (mCRPC) continues to be a significant challenge worldwide in oncology, especially since treatment choices become limited when patients no longer respond to androgen receptor pathway inhibitors (ARPi) or chemotherapy. Novel radioligand therapy such as Lutetium-177 (Lu-177) transformed prostate cancer treatment landscape. In Western countries, Lutetium-177 (Lu-177) labelled PSMA ligands are a key therapeutic option with growing evidence in mCRPC post-chemotherapy or ARPi. Here we report some realworld experience among Chinese population in Hong Kong

Conclusion: Early real-world experience from Hong Kong demonstrates that Lu-177 therapy is a feasible, safe, and tolerable option for Chinese patients with mCRPC, including those who were heavily pre-treated. These findings support broader regional adoption of radioligand therapy and underscore the importance of expanding Asian specific datasets to refine patient selection, guide implementation, and optimize outcomes as novel radioligand therapies continue to evolve globally

PM 3 | 12:10 - 12:30 [GMT+8] | Sunday, 22 November 2026 | Function Room 1 (2/F)

Prognostic Modeling - Conventional Statistics, AI and Beyond

Dr. Ka Man CHEUNG
Department of Clinical Oncology
Queen Elizabeth Hospital
Hong Kong SAR, China

Accurate survival prediction is important in palliative cancer care. It supports communication with patients and families, treatment decisions, advance care planning, hospice referral, and allocation of healthcare resources. However, prognosis is influenced by a broad range of clinical, functional, psychological, and social factors. Their relationships may be complex and can be difficult to capture in a single prediction model.

This talk describes our experience of developing prognostic models using two approaches. The first approach, using the well-known methodology of multivariable logistic regression, identified five predictors of 60-day outcome: poor appetite, peripheral oedema, elevated white blood cell count, low lymphocyte count, and elevated bilirubin. The model had an area under the receiver operating characteristic curve of 0.782, and its performance was maintained after bootstrap validation. Although the model was practical and used routinely available information, its development raised questions about conventional variable selection, particularly when symptoms, laboratory findings, and psychosocial factors were closely related.

We subsequently used an expanded cohort to develop multilayer perceptron neural-network models for survival at 30, 90, and 180 days. The models included 32 predictors covering demographic, physical, psychological, social, disease-related, functional, and laboratory domains. The areas under the curve were 0.842, 0.830, and 0.746 for the three time points, respectively. Feature-importance analysis showed different patterns across the prediction horizons. Laboratory abnormalities, performance status, and physical symptoms were prominent in short-term prediction. Depression and living alone had greater relative importance in the 180-day model. These findings suggest that psychosocial information may add to longer-term survival prediction, although feature importance should not be interpreted as an independent effect or evidence of causation.

The talk will also discuss four possible directions for future work. Bayesian methods regularise correlated predictors and provide a clearer account of uncertainty around individual predictions. Dynamic models could update prognosis when symptoms, performance status, and laboratory results change. Randomised trials could then assess whether specific psychological or social-support interventions improve quality of life and, as a secondary question, survival. Finally, prospective evaluation is required to assess whether prognostic models improve decisions, communication, and patient care in practice.

Rather than viewing regression and AI as competing approaches, both can contribute to prognostic research. Future models should be accurate, well validated, clinically interpretable, responsive to change along patient trajectory, and used alongside clinical judgement and patients' values.

AI 1 | 14:10 - 14:30 [GMT+8] | Sunday, 22 November 2026 | Run Run Shaw Hall (1/F)

The Effect of Artificial Intelligence on the Radiologist Workforce

Prof. Curtis LANGLOTZ
Department of Radiology
Stanford University
United States

The effect of artificial intelligence (AI) algorithms on the radiology workforce has been a subject of commentary and controversy since the beginning of the latest wave of AI. In 2016, some predicted, "We should stop training radiologists now." Others predicted that AI would augment, not replace radiologists: "Will AI replace radiologists? The answer is NO. But radiologists who use AI will replace radiologists who don't."

There is now sufficient published evidence to support a quantitative task-based analysis to predict these effects and resolve these questions. We will present a quantitative, task-based model to predict the effect of AI on the radiology workforce over a 5-year time horizon using the best available published evidence. When published evidence was unavailable, we used expert judgment.

The model projects AI applications likely will cause a significant decrease in radiologist hours worked. But given the relatively static radiology workforce and the continued growth in imaging volumes, radiologist job loss is unlikely for the foreseeable future.

The details of our analysis are available here:
https://www.medrxiv.org/content/10.64898/2025.12.20.25342714v1

AI 2 | 14:30 - 14:50 [GMT+8] | Sunday, 22 November 2026 | Run Run Shaw Hall (1/F)

Governance of Artificial Intelligence in Healthcare: A Glocal Perspective

Prof. Gilberto Ka Kit LEUNG
Department of Surgery
School of Clinical Medicine, LKS Faculty of Medicine, The University of Hong Kong
Hong Kong SAR, China

Good governance is an essential enabler of innovation, not a hindrance to progress. In the realm of medical AI—characterised by rapid and disruptive advancement and profound uncertainties about emergent risks—robust governance builds the public trust necessary for safe, responsible, and widespread adoption. Without clear rules and accountability, fear and fragmentation will stifle investment and slow progress. By establishing shared standards for transparency, fairness, and risk management, governance creates a stable ecosystem where developers and enterprises can innovate responsibly, and where the role and responsibility of users are more clearly delineated.

Yet, considerable challenges exist. AI-enabled tools can continuously learn and evolve, rendering static regulatory control obsolete. Even the very nature of AI defies traditional classification, raising the question about whether such systems are in fact "medical devices". Liability is equally fraught, as accountability may be diffused across developers, healthcare service providers, and clinicians who relied on its output. Concerns about data privacy and biases add further complexity. An effective governance framework must therefore be dynamically adaptive, clinically informed, and human-centric.

The author aims to discuss the pertinent issues and provide an overview of AI governance models across key jurisdictions, including the EU's risk-based framework, the US's sectoral and industry-led approach, and China's state-centric, legislation-heavy regulatory model. The talk will then examine the approach Hong Kong may adopt—one that should ideally be balance safety with innovation, international alignment with local needs, and societal benefit with individual welfare.

AI 3 | 14:50 - 15:10 [GMT+8] | Sunday, 22 November 2026 | Run Run Shaw Hall (1/F)

The Next Frontier of AI-enabled Healthcare: From Bench to Practice

Prof. Yike GUO
Office of the Provost
The Hong Kong University of Science and Technology
Hong Kong SAR, China

AI 4 | 15:30 - 15:40 [GMT+8] | Sunday, 22 November 2026 | Run Run Shaw Hall (1/F)

From Pilot to Practice: AI Deployment in Radiology in Hong Kong

Dr. Keith Wan Hang CHIU
Department of Diagnostic and Interventional Radiology
Queen Elizabeth Hospital
Hong Kong SAR, China

Artificial intelligence (AI) is reshaping healthcare worldwide. Radiology, arguably the most digitised and standardised medical specialty, has led the way in model development and deployment. In Hong Kong, both commercially available and locally deployed AI tools are now used across both public and private radiology departments. Some operate behind the scenes, reducing image acquisition time and triaging the reporting priority of scans, while others support frontline pathology detection and image interpretation.

The transition from pilot to practice, however, has not been straightforward. Embedding AI into picture archiving and communication systems (PACS) without adding friction to already demanding reporting workflows, and securing buy-in from radiologists and referring clinicians alike posed both expected and unexpected challenges. The shift from narrow, single-task models to broad foundation-model systems raises new questions of accountability, data governance, and post-deployment monitoring. Our experience, we hope, can inform others as they develop deployment pathways that are sustainable, equitable, and patient-centred.

AI 5 | 15:40 - 15:50 [GMT+8] | Sunday, 22 November 2026 | Run Run Shaw Hall (1/F)

The AI Application in Healthcare System of China

Prof. Zhengyu JIN
Radiology Department
Peking Union Medical College Hospital
China

To provide a systematic overview of artificial intelligence (AI) applications across the Chinese healthcare system, from national policy to routine clinical deployment.

Policy documents, regulatory announcements, NMPA certification records, market reports and peer-reviewed literature (2017-2025) were reviewed; policy milestones, the regulatory framework for AI medical devices, market data and deployed clinical applications in mainland Chinese hospitals were analysed and synthesised.

Since the State Council's New Generation AI Development Plan (2017), a mature regulatory framework has been established. The National Medical Products Administration (NMPA) classifies AI software as Class II or III medical devices requiring real-world clinical validation; by 2024, more than 60 Class III certificates had been issued, approximately 75% in medical imaging. China's medical AI solutions market reached an estimated RMB 16.4 billion in 2024 (annual growth >28%), making China the world's second-largest AI healthcare market. In clinical practice, radiology leads deployment: lung nodule detection and volumetric follow-up, coronary CTA stenosis grading and calcium scoring, head-and-neck CTA for acute stroke triage, intracranial haemorrhage quantification and paediatric bone-age assessment are integrated into routine PACS/RIS workflows, with reported turnaround-time reductions of 30-50%. Beyond diagnosis, AI is expanding into imaging quality control, smart worklist prioritisation, real-time department performance dashboards and AI-assisted diagnosis in primary care, supported by a national pricing pathway opened in 2025. Remaining challenges include data privacy, cross-hospital generalisation and sustainable reimbursement.

Policy, regulation, industry and clinical practice in China have aligned to move medical AI from pilot projects to population-scale deployment. Multimodal foundation models, the shift from single-task tools to multi-disease platforms, and autonomous reporting workflows are expected to further transform radiology and the wider healthcare system, offering transferable lessons for other health systems.

AI 6 | 15:50 - 16:00 [GMT+8] | Sunday, 22 November 2026 | Run Run Shaw Hall (1/F)

Scaling AI Safely: Lessons Learned from the NHS Experience

Dr. Stephen HARDEN
The Royal College of Radiologists
United Kingdom

The United Kingdom's National Health Service (NHS) faces unprecedented operational pressures, with surging diagnostic demands, a chronic and worsening shortage of clinical workforce, and substantial post-pandemic backlogs. There is growing interest in how AI algorithms can help the workforce to become more efficient and more effective. One of the major challenges is to transition artificial intelligence from isolated local hospital pilots into integrated, system-wide clinical tools.

Early experience has been developed in more widely scaling AI tools which have had some proven benefit, including in lung cancer screening with low dose CT and in diagnostic support for stroke. The AI development fund invested in the wider use of AI tools to act as a second pair of eyes in chest x-ray assessment to reduce backlogs and speed up lung cancer diagnosis. This is now being scaled nationally in England.

In clinical oncology, auto-contouring AI tools have been deployed nationally to help identify organs at risk as part of radiotherapy planning and this has significantly reduced planning time, so increasing productivity.

This presentation will explore these in more detail and discuss the hurdles to be overcome in national deployments beyond procurement and regulatory approval, including governance, vendor neutral deployment platforms, central funding, clinical leadership and ensuring that hospital departments are AI ready. We are clear that this is not intended to replace human expertise, or the role of healthcare practitioners in cancer detection and treatment, but to enable these processes to become more efficient while assuring patient safety.

AI 7 | 16:00 - 16:10 [GMT+8] | Sunday, 22 November 2026 | Run Run Shaw Hall (1/F)

AI in Radiology Across Asia-Oceania: Building Capacity, Equity and Trust

Dr. Chamaree CHUAPETCHARASOPON
Asian Oceanian Society of Radiology
Thailand

The rapid advancement of artificial intelligence presents both opportunities and challenges for radiology communities across Asia and Oceania. As healthcare systems vary widely in resources, workforce capacity, digital maturity, and regulatory readiness, a regional approach is essential to ensure that the benefits of AI are shared responsibly and equitably.

This presentation will provide a perspective from the Asian Oceanian Society of Radiology (AOSR) on the role of professional societies in supporting the adoption of AI across diverse healthcare environments. Rather than focusing on specific technologies, the session will highlight practical initiatives undertaken by AOSR to strengthen regional preparedness, including the development of educational resources, foundational training frameworks, and collaborative efforts addressing trustworthy and responsible AI use in radiology.

The presentation will also reflect on the importance of regional collaboration among member societies, academic institutions, and subject matter experts in addressing common opportunities and challenges. Particular emphasis will be placed on the principles of capacity building, equity, and trust as guiding considerations for future AI adoption.

As AI continues to evolve, sustained engagement, knowledge sharing, and collaboration will remain essential. AOSR is committed to continuing this journey through partnerships with its member societies and dedicated committees to help ensure that innovation serves both the profession and the patients we care for.

AI 8 | 16:10 - 16:20 [GMT+8] | Sunday, 22 November 2026 | Run Run Shaw Hall (1/F)

Vibe Coding and Agentic AI as a Radiologist

Prof. Sungil HWANG
Department of Radiology
The Korean Society of Radiology
South Korea

Vibe coding is a workflow in which users describe desired software behavior in natural language and large language models (LLMs) generate the code. It is increasingly used by non-developer clinicians without formal programming training to create tools supporting clinical workflows. This development is both timely and consequential for radiology, one of the specialties most exposed to artificial intelligence (AI)-driven automation and best positioned to adopt it, because of its longstanding engagement with imaging AI, digital infrastructure, and information system workflows. Radiologists may therefore become not merely passive AI users but clinical workflow orchestrators. This opportunity is illustrated by a structured prostate magnetic resonance imaging reporting tool, vibe-coded by a non-developer radiologist in approximately four hours, and an institution-based voluntary, radiologist-led coding community. Four cautions are highlighted: erosion of domain expertise, risks to security and patient data, absence of peer feedback, and uncoordinated proliferation of tools. A minimum safeguard set for clinician-built tools is proposed. As previously framed, LLMs represent a “fire of Prometheus” for non-native English-speaking researchers. Similarly, vibe coding may warm and burn radiologists in equal measure, with its impact determined less by the technology than by how responsibly the specialty adopts it.

AI 9 | 16:20 - 16:30 [GMT+8] | Sunday, 22 November 2026 | Run Run Shaw Hall (1/F)

Future of Radiology in Japan with AI

Prof. Kei YAMADA
Department of Radiology
Kyoto Prefectural University of Medicine
Japan

The so-called third boom of artificial intelligence (AI) has had a profound impact on the field of radiology. Early in this boom, Prof. Hinton commented that "people should stop training radiologists because in 5 years the computers will outdo humans," which was particularly sensational. Made in 2016, this statement popularized the idea that AI would eventually replace radiologists, significantly influencing the career choices of medical students and junior doctors. This mindset contributed to a temporary drop in residency applicants starting around 2021 (Fig. 1). Although the application trend appeared to normalize, a renewed decline may be emerging this year (2026)—likely driven by the recent rise of Large Language Models (LLMs).

This trend poses a critical challenge, as Japan already faces a substantial shortage of radiologists. In fact, approximately half of all cross-sectional imaging studies (i.e., CT, MRI, and PET) are currently interpreted by non-radiologist clinicians [1].

In this presentation, I will share my perspective on the future of medical AI [2]. I will also discuss the viewpoints of radiologists in Japan, highlighting a generally optimistic outlook toward AI integration that is largely driven by an overwhelming workload. Finally, I will address the current state of Japan's reimbursement system for AI, established in 2023 [3]. Unlike in many Western countries, Japanese radiologists have largely welcomed these reimbursement policies; I will explain the unique context behind this favorable reception.

References

1. Yamada K. What Has Caused the Shortage of Radiologists? Features Exclusive to Japan. Korean J Radiol. 2023; 24: 933-935.
2. Yamada K, Mori S. The day when computers read between lines. Jpn J Radiol. 2019; 37: 351-353.
3. Hirata K, Miyake M, Yamada K. Access and reimbursement for artificial intelligence in radiology: A Japanese perspective. Korean J Radiol. 2026; 27(3): 202-204

JRS Board Certification Examination

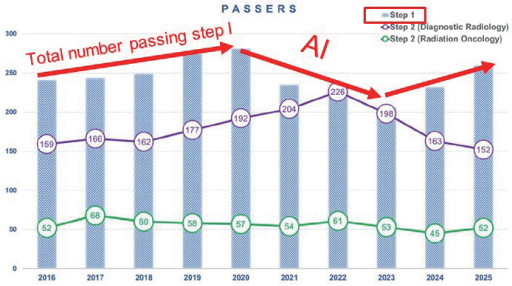

Date of Exam:
August 22-23, 2025

Location:
Tokyo
(The New Otani)



During the examination...



Oral examination
15 minutes × 4 rooms



Source: https://www.newotani.co.jp/en/tokyo/access/

SS 1 12:30 - 13:00 [GMT+8] Saturday, 21 November 2026 Function Room 1 (2/F)

Metastatic Melanoma and irAE Management: Clinical Perspective and Updates in Management

Prof. Aya EL HELALI
Department of Clinical Oncology
The University of Hong Kong
Hong Kong SAR, China

Advanced melanoma comprises biologically and clinically distinct subtypes, and evidence supporting systemic treatment is not uniform across cutaneous and mucosal disease. This lecture will begin by contrasting the treatment considerations for cutaneous and mucosal melanoma. It will highlight the more mature prospective evidence base available for cutaneous melanoma while emphasizing individualized multidisciplinary decision-making for mucosal melanoma, taking into account the primary disease site, molecular profile, disease burden, pace of progression, patient fitness and treatment objectives.

The lecture will then review the final 10-year results from CheckMate 067 and consider how durable overall survival, melanoma-specific survival and sustained disease control inform first-line treatment selection in advanced cutaneous melanoma. The clinical rationale for nivolumab plus ipilimumab will be discussed alongside anti–PD-1 monotherapy, with appropriate recognition of differences in toxicity and patient suitability. The discussion will be placed in the context of international treatment guidelines, emphasizing that dual checkpoint blockade is an important preferred option for appropriately selected patients rather than a universal approach for every patient.

For patients with BRAF V600-mutant melanoma, treatment sequence represents an additional critical decision. The DREAMseq study provides prospective evidence supporting an immunotherapy-first sequence for most treatment-naïve patients, while preserving BRAF/MEK-targeted therapy as an effective subsequent option. Clinical circumstances that may require an alternative strategy, including an urgent need for rapid disease control or a contraindication to immunotherapy, will also be considered.

The second half of the lecture will focus on the safe delivery of immune checkpoint inhibitors. A practical framework for immune-related adverse-event management will cover early recognition, treatment interruption, exclusion of alternative diagnoses, organ-specific grading, corticosteroid initiation, monitoring and multidisciplinary escalation.

Particular attention will be given to myocarditis–myositis–myasthenia gravis overlap syndrome, commonly described as “Triple M.” The discussion will address its potentially rapid multisystem progression, key cardiac, neuromuscular, bulbar and respiratory warning signs, and the need for urgent coordinated assessment. Management principles will include early high-dose intravenous corticosteroids for severe presentations, close monitoring of clinical status and relevant biomarkers, and prompt escalation when the patient fails to improve or continues to deteriorate. The potential roles of intravenous immunoglobulin, plasma exchange and additional immunosuppressive or immunomodulatory therapies in refractory cases will be discussed according to the dominant organ toxicity, current guidance and local specialist expertise.

SS 2 13:00 - 13:30 [GMT+8] Saturday, 21 November 2026 Function Room 1 (2/F)

NEOTORCH: Expanding the Possibilities of Perioperative Immunotherapy in Resectable Stage III NSCLC

Prof. Victor Ho Fun LEE
Department of Clinical Oncology
The University of Hong Kong
Hong Kong SAR, China

Resectable stage III non-small cell lung cancer (NSCLC) remains a clinically challenging and heterogeneous disease, requiring multidisciplinary assessment to optimise systemic therapy and surgery. The NEOTORCH study (NCT04158440) has generated an evolving body of evidence supporting perioperative immunotherapy in this setting, among other published and ongoing studies on pre/perioperative therapy in early-stage NSCLC.

In 2023, NEOTORCH marked an important milestone in perioperative immunotherapy. Presented at the April ASCO Monthly Plenary Series, NEOTORCH was the first phase III study of an anti-PD-1 antibody incorporating both neoadjuvant and adjuvant treatment to report a positive event-free survival (EFS) result in NSCLC. In patients with resectable stage III disease, toripalimab plus chemotherapy reduced the risk of recurrence, progression or death by **60%** versus chemotherapy alone (HR 0.40; P<0.001).

In 2024, the full results published in *JAMA* further established the NEOTORCH perioperative strategy. The study focused predominantly on stage III disease and introduced the "3+1+13" regimen: three cycles of neoadjuvant chemoimmunotherapy, one postoperative cycle, followed by up to 13 cycles of toripalimab maintenance. Major pathological response was **48.5% versus 8.4%**, pathological complete response was **24.8% versus 1.0%**, and 2-year EFS was **64.7% versus 38.7%**.

In 2026, a surgical outcomes analysis published in *JAMA Surgery* provided further insights. Fewer patients receiving toripalimab had surgery cancelled **(17.8% vs 26.7%)**, while tumour downstaging **(80.7% vs 50.7%)** and nodal downstaging **(67.5% vs 48.6%)** were significantly higher. Both tumour and nodal downstaging were associated with improved EFS.

At ESMO 2026, NEOTORCH enters its next chapter. The final analysis extends the evidence from the previously reported stage III population to the overall stage II–III population, providing a more comprehensive assessment of the efficacy and safety of perioperative toripalimab plus chemotherapy.

This symposium will provide an overview of the published data of phase III trials on pre/perioperative therapy for NSCLC and track the evolution of NEOTORCH from its initial stage III EFS breakthrough through pathological and surgical outcomes to the final stage II–III analysis and discuss how the totality of evidence may inform **patient selection, resectability assessment, treatment sequencing and multidisciplinary decision-making** in clinical practice. Recommendations on the choice of pre/perioperative therapy will also be discussed.

SS 3 16:30 - 16:50 [GMT+8] Saturday, 21 November 2026 Function Room 1 (2/F)

Rethinking Immunotherapy Across the HCC Spectrum: A Surgical Perspective

Prof. Albert Chi Yan CHAN
Department of Surgery
School of Clinical Medicine
The University of Hong Kong
Hong Kong SAR, China

The management of hepatocellular carcinoma (HCC) has evolved substantially over the past decade, driven by advances in systemic therapies, locoregional interventions, and surgical techniques. Traditionally, treatment decisions have been guided by tumour stage and liver function, with surgery, transplantation, and locoregional therapies forming the cornerstone of management for selected patients. More recently, the emergence of immunotherapy has transformed the treatment landscape, expanding therapeutic possibilities and prompting renewed discussion on how different treatment modalities may be optimally integrated across the HCC continuum.

Durable clinical benefit observed with immunotherapy-based approaches in advanced HCC has generated increasing interest in the broader role of immunotherapy across the HCC treatment continuum. At the same time, growing evidence supporting the combination of systemic and locoregional therapies has highlighted new opportunities for multidisciplinary care. As treatment options continue to expand, close collaboration among surgeons, medical oncologists, interventional radiologists, hepatologists, and radiation oncologists is becoming increasingly important to optimize patient outcomes.

From a surgical perspective, these developments raise important questions regarding patient selection, treatment sequencing, and the integration of systemic and local therapies. Surgery remains a cornerstone of treatment for carefully selected patients with resectable disease, while advances in systemic and locoregional treatments may create opportunities for downstaging and conversion to potentially curative-intent interventions in selected patients. Multidisciplinary evaluation is therefore increasingly important to identify patients who may benefit from integrated treatment approaches and to determine the optimal timing and sequencing of therapies.

At the same time, emerging technologies and novel treatment approaches continue to expand the range of options available for HCC management, creating new opportunities for multidisciplinary collaboration and individualized care. As interest in the integration of systemic and local therapies grows, a coordinated multidisciplinary approach remains essential to optimize treatment selection and patient outcomes across the disease continuum.

This presentation will provide a surgeon's perspective on the evolving role of immunotherapy in HCC, discuss key considerations in multidisciplinary decision-making, and explore how advances in surgery, systemic therapy, and emerging treatment approaches are reshaping contemporary HCC management. Through case-based discussion and clinical experience, it will highlight future opportunities to optimize patient outcomes through integrated and individualized care.

SS 4 16:50 - 17:10 [GMT+8] Saturday, 21 November 2026 Function Room 1 (2/F)

Addressing Unmet Needs in HER2m NSCLC: From Evidence to Practice

Dr. Gordon Cheuk Ho TANG
Department of Clinical Oncology
Prince of Wales Hospital
Hong Kong SAR, China

Activating *HER2 (ERBB2)* mutations occur in approximately 2–4% of non-small cell lung cancers. HER2 exon 20 insertions, particularly A775_G776insYVMA, predominate. This subset is clinically aggressive, with a high incidence of brain metastases, and until recently lacked an approved first-line targeted option. Platinum–pemetrexed with or without immunotherapy remains widely used for unresectable, locally advanced or metastatic disease, but responses are modest and durability is limited. The therapeutic gap is both molecular and practical: incomplete *ERBB2* mutation testing, uncertain sequencing of antibody–drug conjugates (ADCs) versus tyrosine kinase inhibitors (TKIs), central nervous system (CNS) control, and toxicity trade-offs that matter in our clinics.

In this 20-minute talk, I will review first- and later-line evidence for the treatment of metastatic HER2m NSCLC, and share a local case of zongertinib use.

In previously treated disease, trastuzumab deruxtecan (T-DXd) established the ADC standard (DESTINY-Lung02): confirmed objective response rates (ORR) of around 50%, median progression-free survival (PFS) around 10 months, and clinically meaningful duration of response (DoR) of around 17 months. Drug-related pneumonitis, with incidence rate of around 15%, remains the most important side effect we watch out for. Selective oral HER2 TKIs have now entered the same space. In Beamion LUNG-1 cohort 1, zongertinib 120 mg daily produced an ORR of 71%, median PFS of 12.4 months and median DoR of 14.1 months after prior systemic therapy, with retained activity after a HER2 ADC (ORR ~44–48%). Grade ≥3 treatment-related events were uncommon; diarrhoea was mostly low grade and ILD was not observed. Sevabertinib is an additional approved TKI option after prior therapy. Both agents are relevant where oral therapy, CNS activity, or avoidance of ADC-related ILD is preferred.

The first-line landscape has shifted in 2026. Beamion LUNG-1 cohort 2 (treatment-naïve, n=74) reported an ORR of 76%, disease control 96%, median PFS 14.4 months and median DoR 15.2 months. Intracranial ORR is 47% in patients with active brain metastases (cohort 4). These data supported FDA's accelerated first-line approval of zongertinib. DESTINY-Lung04, presented at WCLC 2026, is the first randomized phase 3 comparison of a HER2-directed agent versus pembrolizumab plus platinum–pemetrexed: median PFS 14.3 versus 8.3 months (HR 0.63), ORR 70% versus 44.5%. Interim overall survival did not favour T-DXd. Sevabertinib has also received FDA's accelerated first-line approval in September 2026. Confirmatory phase 3 TKI trials (Beamion LUNG-2, SOHO-02) remain ongoing.

Given these new data, individual patient factors must be considered to select the most appropriate option for each patient. A short later-line case of zongertinib after chemotherapy and T-DXd will illustrate response kinetics, CNS behaviour and toxicity management in a real-world local patient.

SS 7 08:50 - 09:10 [GMT+8] Saturday, 21 November 2026 Function Room 2 (2/F)

Navigating First-line mTNBC: Positioning SG in Clinical Practice

Prof. Sung-Bae KIM
Department of Oncology
University of Ulsan College of Medicine
South Korea

Prof. Sung-Bae Kim will provide an overview of the evolving treatment landscape for metastatic triple-negative breast cancer (mTNBC) and discuss key considerations in first-line treatment decision-making. Drawing on current clinical evidence and his extensive clinical experience, this session will explore the role of sacituzumab govitecan (SG) in the treatment paradigm for mTNBC, with a focus on patient selection, treatment sequencing, and practical application in clinical practice.

SS 8 09:10 - 09:30 [GMT+8] Saturday, 21 November 2026 Function Room 2 (2/F)

'LIVE Imaging' MRI: Innovative Applications

Prof. Dong LIANG
Shenzhen Institutes of Advanced Technology
Chinese Academy of Sciences
Research Center for Medical Artificial Intelligence
Institute of Biomedical and Health Engineering
China

Since the inception of Magnetic Resonance Imaging (MRI), physiological motion—such as respiration, cardiac motion, and peristalsis—has presented one of the most persistent clinical and technical challenges. Traditional techniques attempt to "freeze" motion through gating, breath-holds, or ultra-fast static acquisitions, often compromising spatial resolution or signal-to-noise ratio.

This presentation explores the clinical applications and technological foundations of LIVE Imaging, enabled by United Imaging Healthcare's uMR Ultra and powered by the uAIFI.LIVE intelligent processing platform. By harmonizing ultra-high hardware performance, the uMR Ultra shifts MRI from static "photography" to real-time dynamic "videography".

The lecture will review clinical case examples demonstrating how LIVE Imaging provides high-definition, frame-by-frame diagnostic visualization across challenging anatomical regions. Finally, the lecture will address workflow transformations, patient-centric benefits, and the expanding role of AI-driven real-time MR in guiding diagnostic confidence.

SS 9 09:30 - 10:00 [GMT+8] Saturday, 21 November 2026 Function Room 2 (2/F)

The Evolving Landscape of Gadolinium-based Contrast Agents (GBCAs): Clinical Evidence and Future Directions

Prof. Yoshito TSUSHIMA
Department of Diagnostic Radiology and Nuclear Medicine
Gunma University Graduate School of Medicine
Japan

Gadolinium-based contrast agents (GBCAs) remain essential to magnetic resonance imaging, providing diagnostic information that influences patient management across clinical settings. However, their evolving role requires a broader assessment of value that integrates diagnostic efficacy, patient safety, environmental responsibility, and resource stewardship. This lecture reviews clinical evidence and emerging strategies for achieving these complementary goals.

Although GBCAs are generally well tolerated, immediate hypersensitivity reactions, including rare anaphylaxis, require appropriate risk assessment and preparedness. Prompt recognition and intramuscular adrenaline remain central to anaphylaxis management. Nephrogenic systemic fibrosis (NSF) has become exceptionally uncommon with appropriate agent selection and contemporary practice, particularly when agents associated with very low risk are used. Nevertheless, renal impairment warrants individualized consideration of clinical necessity, agent characteristics, and dosing. Gadolinium retention in the brain and other tissues has also prompted scrutiny. Retention differs between agents and is generally greater with linear than macrocyclic compounds; however, a causal relationship with adverse clinical outcomes in patients with normal renal function has not been established. Clear communication should distinguish demonstrated risks from unresolved concerns without discouraging clinically justified examinations.

Beyond individual patients, gadolinium discharged after contrast administration represents an emerging environmental challenge. Most extracellular GBCAs are excreted largely unchanged in urine, while conventional wastewater treatment incompletely removes these compounds. Anthropogenic gadolinium has consequently been detected in rivers and drinking water. Although the long-term ecological and human health implications remain uncertain, persistent environmental dissemination supports a precautionary approach. Practical measures include avoiding unnecessary contrast administration, minimizing unused residues, collecting residual contrast material, and evaluating urine collection and recovery technologies.

New macrocyclic agents, with high relaxivity offer opportunities to reduce administered gadolinium while preserving diagnostic performance. These developments emphasize that the relevant objective is reducing gadolinium exposure per diagnostically adequate examination, rather than simply reducing injection volume. Lower doses may decrease environmental loading, but improved clinical safety and reduced tissue retention require direct evidence rather than assumption.

Future progress will depend on integrating appropriate indications, optimized imaging protocols, evidence-based agent selection, and recovery pathways. Collaboration among clinicians, researchers, manufacturers, patients, and policymakers can help move contrast-enhanced MRI toward a more sustainable model. The overarching goal is to preserve diagnostic benefit while reducing avoidable exposure, waste, and environmental release throughout the contrast agent lifecycle.

SS 10 **12:30 - 13:00 [GMT+8]** **Saturday, 21 November 2026** **Function Room 2 (2/F)**

Optimizing Management of Endometrial Cancer with IO: When and How?

Dr. Amy Tien Yee CHANG
Department of Clinical Oncology
Hong Kong Sanatorium & Hospital
Hong Kong SAR, China

Immunotherapy combined with platinum-based chemotherapy has become a standard first-line treatment option for patients with advanced or recurrent endometrial cancer, particularly those with DNA mismatch repair-deficient (dMMR) or microsatellite instability-high (MSI-H) tumors. However, whether chemotherapy remains necessary in this highly immunogenic population has remained an important clinical question.

This lecture will focus on the emerging role of immunotherapy monotherapy in the first-line treatment of recurrent dMMR/MSI-H endometrial cancer, highlighting the phase III KEYNOTE-C93 study that compared pembrolizumab monotherapy with platinum-based chemotherapy. The KEYNOTE-C93 findings will be critically examined alongside existing evidence from frontline immunotherapy combination trials, with discussion of their potential impact on clinical practice and future treatment algorithms.

SS 11 13:00 - 13:30 [GMT+8] Saturday, 21 November 2026 Function Room 2 (2/F)

Evolving Treatment Paradigms in First-line EGFR-Mutated NSCLC: Advancing Outcomes through Combination Strategies, Treatment Innovation and Patient-centred Care

Dr. Samuel Ka Wai CHAN
Centre of Cancer Medicine, School of Clinical Medicine
The University of Hong Kong
Hong Kong SAR, China

The treatment landscape for first-line EGFR-mutated non-small cell lung cancer (NSCLC) continues to evolve, with emerging combination strategies offering opportunities to further optimise clinical outcomes. This lecture will review the evolving evidence supporting combination approaches in the first-line setting, with a focus on the interpretation of clinical data and their implications for treatment decision-making in practice. The session will also consider the practical translation of these advances into routine clinical practice. Practical considerations surrounding proactive management of treatment-related adverse events will be discussed, with an emphasis on supporting treatment adherence and optimising the overall patient experience.

SS 12 12:30 - 13:00 [GMT+8] Sunday, 22 November 2026 Function Room 1 (2/F)

Advancing Breast Care with Contrast-enhanced Mammography and CEM-guided Biopsy

Dr. Rameysh DANOVANI
Changi General Hospital
Singapore

Using iodinated intravenous contrast, contrast-enhanced mammography provides a new dimension in functional imaging of the breasts, highlighting underlying malignant lesions, a role that has been traditionally established by breast MRI. The lecture aims to review its clinical performance using clinical case examples guided by literature review. In addition, provision of contrast-enhanced mammography service would not be complete without the added biopsy capability for CEM-only lesions. Preparation for CEM-guided biopsy is therefore essential, avoiding the need for MRI-guided biopsies which are inherently more costly, time-consuming and may be limited by availability of expertise. The lecture aims to provide an overview of CEM-guided biopsy, covering its methodology by using clinical case examples.

Pretreatment DCE-MRI Spatial Ecological Signatures for Predicting Pathologic Complete Response in HER2-Positive Breast Cancer

Author(s) and Institution(s):
Tong Su[1,2,3†], Chengxin Kang[4†], Kaidi Long[5] Tian Xie[6,7], Wei Tang[1,2,3], Zhongxin Huang[1,2,3], Fajin Lv[5], Song Peng[1,2,3*]
[†] T.S. and C.K. contributed equally to this work.
[*] S.P. and Z.O. are co-senior authors.
[1]Department of Radiology, Chongqing Health Center for Women and Children, Chongqing, 401147, China
[2]Department of Radiology, Women and Children's Hospital of Chongqing Medical University, Chongqing, 401147, China
[3]NHC Key Laboratory of Birth Defects and Reproductive Health, Chongqing, 401147, China
[4]Radiation Physics Center, Chongqing University Cancer Hospital, Chongqing 400030, China
[5]Department of Radiology, The First Affiliated Hospital of Chongqing Medical University, Chongqing, China
[6]Department of Radiology, Daping Hospital, Army Medical University, PLA, Chongqing, China
[7]Chongqing Clinical Research Centre of Imaging and Nuclear Medicine, Chongqing, China

Objectives:
To develop and validate a pretreatment MRI-based multiscale spatial fusion model incorporating tumor ecological diversity signatures for predicting pathologic complete response (pCR) in HER2-positive breast cancer.

Materials and methods:
This retrospective multicenter study included women with HER2-positive breast cancer who underwent baseline DCE-MRI before neoadjuvant therapy between December 2019 and December 2025. Patients were divided into a training cohort, two external validation cohorts, and an independent radiogenomic validation cohort. Tumors were segmented on DCE-MRI using a pretrained 3D nnU-Net with radiologist refinement. Macroscopic radiomics, habitat clustering, and intratumoral and peritumoral tumor ecological diversity signatures were extracted and integrated into a multiscale spatial fusion model. Radiogenomic analyses using weighted gene co-expression network analysis and gene set variation analysis were performed in patients with matched pretreatment transcriptomic data.

Results:
The final cohort included 853 women, with 366 in the training cohort, 172 and 210 in two external validation cohorts, and 105 in the radiogenomic validation cohort. The spatial fusion model achieved AUCs of 0.87, 0.84, and 0.87 in the three validation cohorts, respectively, and outperformed clinicopathologic predictors. In multivariable modeling, multiscale imaging signatures were retained as independent predictors of pCR. Radiogenomic analysis linked pCR-favorable imaging signatures to targeted-therapy sensitivity pathways, including ErbB signaling, whereas non-pCR signatures mapped to DNA repair and immune exhaustion networks. Spatial habitat metrics also showed correlations with stemness-related pathways, including Notch and Hedgehog signaling.

Conclusion:
Pretreatment DCE-MRI spatial ecological signatures predicted pCR in HER2-positive breast cancer across multicenter cohorts and provided a noninvasive imaging window into treatment-response biology.

RAD Session A(2) **21 November 2026** **08:40-08:50 [GMT+8]** **Pao Yue Kong Auditorium, G/F**

Anatomy-Aware Deep Learning with Tumour and Lymph Node Station Maps for CT-Based Nodal Metastasis Prediction in Lung Cancer

Author(s) and Institution(s):
Zhebing Lin[1], Hanxiao Zhang[2], Pengchong Li[1], Xinghua Cheng[1]
[1]Department of Oncology, Shanghai Chest Hospital, Shanghai Jiao Tong University School of Medicine, Shanghai, China
[2]Institute of Medical Robotics, Shanghai Jiao Tong University, Shanghai, China

Objectives:
Accurate imaging assessment of nodal status remains challenging in lung cancer: conventional CT has limited diagnostic performance when based largely on nodal size and morphology, while FDG-PET/CT, despite its established role, is not definitive. We investigated whether anatomy-aware integration of the primary tumour and International Association for the Study of Lung Cancer (IASLC)-defined nodal stations could improve **CT-based deep-learning prediction of pathological nodal status (N0 vs N+)**.

Materials and methods:
Multiclass nodal segmentation used an anatomy-aware nnU-Net with airway, oesophageal, and azygos-vein priors as separate input channels. The model was trained on 102 fully annotated CT scans and evaluated in internal (n=120) and external (n=150) cohorts. Nodal and primary-tumour masks were then fed to a 3D ResNet trained on 200 National Lung Screening Trial (NLST) cases (100 N0, 50 N1, 50 N2). Four inputs were compared: CT alone, CT+nodal masks, CT+tumour masks, and CT+tumour+nodal masks. Independent NLST (n=100) and Shanghai Chest Hospital (SCH; n=100) cohorts were used for validation. The SCH cohort underwent curative-intent resection with systematic lymph-node dissection; pathological N status was the reference standard.

Results:
Anatomy-aware segmentation achieved Dice similarity coefficients (DSCs) of 0.6106±0.1328 internally and 0.5938±0.1586 externally, enabling automated 3D visualisation of the 14 IASLC-defined nodal stations. In internal validation, AUCs were 0.5869 for CT alone, 0.6588 for CT+nodal masks, 0.6238 for CT+tumour masks, and 0.7640 for CT+tumour+nodal masks (95% CI 0.6684–0.8596; sensitivity 82.22%; specificity 67.27%). In external validation, CT+tumour+nodal masks had the highest AUC (0.7014; 95% CI 0.5958–0.8071; sensitivity 73.33%; specificity 69.09%), compared with 0.6216 for CT+nodal masks and 0.6113 for CT+tumour masks.

Conclusion:
Explicit tumour and nodal-station anatomy yielded the highest discrimination in both validation cohorts, supporting **anatomically informed AI as complementary decision support for preoperative nodal assessment**. Station-specific 3D maps may also provide **an intuitive anatomical reference for preoperative planning.**

RAD Session A(3) 21 November 2026 08:50-09:00 [GMT+8] Pao Yue Kong Auditorium, G/F

Anatomy-Informed 3D Deep Learning for Preoperative CT Prediction of Visceral Pleural Invasion

Author(s) and Institution(s):
Pengchong Li[1], Zhonghe Liu[1], Fang Zhu[1], Zhebing Lin[1], Xinghua Cheng[1]
[1]Department of Oncology, Shanghai Chest Hospital, Shanghai Jiao Tong University School of Medicine, Shanghai, China

Objectives:
To assess whether explicit three-dimensional nodule and pleural-region information improves CT-based prediction of visceral pleural invasion (VPI) and physician interpretation.

Materials and methods:
This retrospective single-centre study included 823 patients with resected lung adenocarcinoma measuring 3 cm or smaller (675 VPI-negative, 148 VPI-positive); reference labels came from postoperative pathology with elastic staining in every case. Patients were chronologically divided into development (n=660; 2017-2021) and temporal test (n=163; 2022-2024) cohorts. Noncontrast CT patches and reviewed nodule and pleural-region masks were separate inputs to 3D ResNet-50. CT-only, anatomy-informed, mask-only and interface-augmented models were evaluated using five-fold out-of-fold development predictions and fixed temporal testing. An interim paired study assessed 11 physicians reading 60 test cases with and without model assistance.

Results:
In temporal testing, the CT+nodule+pleural-region model achieved an area under the receiver operating characteristic curve (AUC) of 0.897 (95% confidence interval [CI], 0.836-0.947), versus 0.812 (95% CI, 0.727-0.887) for CT alone. The paired AUC difference was 0.085 (95% CI, 0.007-0.165; Holm-adjusted P=0.267). Interface-model AUCs were 0.881-0.899, with no uniquely optimal width. At a development-derived threshold, the anatomy-informed model achieved 90.0% sensitivity and 66.4% specificity. In the interim reader analysis, assistance increased mean accuracy from 61.7% to 75.9% (difference, 14.2 percentage points; 95% CI, 9.2-19.6; P<0.001).

Conclusion:
Explicit nodule and pleural-region channels achieved higher temporal-test discrimination than CT alone, while AI assistance improved physician accuracy. These findings support anatomy-informed deep learning as a promising decision-support approach for preoperative VPI assessment.

RAD Session A(4) 21 November 2026 09:00-09:10 [GMT+8] Pao Yue Kong Auditorium, G/F

Interpretable Intrasplenic Attenuation Phenotypes and Spatial Relationship Modelling for Early Identification of High-Grade Splenic Injury on Non-Contrast CT

Author(s) and Institution(s):
Yaning Wang[1], Mingyang Li[1],Zheng Miao[1], Simin Yang[1], Han Xue[1], Huimao Zhang
[1]Department of Radiology, the First Hospital of Jilin University

Objectives:
To develop an interpretable non-contrast CT model for identifying high-grade splenic injury (AAST grades IV–V) and compare attenuation phenotypes with whole-spleen radiomics.

Materials and methods:
This study included 356 adults with splenic injury. The development cohort comprised 252 non-contrast CT examinations (117 high-grade and 135 low-grade), and an independent test cohort comprised 90 patients with paired non-contrast and contrast-enhanced CT (36 high-grade and 54 low-grade). A contrast-enhanced CT reference model was trained on 279 cases. Images and spleen masks were resampled to 1.5-mm isotropic voxels. Five modules were developed: whole-spleen radiomics (RadScore), intrasplenic high-attenuation phenotypes (HighTop), low-attenuation phenotypes (LowTop), perisplenic high-attenuation burden (PeriTop), and spatial relationships between high- and low-attenuation abnormalities (SpatialTop). Feature selection used univariable analysis, correlation filtering, cross-validated ElasticNet regression, and bootstrap stability assessment.

Results:
In the paired test cohort, HighTop was the best individual non-contrast CT module (AUC, 0.866; 95% CI, 0.783–0.949), outperforming RadScore (AUC, 0.731; 95% CI, 0.621–0.841), LowTop (AUC, 0.665), and PeriTop (AUC, 0.651). SpatialTop achieved an AUC of 0.822. RadScore combined with HighTop achieved the highest AUC of 0.867 (95% CI, 0.785–0.949), with 75.0% sensitivity and 85.2% specificity. HighTop combined with SpatialTop achieved a comparable AUC of 0.861 (95% CI, 0.777–0.945) and the highest sensitivity of 86.1%, with 79.6% specificity. Its performance was comparable to the best contrast-enhanced CT reference model (AUC, 0.830; 95% CI, 0.750–0.900). The complete multimodule model did not improve performance (AUC, 0.820).

Conclusion:
Interpretable intrasplenic high-attenuation phenotypes and their spatial relationships enabled effective identification of AAST grade IV–V splenic injury on non-contrast CT. This approach may support early risk stratification and prioritisation of contrast-enhanced CT, interventional radiology, or surgical assessment when enhanced imaging is delayed or unavailable.

Bridging the Implementation Gap: A Cross-Sectional Study of Radiologist and Clinician Perspectives on Artificial Intelligence (AI) in Radiology.

Author(s) and Institution(s):
Mok Alex[1], Kwok Hoi Ming[1], Li Kwok Yan[1], Lee Bo Yee[1], Lo Phoebe Hiu Wai[1], Mahboobani Neeraj[2], Cheng Lik Fai[1]
[1]Department of Diagnostic and Interventional Radiology, Princess Margaret Hospital, Hong Kong
[2]Department of Imaging and Interventional Radiology, The Chinese University of Hong Kong

Objectives:
To evaluate disparities in AI awareness, expectations, and adoption between radiologists and clinicians contributing to the implementation gap in Hong Kong radiological practice.

Materials and methods:
A cross-sectional survey of 71 professionals (84% response rate; 40 radiologists [R], 31 clinicians [C]) assessed perspectives across AI domains using categorical and non-parametric statistical analyses.

Results:
Both cohorts demonstrated high diagnostic AI awareness with the majority expecting fundamental practice impacts within 10 years. A literacy-practice mismatch emerged: despite high diagnostic AI experience (R:95.0% vs C:74.2%, $p<0.05$), formal training was critically low (3.2%), with clinicians rating curricula as more inadequate ($p<0.05$). Moreover, 90.1% advocated integrating AI literacy into medical training. While both cohorts prioritized workflow efficiencies (R:82.5% vs C:87.1%), awareness of non-interpretative applications (e.g., triage prioritization, acquisition acceleration) remained low, though radiologists reported higher image processing awareness (R:3.6/5 vs C:3.0/5, $p<0.05$). Both cohorts prioritized concerns regarding medico-legal liability (R:57.5% vs C:83.9%, $p<0.05$) and AI reliability (R:52.5% vs C:77.4%, $p<0.05$), yet with low black-box awareness (R:37.5% vs C:38.7%). Radiologists exhibited disclosure-dependent automation bias, with AI findings influencing reports progressively as recipient scope expanded from radiologists alone to clinicians and patients ($p<0.05$). Neither group trusted fully autonomous AI (R:0% vs C:3.2%). Radiologists favored strict human oversight and shared accountability (48.7%), while a subset of clinicians accepted minimal oversight (26.7%) and held radiologists primarily accountable for AI errors (35.5%).

Conclusion:
Bridging the implementation gap necessitates dynamic, role-specific AI training to address literacy-practice mismatch. Strategies should expand focus towards non-interpretative AI to enhance workflow efficiency. Establishing risk-based governance to harmonize human oversight, align interdisciplinary accountability, and mitigate automation bias is essential for safe AI adoption.

Quantitative Ultrafast DCE-MRI Pharmacokinetic Analysis of Breast Lesions referred for MRI-Guided Biopsy

Author(s) and Institution(s):
PL Lam[1], WP Cheung[1], LW Lo[1], WS Mak[1], KML Wong[1], PYE Fung[1]
[1]Department of Diagnostic and Interventional Radiology, Kwong Wah Hospital, Hong Kong SAR

Objectives:
To evaluate quantitative pharmacokinetic parameters derived from ultrafast dynamic contrast-enhanced magnetic resonance imaging (DCE-MRI) in differentiating benignity and malignancy for suspicious breast lesions referred for MRI-guided biopsy.

Materials and methods:
This was a retrospective study performed in an acute general hospital. Consecutive MRI-guided biopsies of suspicious breast lesions (BI-RADS 4 or 5) from June 2023 to May 2025 were analysed. Clinical information, procedural details, and pathological results were retrieved. Pre-procedural standard and ultrafast DCE MRI were reviewed. Ultrafast DCE MRI consisted of high-temporal-resolution (4.5-second intervals) T1-weighted images acquired during the first minute using 3T MRI scanner. Quantitative parameters, including early-phase volume transfer constant (K^{trans}) and initial area-under-curve (iAUC), were derived using Tofts pharmacokinetic modelling. Factors associated with benign or malignant biopsy results were evaluated using Fisher's exact test for categorical data and Mann-Whitney U test for non-parametric continuous data. Area-under-curve (AUC) values were obtained from receiver operating characteristics (ROC) curves.

Results:
Fifty MRI-guided breast biopsies were performed in 31 adult (≥18 years) female patients (median age, 61.0 years; IQR, 13.0 years). All biopsies obtained diagnostic pathological results, with no procedure-related complications. Thirty-five lesions (70.0%) were benign and fifteen (30.0%) were malignant. Malignant lesions demonstrated higher median K^{trans} than benign lesions (0.246 min^{-1} vs 0.081 min^{-1}; p=0.014) and higher median iAUC (0.083 vs 0.034; p<0.001). AUC for differentiating malignant from benign lesions were 0.77 (95% CI, 0.63–0.92) for K^{trans} and 0.86 (95% CI, 0.75–0.97) for iAUC.

Conclusion:
Ultrafast DCE-MRI-derived quantitative pharmacokinetics, K^{trans} and iAUC, significantly differentiated benign from malignant lesions referred for MRI-guided biopsy. These parameters show promise as adjuncts for lesion characterisation and merit validation in larger prospective cohorts.

Winning by Saving: Utility of Contrast-enhanced Mammography as a One-stop Problem-solving Tool

Author(s) and Institution(s):
Stefanie W.Y. Yip[1], H. L. Chau[1], Winnie C.W. Chu[1], Esther H.Y. Hung[1]
[1]Department of Imaging and Interventional Radiology, The Chinese University of Hong Kong, Prince of Wales Hospital, 30-32 Ngan Shing Street, Shatin, Hong Kong

Objectives:
Contrast-Enhanced Mammography (CEM) is increasingly recognized as a less costly, more accessible, and similarly accurate alternative to MRI in the diagnosis and workup of breast cancer. Of particular value is its ready availability such that CEM can immediately be performed in the same visit once conventional modalities are found to be inconclusive. Yet it is not widely performed in Hong Kong. This study evaluates the efficacy of implementing CEM into the routine diagnostic workup algorithm for suspicious or indeterminate breast lesions.

Materials and methods:
50 consecutive breast lesions (16 malignant or atypia, 34 benign) that required further evaluation by CEM due to suspicious or inconclusive findings after undergoing mammography, tomosynthesis, and ultrasound during 2022-2026 were analyzed. The BIRADS category assigned by the radiologist at the time of examination was recorded. Each case was prospectively followed up on the final diagnosis, which was based on histopathology (50%, n=25) or clinical/imaging follow-up (50%, n=25). Mean clinical follow-up duration was 345 days.

Results:
CEM correctly identified 15 of the 16 malignant/atypia lesions, with a single false negative case of DCIS presenting as non-enhancing grouped pleomorphic microcalcifications in background severe fibrocystic change and multiple fibroadenomas. For diagnosis of malignancy in suspicious cases, CEM showed a sensitivity of 94% and a negative predictive value of 96%. No US correlate was identifiable in 53% of cases.

Overall CEM showed a 96% accuracy in differentiating benign from malignant lesions, with 36% of benign lesions exhibiting enhancement, but none with contrast washout.

CEM was completed < 12min post-injection for all cases, which is less than half the time of MRI. Similarly, CEM-guided biopsy took half the time of MR-guided biopsy and had 100% technical success in our cases.

Conclusion:
CEM is an effective one-stop problem-solving tool for evaluating occult, suspicious, and/or indeterminate lesions, while CEM-guided biopsy can readily be performed on occult lesions. The addition of CEM into the workup protocol is able to save time and costs, thus directly expediting patient management.

Implementation of Ultrasound-Guided Therapeutic Vacuum-Assisted Biopsy for High-Risk (B3) and Discordant Benign Breast Lesions: Effectiveness and Long-Term Outcomes

Author(s) and Institution(s):
PBK Tang[1], EPY Fung[2], WP Cheung[2], LW Lo[2], LKM Wong[2], WS Mak[2], DHY Cho[2]
[1]Department of Diagnostic and Interventional Radiology, Queen Elizabeth Hospital, Hong Kong
[2]Department of Diagnostic and Interventional Radiology, Kwong Wah Hospital, Hong Kong

Objectives:
To evaluate the effectiveness and long-term outcomes of ultrasound-guided therapeutic vacuum-assisted biopsy (VAB) with the intent of complete lesion removal at a tertiary referral centre.

Materials and methods:
A retrospective analysis of consecutive patients undergoing therapeutic VAB between April 2022 and March 2024 was performed. Clinico-radiological, procedural and histopathological data were evaluated. Procedural success was defined as immediate complete lesion removal. Long-term outcome was determined by absence of residual or recurrent lesion on surveillance ultrasound, after excluding lesions with incomplete removal, patients lost to follow-up or with concurrent ipsilateral same-quadrant malignancies.

Results:
The final cohort comprised 128 lesions: 82 (64.1%) core-needle biopsy-proven high-risk B3 or B5a lesions, 34 (26.6%) radiologically-pathologically discordant benign lesions (BI-RADS category ≥ 4a), and 12 (9.4%) suspicious lesions managed via upfront therapeutic VAB.

Immediate complete lesion removal was achieved in 93.0% (119/128) of cases, significantly predicted by smaller lesion size (mean 8.2 mm vs 14.9 mm; $p = 0.021$). No major procedural complications were reported. The overall malignant upgrade rate was 10.2% (13/128), with larger lesions (>10 mm) demonstrating a significantly higher upgrade risk (17.9% vs. 8.0%; $p = 0.042$).

All patients were followed up clinically. For the completely removed, non-malignant lesions undergoing ultrasound surveillance, 93.0% (93/100) demonstrated no recurrence at a mean follow-up of 20.3 months.

Conclusion:
Therapeutic VAB is a highly effective, tissue-sparing intervention for high-risk and discordant benign breast lesions. With the intent of complete lesion removal, it maintains exceptionally low complication and local recurrence rates while reliably identifying occult malignancies.

Placental Vascularization-Flow Index on 3D Power Doppler Ultrasound as an Early Predictor for Gestational Diabetes Mellitus: A Prospective Cohort Study

Author(s) and Institution(s):
Dr Bhumika Dhamija[1], Dr Upasana Sinha[2], Dr Mukta Agarwal[3], Dr Sangam Kumari[4]
[1]Department of Diagnostic and Interventional Radiology, All India Institute of Medical Sciences, Rishikesh, India, and Department of Radiodiagnosis, All India Institute of Medical Sciences, Patna, India
[2]Department of Radiodiagnosis, All India Institute of Medical Sciences, Patna, India
[3,4]Department of Obstetrics and Gynaecology, All India Institute of Medical Sciences, Patna, India

Objectives:
To assess whether mid-pregnancy three-dimensional power Doppler placental volume and vascular indices differ between women who develop GDM and those who remain normoglycemic, and the predictive performance of placental Doppler indices for subsequent GDM.

Materials and methods:
This prospective cohort study included 204 pregnant normoglycemic women at the time of midtrimester ultrasound at 19-24 weeks of gestation. 3D placental Doppler examination with assessment of placental volume, vascularisation index (VI), flow index (FI) and vascularisation-flow index (VFI) were recorded. Maternal demographic and clinical parameters were noted. The participants were followed up and classified depending on the development of Gestational Diabetes during pregnancy. Placental parameters were compared between groups, and ROC curve analysis was performed to assess their predictive ability for subsequent GDM.

Results:
Among the 204 women, 18 (8.8%) developed Gestational Diabetes Mellitus, whereas 186 remained normoglycemic. Women with GDM were older and had a higher weight and BMI. There were no significant differences between groups in placental volume, VI, and FI. Additionally, VFI was significantly lower in women who developed GDM as compared to those who remained normoglycemic (0.34 ± 0.20 vs. 1.13 ± 0.73; $p < 0.001$, Cohen's $d = 1.12$). ROC analysis demonstrated **excellent predictive performance of placental VFI for subsequent GDM, with an AUC of 0.912 (95% CI: 0.848–0.975; p < 0.001).**

Conclusion:
Placental VFI provides excellent predictive value for subsequent GDM, demonstrating its potential as a novel non-invasive early marker for identifying pregnancies at increased risk of GDM before clinically overt disease manifestation. VFI in the second-trimester ultrasound may represent an additional opportunity for early risk stratification and targeted surveillance.

Percutaneous cryoablation of lung tumours – experience at a tertiary centre

Author(s) and Institution(s):
RK Mak[1], JCY Lee[1], BCK Chow[1], KWH Chiu[1], KK Li[2], HW Mok[2], J Chik[3], J Chow[3], WL Poon[1]
[1]Department of Diagnostic and Interventional Radiology, Queen Elizabeth Hospital
[2]Department of Cardiothoracic Surgery, Queen Elizabeth Hospital
[3]Department of Clinical Oncology, Queen Elizabeth Hospital

Objectives:
CT-guided percutaneous cryoablation is a minimally invasive option for selected lung tumours, particularly in medically inoperable patients or those with limited pulmonary metastatic disease. Contemporary evidence suggests favorable local control and acceptable safety, with pneumothorax remaining the most common complication.

Materials and methods:
We conducted a prospective single-centre cohort study of patients undergoing CT-guided lung cryoablation between October 2025 and July 2026. Eligible patients had biopsy-proven primary or recurrent NSCLC, or selected pulmonary metastases, and were reviewed in a multidisciplinary setting before treatment. The primary endpoint was technical success, defined as complete macroscopic ice-ball coverage of the index lesion on intraprocedural CT. Secondary endpoints included 30-day complications, short-term local control, and post-procedural hospital stay.

Results:
Twenty-three patients underwent cryoablation of 25 lesions. Median age was 67.5 years, and most lesions were NSCLC (76.0%). Median lesion size was 1.7 cm. A median of three cryoprobes was used per lesion, and triple freeze-thaw cycles were applied in all cases. Technical success was achieved in 100% of lesions. Two SIR grade C complications occurred, both pneumothoraces requiring chest drainage. Post-procedural hospital stay ranged from 1 to 8 days. On early follow-up imaging, all evaluable lesions showed expected post-ablation evolution without residual enhancing tumour, and no local recurrences were identified at 6 months among evaluable lesions.

Conclusion:
CT-guided percutaneous lung cryoablation achieved excellent technical success with acceptable safety and encouraging early local control in this tertiary-centre cohort. Longer follow-up is needed to determine durability of tumour control.

Initial Single-Centre Experience with the CARESTO Heal Carotid Stent in Symptomatic Carotid Stenosis: 30-Day Safety and Short-term CTA Findings

Author(s) and Institution(s):
Cherry Cheuk Yan Chan, Chun Kit Richard Chan, Danny Hing Yan Cho
Department of Diagnostic & Interventional Radiology, Kwong Wah Hospital

Objectives:
To describe our initial single-centre experience with elective carotid artery stenting (CAS) using the CARESTO heal stent, focusing on procedural/technical success, 30-day clinical safety outcomes, and short-term computed tomography angiography (CTA) findings including patency and categorical in-stent restenosis (ISR).

Materials and methods:
Retrospective single-centre observational study of consecutive elective CAS procedures using the CARESTO heal stent between April 2025 and May 2026. After predefined exclusions, 27 carotid stenoses in 22 patients (including five same-session bilateral procedures) were analysed. Stenosis severity was determined intra-procedurally on digital subtraction angiography (DSA) using NASCET criteria. Technical success was defined as successful delivery/deployment with a satisfactory final angiographic result (residual stenosis <30% with preserved antegrade flow) without implantation of an additional non-study carotid stent. Clinical outcomes included stroke/transient ischemic attack (TIA) and all-cause mortality within 30 days. Short-term CTA follow-up was assessed for stent patency and categorical ISR.

Results:
Median age was 69.5 years (range 51–83); 77% were male. Treated lesions were predominantly symptomatic (26/27, 96%). On DSA, 19/27 (70%) stenoses were severe (≥70%) and 8/27 (30%) were moderate (50–69%). Technical success was achieved in 27/27 lesions (100%), with residual stenosis <30% in all lesions and no requirement for additional non-study carotid stents. No in-hospital deaths or new neurological deficits were documented. At 30 days, stroke/TIA and mortality were 0/22. CTA follow-up at approximately 3 months was available in 24/27 (89%) treated lesions: all were patent. ISR was <50% in 6/24 (25%), 50–69% in 3/24 (12.5%), and no restenosis in 15/24 (62.5%); no ≥70% ISR or occlusions were observed among imaged stents.

Conclusion:
In this initial single-centre elective experience, CAS with the CARESTO heal stent was associated with high technical success, no 30-day stroke/TIA or mortality, and favourable short-term CTA findings with preserved patency and no severe ISR. Larger studies with longer follow-up are warranted.

Development and Validation of a CT-Based Diagnostic Flowchart for Neuromuscular Diseases

Author(s) and Institution(s):
Takuto Oki[1,2], Hajime Yokota[3], Hiroki Miyazaki[2], Hiroki Mukai[2], Takashi Uno[3], Kei Yamada[1]
[1]Department of Radiology, Kyoto Prefectural University of Medicine
[2]Department of Radiology, Chiba University hospital
[3]Diagnostic Radiology and Radiation Oncology, Graduate School of Medicine, Chiba University

Objectives:
To develop and internally validate a CT-based diagnostic flowchart for differentiating neuromuscular diseases using whole-body muscle CT findings

Materials and methods:
This study included patients who underwent non-contrast whole-body CT for muscle assessment at Chiba University Hospital between October 2019 and April 2025. Patients with confirmed neuromuscular diseases were analyzed. Two radiologists evaluated predefined CT findings, including muscle and tongue fatty infiltration, symmetry of involvement, severe quadriceps involvement, distal lower-limb-predominant involvement, tibialis anterior involvement, and gynecomastia, without reference to the final diagnosis. Cases were chronologically divided into derivation (70%) and internal validation (30%) cohorts. The branching order was determined using two-step look-ahead diagnostic yield. Diagnostic performance was compared with the initial clinical diagnosis using McNemar's test.

Results:
Among 499 candidate CT examinations, 260 patients were included (165 men, 95 women; median age, 65 years; interquartile range, 54–73 years). Diagnostic accuracy was 77.5% (141/182) in the derivation cohort and 80.8% (63/78) in the internal validation cohort. The accuracy of the initial clinical diagnosis was 80.4% (209/260), increasing to 93.5% (243/260) when combined with the flowchart ($p < 0.001$). The flowchart added correct diagnostic candidates in 34 cases, with a number needed to diagnose of 7.6.

Conclusion:
A CT-based diagnostic flowchart using muscle fatty infiltration patterns and extramuscular findings showed good internal validation performance and significantly improved diagnostic accuracy when combined with the initial clinical diagnosis. Whole-body CT may complement the differential diagnosis of neuromuscular diseases.

Toxic but Good: A 10-year Review of the Efficacy and Tolerability of Botox Injection for Muscle Spasticity in a Single Tertiary Centre

Author(s) and Institution(s):
T.H. Wong[1] , Stefanie W.Y. Yip[1], Cina S.L. Tong[1], Esther H.Y. Hung[1], Griffith James Francis[1]
[1]Department of Imaging and Interventional Radiology, The Chinese University of Hong Kong, Prince of Wales Hospital, 30-32 Ngan Shing Street, Shatin, Hong Kong

Objectives:
Botulinum type A neurotoxin injection (Botox®) has been FDA-approved for treatment of focal spasticity in cerebral palsy and stroke patients. More recently, there is increasing interest in expanding applications of Botox for off-label use in various other spastic conditions, yet the influence of patient demographics, dosing, and disease etiology remain complex. This study investigates the efficacy and safety of Botox for muscle spasticity across different ages, dose regimens, and disease indications.

Materials and methods:
163 consecutive cases of ultrasound (US)-guided Botox injection performed over 10 years in a single tertiary centre during 2016 - 2026 were retrospectively reviewed. All cases were clinically referred for relief of focal muscle spasticity or dystonia. Cases were stratified according to patient age group, disease indication, high vs low dose, upper vs lower limb, and treatment endpoint. Treatment outcome and adverse effects were assessed by longitudinal clinical follow-up, with mean follow-up of 73 months.

Results:
Overall, 76% of injections yielded clinical improvement. 96% cases did not have adverse events, which were all minor. Mean number of injections was 2.4 per patient, with repeated injections performed more for those who had clinical improvement ($p = 0.049$).
Using multivariate regression to control for confounders, clinical outcomes did not significantly differ by gender (OR=0.41, p=0.14), age group (OR=1.26, p=0.71), or injection site (OR=1.34, p=0.64). Compared to cerebral palsy, efficacy was similar for CVA (OR=0.75, p=0.68) and musculoskeletal conditions (OR=0.61, p=0.67). There was higher tendency towards improvement for spasticity from non-CVA insults ($OR = 3.08$, $p = 0.09$) comprising Parkinson's disease, traumatic cord/brain injury, and when given at high dose ($OR = 2.67$, $p = 0.16$).

Conclusion:
US-guided Botox injection is a highly tolerable safe procedure enabling improvement in spasticity in over three-quarters of patients. Clinical efficacy is consistent across demographics, dosages, and aetiologies, reinforcing its broad versatility, with tendency towards greater efficacy when given for non-CVA post-insult spasticity and at high dose.

Diagnostic performance of 3D T2-weighted sequence for local staging of endometrial carcinoma on magnetic resonance imaging (MRI)

Author(s) and Institution(s):
OL Chan[1], SCT Ling[2], WLW Yip[3], KW Lee[1], L Xiao[1], DLY Chow[1], WH Chong[1], KY Kwok[1]
[1]Department of Radiology and Nuclear Medicine, Tuen Mun Hospital, Hong Kong
[2]Department of Obstetrics and Gynaecology, Tuen Mun Hospital, Hong Kong
[3]Department of Clinical Oncology, Tuen Mun Hospital, Hong Kong

Objectives:
To evaluate the diagnostic performance of 3D T2W sequence for local staging of endometrial carcinoma on MRI.

Materials and methods:
Patients with a histological diagnosis of endometrial carcinoma were prospectively recruited from the Department of O&G from 1 Jun 2022 to 31 Jul 2023. Pre-operative staging MRI was performed on a 1.5T scanner. In addition to the standard MRI protocol, a 3D T2W sequence was acquired (axial plane; FOV 360x400x400mm; voxel size 1x1x2mm).
MRI findings were independently evaluated based on 3D T2W sequence alone and 2D T2W sequences alone by two readers. Discrepancies were resolved by consensus with a third reader. Histopathological results were used as the reference standard.

Results:
During the study period, 44 patients (median age 59 years; range 34-88) underwent MRI followed by hysterectomy, with a median interval of 33 days (range 7 – 287) between MRI and surgery. Eight patients were excluded due to the time interval exceeding 60 days, leaving 36 cases for the final analysis.
3D T2W sequences demonstrated a sensitivity, specificity and diagnostic accuracy of 92.3%, 91.3%, 92.7% for deep myometrial invasion and 66.7%, 96.7%, 92.7% for and cervical stromal invasion.
2D T2W sequences demonstrated a sensitivity, specificity and diagnostic accuracy of 92.3%, 87.0%, 88.9% for deep myometrial invasion and 66.7%, 93.3%, 88.9% for and cervical stromal invasion.
For 3D T2W sequences, interobserver agreement was moderate for deep myometrial invasion ($k = 0.6$, $p = 0.001$) and substantial for cervical stromal invasion ($k = 0.78$, $p < 0.001$). The interobserver agreement for 2D T2W sequences was perfect for both deep myometrial invasion and cervical stromal invasion ($k = 1.0$, $p = 0.002$).

Conclusion:
3D T2W sequence demonstrated good diagnostic performance for local staging in endometrial carcinoma. When compared with 2D T2W sequences, it showed higher specificity and diagnostic accuracy. However, the 3D T2W sequence is limited by longer acquisition time and lower signal-to-noise ratio. Besides, the lower interobserver agreement observed with 3D T2W sequences suggests a potential learning curve for this less routinely used sequence.

RAD Session B(6) 21 November 2026 17:20-17:30 [GMT+8] Function Room 2, 2/F

Diagnostic Performance of Multiparametric MRI in the Characterization of Parotid Masses: A 2-Year Retrospective Local Center Experience

Author(s) and Institution(s):
Dr. WONG Ching Tung[1], Dr. CHU Ka Man[2], Dr. KO Wei Sum Koel[2], Dr. FUNG King Him[2]
[1]Department of Diagnostic & Interventional Radiology, Kwong Wah Hospital
[2]Department of Diagnostic & Interventional Radiology, Queen Elizabeth Hospital

Objectives:
Parotid masses range from benign entities, such as pleomorphic adenoma and Warthin tumour, to malignant neoplasms. Conventional MRI remains the mainstay of preoperative assessment, but accuracy is limited by overlapping features between benign subtypes and malignant lesions. Fine-needle aspiration cytology is not always conclusive, owing to sampling difficulty and histological heterogeneity. Multiparametric MRI (mpMRI), integrating diffusion-weighted imaging with apparent diffusion coefficient (ADC) and dynamic contrast-enhanced (DCE) perfusion curve analysis, may resolve these uncertainties. This study evaluates diagnostic performance of mpMRI in characterizing parotid masses.

Materials and methods:
Of 105 patients who underwent mpMRI at our centre between July 2024 and June 2026, 42 with pathological confirmation (FNA, core biopsy, or surgical excision) were included, comprising 12 malignant tumors, 12 pleomorphic adenomas, 15 Warthin tumors, and 3 other benign masses. Conventional morphological and multiparametric features were recorded for each lesion. One-vs-rest diagnostic performance was calculated per feature, categorical variables were tested by permutation chi-square and ADC by Mann-Whitney U, with LASSO regression for multivariate selection.

Results:
DCE curve type showed the strongest single-feature performance: Type A identified pleomorphic adenoma (91.7% sensitivity, 96.7% specificity), Type B identified Warthin tumour (100%/100%), and Type C identified malignant tumors (91.7%/93.3%), outperforming the best conventional feature for malignancy (ill-defined margin: 41.7%/100%). ADC $\geq$1.44 identified pleomorphic adenoma (100%/93.3%) and ADC $\leq$0.98 identified Warthin tumour (100%/74.1%). No ADC cut-off reliably distinguished malignant from other lesions (p=0.63).

Conclusion:
Multiparametric MRI shows high diagnostic performance in characterizing parotid masses. DCE curve type and ADC cut-offs reliably distinguished pleomorphic adenoma, Warthin tumour, and malignant tumors. A diagnostic flow chart integrating these multiparametric and conventional features is proposed to guide radiologists in lesion characterization.

ONC Session CO(1) 21 November 2026 08:30-08:40 [GMT+8] Function Room 1, 2/F

Real-World Outcomes of Pre-emptive UGT1A1-Guided Irinotecan Dose Reduction in Asian Intermediate Metabolisers

Author(s) and Institution(s):
Ying Chan[1], Brian Chan[1], Natalie Sean Man Wong[1], Ka Chun Leung[1], Barry Bar Wai Wo[1], Chin Hong Yick[1], Ann Shing Lee[1]
[1]Department of Clinical Oncology, Tuen Mun Hospital, Hong Kong SAR, China

Objectives:
Irinotecan is a widely-utilized chemotherapeutic agent. UDP-glucuronosyltransferase 1A1 (UGT1A1) polymorphisms impact Irinotecan toxicity, often necessitating hospitalization and posing lethal risks in poor metabolizers (PM, 5-15% patients) and intermediate metabolizers (IM, 35-45% of patients). Real-world data and Asian-specific guidelines on genotype-guided Irinotecan dosing remain limited.

Materials and methods:
This retrospective cohort study included Chinese patients with advanced gastrointestinal cancers who underwent preemptive UGT1A1 genotyping between January 2024 and July 2025. IM and PM patients received a protocol-specified minimum 20% and 30% dose reduction respectively, with subsequent dose escalation in tolerated individuals. The primary endpoint was grade ≥3 toxicity in the first three cycles of treatment.Secondary endpoints included relative dose (RD), further Irinotecan dose modification, objective response rate (ORR), disease control rate (DCR), time to treatment failure (TTF), and progression free survival (PFS).

Results:
61 patients were included (normal metabolisers(NM)=26,IM=32,PM=3). IM patients had significantly lower average RD (IM 58.8% vs. NM 77.3%,$p<0.001$). Rates of grade ≥3 toxicities were comparable: neutropenia (IM 15.6% vs. NM 23.1%,$p=0.517$), diarrhea (IM 3.1% vs. NM 3.8%,$p=1.000$), and febrile neutropenia (0% in both groups). Rates of further dose reduction were numerically lower in IM (IM 15.6% vs. NM 23.1%, $p=0.517$).

Despite lower dose intensity, early efficacy and survival outcomes showed no significant differences: ORR (IM 24.1% vs NM 23.8%,$p=1.000$), DCR (IM 72.4% vs NM 71.4%,$p=0.939$), TTF (IM 9.9 vs NM 7.4 months,$p=0.599$), PFS (IM 11.1 vs NM 10.2 months,$p=0.599$). Similar non-significant differences were observed in the colorectal cancer-only subgroup (n=46).

Conclusion:
In this first Hong Kong cohort study, preemptive UGT1A1 testing with genotype-guided dose reduction in IM was feasible, demostrating acceptable toxicity and maintained early efficacy. These findings may suggest wider implementation, though larger studies are needed for confirmation.

BLCA-RAPID: External Validation of Multimodal Recurrence Prediction in Non-Muscle-Invasive Bladder Cancer

Author(s) and Institution(s):
Xing Liu[1]
[1]Department of Urology, Xuzhou Central Hospital, School of Medicine, Southeast University, Xuzhou, Jiangsu, China

Objectives:
Recurrence after transurethral resection remains common in non-muscle-invasive bladder cancer (NMIBC). We developed and externally validated BLCA-RAPID, integrating clinical variables, computed tomography (CT) radiomics, and foundation-model histopathology for recurrence risk stratification.

Materials and methods:
This retrospective two-center study included 230 patients with NMIBC: 168 patients with 60 recurrence events in the development cohort and 62 patients with 30 events in the external cohort. Radiomics features were extracted from tumors and concentric peritumoral regions on preoperative non-contrast CT. The primary CT representation combined intratumoral features with cumulative peritumoral information extending to 3 mm. H&E whole-slide images were encoded with UNI2 and pooled using attention-based multiple-instance learning. Cross-fitted clinical, CT, and pathology scores were combined by ridge-penalized Cox regression. Models were developed using repeated nested cross-validation and applied unchanged to the external cohort.

Results:
In external validation, C-indices were 0.751 for the clinical model, 0.601 for CT, 0.649 for histopathology, and 0.757 (95% CI 0.675-0.840) for BLCA-RAPID. The 12-, 24-, and 36-month AUCs of BLCA-RAPID were 0.806, 0.815, and 0.892; the 24-month Brier score was 0.227. Compared with CT plus histopathology, BLCA-RAPID improved the external 24-month AUC by 0.130 (P=0.034) and reduced the Brier score by 0.010 (P=0.004). Incremental analyses indicated that most added prognostic information arose from whole-slide histopathology, whereas CT provided limited complementary information.

Conclusion:
BLCA-RAPID provided externally validated recurrence risk stratification by combining routinely available clinical, CT, and histopathological data. Prospective evaluation is needed before clinical implementation.

ONC Session CO(3) 21 November 2026 08:50-09:00 [GMT+8] Function Room 1, 2/F

Dosimetric Drivers of Cardiopulmonary NTCP and Risk Equalization: Implications for Proton Therapy Patient Selection in Breast Cancer

Author(s) and Institution(s):
CHANG Tien Yee, Amy[1], TANG, Rosalyn Yuen Yim[2], YANG, Bin[3], WONG, Hiu Yi[4]
[1]Comprehensive Oncology Centre, Hong Kong Sanatorium & Hospital, Hong Kong SAR
[2]LKS Faculty of Medicine, The University of Hong Kong, Hong Kong SAR
[3]Medical Physics Department, Hong Kong Sanatorium & Hospital, Hong Kong SAR
[4]Research Department, Hong Kong Sanatorium & Hospital, Hong Kong

Objectives:
Normal Tissue Complication Probability (NTCP) models translate 3D dose-volume histogram (DVH) metrics into cardiopulmonary toxicity risk to guide patient selection for proton therapy. In photon plans, NTCP is highly driven by patient-specific anatomy, creating variable risk distribution. We evaluated modality-specific dosimeric drivers of heart and lung NTCP to identify which patients benefit most from proton therapy.

Materials and methods:
Within a propensity-matched cohort of 164 breast cancer patients who received proton (n=82) or photon (n=82) therapy, stratified by nodal involvement and laterality, heart and lung DVH metrics were extracted. Patient-level NTCP variance was quantified by IQR and range. In the primary 15-fraction cohort (n=129), Spearman's correlation between DVH metrics and NTCP was calculated.

Results:
Proton greatly reduced NTCP variance compared to photon plans, with the greatest effect in nodal patients. Photon NTCP heavily relied on patient spatial geometry, leading to wide ranges and high-risk outliers.

Low-dose exposure to the lung (V4 Gy) most strongly correlated with lung NTCP for proton, while high-dose exposure (V16 Gy) most strongly correlated for photon. High-dose exposure is more sensitive to patient-specific anatomy, explaining NTCP variability of photon.

LAD and RCA D_{mean} correlated significantly with heart NTCP, with stronger correlation strength in right-sided patients in both photon (left ρ=0.56, right ρ=0.78) and proton (left ρ=0.57, right ρ=0.83) plans. RCA D_{mean} also correlated significantly with lung NTCP in proton but not photon plans, with stronger correlation strength in right-sided (ρ=0.72) than left-sided (ρ=0.58) patients.

Conclusion:
While photon NTCP is vulnerable to unfavorable spatial geometry, proton therapy compresses patient-level variance and shifts dosimetric drivers from high-dose to low-dose metrics, neutralizing anatomical variability. Patients with higher anatomical risk, particularly nodal patients, could be prioritized for proton therapy. RCA D_{mean} is a potential indicator of compound cardiopulmonary risk in proton plans, particularly for right-sided patients, when selecting patients for proton therapy.

The Reaudit of Monitoring of QT Interval in Cancer Patients using Methadone in the Department of Clinical Oncology, Tuen Mun Hospital

Author(s) and Institution(s):
HC Wong[1], WY Tin[1]
[1]Department of Clinical Oncology, Tuen Mun Hospital

Objectives:
To review the compliance of performing baseline ECG, follow-up ECG (FU ECG), ECG on admission (admission ECG), in TMH oncology patients being prescribed methadone due to cancer pain, according to our departmental guideline updated in 2024 and against international standards.

Materials and methods:
During the audit period from 1st May 2025 to 30th June 2025, 23 patients were started methadone by our unit. There were 25 episodes of admission of patients on methadone (for audit, 1 was excluded due to clinical admission for chemotherapy, 1 was excluded due to clinical admission for end-of-life care), 46 out-patient attendances while 30 require FU ECG on index attendance. Baseline ECG, FU ECG and admission ECG records were retrieved from electronic patient records and hard copies from outpatient and in-patient care episodes. Two standards were used: primary standard was the new Methadone ECG monitoring protocol updated in July 2024 in TMH Oncology, secondary standard was the Methadone Safety Guidelines by American Pain Society 2014.

Results:
Compliance of performing baseline ECG according to our new department protocol and secondary standard were 100%. Median baseline QTc was 424ms. Two patients had baseline prolonged QTc (range 457-460ms).
Compliance of FU ECG according to primary standard was suboptimal (63.3%). Incidence of QTc prolongation in FU ECG was 26.3%, 1 in 5 patients with prolonged QTc had baseline prolonged QTc.
According to secondary standard, FU ECG compliances were 100% for patients with baseline prolonged QTc, or with risk factors of QTc prolongation. Both were improved compared to that in 2022 (20% and 15.2% respectively).
Compliance of admission ECG was 78.3%. One patient was found to have prolonged QTc of 496ms, and methadone was stopped in view of the QTc prolongation. No patients were found to have clinically significant QTc prolongation on FU ECG or admission ECG. No torsades de pointes was identified.

Conclusion:
Baseline ECG compliance was 100%. The compliance of FU ECG was suboptimal according to primary standard, but was 100% according to secondary standard, which was improved compared to 2022. Remedial actions will be introduced.

ONC Session CO(5) 21 November 2026 09:10-09:20 [GMT+8] Function Room 1, 2/F

Real-World Outcomes of First-Line Taxane-Based Chemotherapy with Trastuzumab and Pertuzumab in Advanced HER2-Positive Breast Cancer: A Single-Centre Retrospective Cohort Study

Author(s) and Institution(s):
King Nam Edmond Wong[1], Sheona Sze Nga Leung[1], Kwan Ho Leung[1], Jessica Wing Yu Lai[1]
[1]Department of Oncology, Princess Margaret Hospital, Hong Kong SAR

Objectives:
Taxane, trastuzumab and pertuzumab (THP) has been the standard first-line therapy for advanced HER2-positive breast cancer for a decade. Newer regimens and intensified maintenance strategies have since emerged, but carry additional toxicity and cost. We describe real-world outcomes of first-line THP in an Asian cohort and identify factors associated with poorer outcome.

Materials and methods:
We retrospectively reviewed 128 patients receiving first-line THP over six years. Progression-free survival (PFS) and overall survival (OS) were measured from the first dose, estimated by Kaplan–Meier and compared by log-rank test. Prognostic factors were assessed by Cox regression, with variables significant on univariate analysis entered into a multivariable model.

Results:
After a median follow-up of 37.7 months, median PFS was 24.5 months (95% CI 18.2–30.9) and 3-year OS was 74.7%. Maintenance endocrine therapy was given to 95.7% of ER-positive patients. No significant PFS difference was observed by mode of presentation, ER status or HER2 expression. Median PFS differed by pattern of visceral involvement (log-rank P=0.004): 36.7 months with neither hepatic nor pulmonary metastasis versus 12.4 months with both. On multivariable analysis adjusting for performance status, number of metastatic sites and baseline CA 15-3, concurrent hepatic and pulmonary involvement remained associated with PFS (HR 2.84, P=0.029). ECOG 2 or above also predicted shorter PFS (HR 2.28, P=0.032), but number of metastatic sites and CA 15-3 did not. Brain metastasis, modelled as time-dependent, was associated with increased mortality (HR 5.71, P<0.001). Grade 3–4 neutropenia and febrile neutropenia were significantly more frequent without primary G-CSF prophylaxis.

Conclusion:
First-line THP achieved outcomes comparable with registration trials. Concurrent hepatic and pulmonary metastasis predicted shorter PFS independent of metastatic burden, identifying a high-risk subgroup that might benefit from intensified strategies. Baseline and interval brain imaging, to detect intracranial disease before symptoms develop, and routine primary G-CSF prophylaxis should be considered.

CDK4/6 Inhibitors In HR Positive, HER2 Negative Advanced Breast Cancer In Malaysia: Real World Outcome And Cost Analysis

Author(s) and Institution(s):
Yeong Uen Yea[1], Adlinda Alip[1]
[1]Department of Clinical Oncology, Faculty of Medicine, Universiti Malaya, Kuala Lumpur, Malaysia

Objectives:
Hormonal therapy with CDK4/6 inhibitors are standard of care for HR positive HER2 negative metastatic breast cancer. This study aimed to evaluate clinical outcomes, toxicity profiles and costs of CDK4/6i in an academic hospital in Malaysia.

Materials and methods:
All patients who started on CDK4/6i from June 2016 to December 2022 in Universiti Malaya Medical Centre were included except those in adjuvant setting. We examined patient characteristics, variations in prescribing practices, efficacy, adverse events and cost analysis

Results:
84 patients were included, with mean age of 57 years. Palbociclib (63.1%) was the most prescribed CDK4/6i, followed by ribociclib (22.6%) and abemaciclib (14.3%). Median PFS in first line treatment was 19.1 months (n=41, 48.8%), second line 13.2 months (n=18, 21.4%), and 8.5 months for third line and beyond (n=25, 29.8%), while median OS was 37.9 months, 22.7 months, and 25.9 months respectively. There were no significant differences in PFS or OS between CDK4/6i. 57% of patients had neutropenia while 28.6% required dose reduction due to adverse events. Mean cost per PFS month was lowest for palbociclib (RM 2410, 95% CI: RM 98-8956), followed by ribociclib (RM 4125, 95% CI: RM 325-12925), and abemaciclib (RM 4045, 95% CI: RM 47-21146). Probabilistic sensitivity analysis indicated palbociclib had the highest probability of being cost-efficient at RM 6000/PFS month (91.3%), compared to ribociclib (79.4%) and abemaciclib (77.9%). Wide confidence intervals for ribociclib and abemaciclib reflected interpatient cost variability.

Conclusion:
This real-world clinical data of CDK4/6i treatment in an academic hospital in Malaysia demonstrated comparable efficacy and adverse events with phase 3 trials, particularly as first line treatment. Palbociclib had the most favourable cost-efficient profile with the lowest cost per PFS month and the highest probability of being cost-efficient compared to ribociclib and abemaciclib.

StratiFIVE: a pilot PROMISE V2-based score for early response assessment on post-therapy imaging after 177Lu-PSMA-617 radioligand therapy

Author(s) and Institution(s):
MHY Cheung, PL Tsoi, WT Ngai
Department of Nuclear Medicine, Pamela Youde Nethersole Eastern Hospital, Hong Kong SAR

Objectives:
Tumour-volume assessment on post-therapy imaging after ^{177}Lu-PSMA-617 radioligand therapy (RLT) requires calibrated reconstruction and lesion segmentation, limiting routine use. We evaluated StratiFIVE, an exploratory visual score derived from interval changes in adapted PROMISE V2 PSMA-expression score in up to five lesions on post-therapy planar imaging with SPECT/CT correlation, for association with biochemical response.

Materials and methods:
This retrospective single-centre pilot included 14 consecutive men with mCRPC treated with ^{177}Lu-PSMA-617. Post-therapy images after cycles 1 and 2 were reviewed in consensus by two nuclear medicine physicians blinded to PSA outcomes. Up to five lesions with greatest directional change in adapted PSMA-expression score (score range 0 to 3; per lesion change –3 to +3) were selected, preferentially including positively over negatively scored lesions. These lesion-level changes were summed to a StratiFIVE score (theoretical range –15 to +15). Co-primary endpoints were PSA50 and PSA90 at any time during RLT. Associations were assessed using Mann-Whitney U and Fisher exact tests; apparent discriminatory performance was assessed with ROC analysis.

Results:
StratiFIVE scores ranged from –11 to +5. PSA50 and PSA90 were achieved by 9/14 (64.3%) and 6/14 (42.9%) patients, respectively. Scores were lower in PSA50 responders than non-responders (median –10 vs +2; p=0.004); apparent AUC 0.978 (95% CI 0.926–1.00). Exploratory ROC-derived cutoff of ≤ 0 yielded 100% sensitivity and 80% specificity for identifying PSA50 responders. PSA90 responders also had lower scores (median –10 vs +0.5; p=0.009); apparent AUC 0.927 (95% CI 0.779–1.00). Exploratory ROC-derived cutoff of ≤–1 yielded 100% sensitivity and 87.5% specificity for identifying PSA90 responders.

Conclusion:
In this small exploratory cohort, a simple visually derived lesion-panel score from post-therapy imaging after the first two cycles of ^{177}Lu-PSMA-617 was associated with PSA50 and PSA90 response. StratiFIVE may offer a pragmatic early assessment framework where quantitative SPECT is unavailable; prospective multicentre validation is required before clinical adoption.

NM Session NM(2) 21 November 2026 15:30-15:40 [GMT+8] Function Room 2, 2/F

Impact of Different T-score Reference Databases on Osteoporosis Diagnosis and Treatment Eligibility in Hong Kong Chinese Adults: A Single-Centre Study

Author(s) and Institution(s):
J Chu[1], TK Chow[1]
[1]Department of Radiology & Nuclear Medicine, Tuen Mun Hospital, Hong Kong

Objectives:
To compare prevalence of osteoporosis/osteopenia and treatment eligibility (per Osteoporosis Society of Hong Kong (OSHK) guideline) in treatment-naïve Chinese postmenopausal women and men >50 years referred for DXA, when bone mineral density (BMD) is analysed using Caucasian female (T_{US}), Chinese (T_{CN}) and Hong Kong (T_{HK}) reference databases.

Materials and methods:
Consecutive patients undergoing DXA at Tuen Mun Hospital during 1 May to 31 Oct 2023, who were Chinese, treatment-naïve, postmenopausal or male >50 years old were included. BMD (L1–L4, total hip, femoral neck) was measured on a Hologic Horizon scanner and re-analysed with T_{US} (NHANES III/Hologic), T_{CN} (Liao et al.) and T_{HK} (Lynn et al.) databases. Prior low-energy hip/vertebral fractures, ethnic-specific FRAX were recorded. Treatment eligibility followed OSHK guideline (prior fracture, T-score ≤–2.5, or T-score between -1 and -2.5 and elevated FRAX). Overall proportions of patients classified as treatment-eligible across the three databases are compared by Cochran's Q test, followed by pairwise McNemar's test if needed.

Results:
234 patients (201 women, 33 men) were analysed. Osteoporosis prevalence was higher with T_{US} (women 60.2%, men 60.6%) than T_{CN}/T_{HK} (women 42.3–45.8%, men 42.4%). In women, treatment eligibility following OSHK guideline using different reference databases was 80.6% (T_{US}), 77.1% (T_{CN}) and 77.6% (T_{HK}) (Cochran's Q test, p=0.005). Pairwise McNemar's tests confirmed significantly higher treatment eligibility with T_{US} versus T_{CN} or T_{HK}, while there is no statistical difference between T_{CN} and T_{HK}.

Conclusion:
The Caucasian female database labelled ~15–20 % more patients osteoporotic compared with Chinese or Hong Kong databases. The Caucasian female database also classified significantly more patients as treatment-eligible than Chinese or Hong Kong databases. Database choice affects both diagnosis and treatment decisions, and standardization of reference databases in Hong Kong is needed.

NM Session NM(3) 21 November 2026 15:40-15:50 [GMT+8] Function Room 2, 2/F

Efficacy of Personalised Dosimetry in Selective Internal Radiation Therapy for Palliative Treatment of Locally Advanced Hepatocellular Carcinoma

Author(s) and Institution(s):
HM Cheung[1], WI Li[1], JHY Lau[1], WC Wong[1], KS Ng[1], KK Ng[1], BT Kung[1]
[1]Nuclear Medicine Unit, Queen Elizabeth Hospital, Hong Kong SAR

Objectives:
Patients with locally advanced hepatocellular carcinoma (HCC) are challenging to manage and selective internal radiation therapy (SIRT) is often considered. This study aims to the evaluate efficacy of personalised dosimetry in palliative SIRT and establish tumour dose threshold for patients with locally advanced HCC.

Materials and methods:
This single-centre retrospective study included patients have unresectable locally advanced HCC received SIRT from December 2015 to January 2026. Tumour dose was calculated with DOSIsoft system on the pre-treatment ^{99m}Tc-MAA SPECT/CT. Treatment response of tumour was evaluated on the post-treatment CT according to RECIST version 1.1 criteria. Receiver Operating Characteristic (ROC) curve analysis to evaluate the predictive value of tumour dose. Patient were stratified into high- and low-dose groups for further analysis.

Results:
Forty-one patients were included; 23 (56.1%) achieved partial response, while 18 (43.9%) were non-responders. ROC curve analysis identified a tumour dose threshold of 160.2 Gy (AUC 0.81, $p = 0.007$), with 78.2% sensitivity, 77.8% specificity, 81.8% PPV and 73.7% NPV. Treatment-naïve tumours were more common among responders (87.0% vs. 61.1%, OR = 0.07, $p = 0.002$). Responders showed favourable reduction in alpha-fetoprotein (AFP) (mean AFP %change –61.9% vs +69.0%, $p = 0.003$). High-dose patients demonstrated greater AFP reduction (–36.2% vs. +43.3%, $p = 0.04$) and longer AFP time-to-progression (5.3 vs. 3.0 months, $p = 0.03$). The median time to AFP nadir among high-dose responders was 105 days (95% CI: 77.1–143.3). More responders were able to proceed to subsequent therapies (89.5% vs. 38.9%, OR = 13.4, $p = 0.002$). Median overall survival was longer in the high-dose group (32.4 vs. 14.1 months).

Conclusion:
Personalised dosimetry-guided SIRT is an effective palliative treatment for unresectable locally advanced HCC, particularly in treatment-naïve patients. A tumour dose threshold of 160.2 Gy is a useful predictor of treatment response and clinical outcomes.

From full-time full-dose to half-time half-dose in FDG PET imaging with digital PET scanner: A phantom study with Bayesian penalized likelihood image reconstruction

Author(s) and Institution(s):
Martin Law[1,2], Keith Kwan[2], Judy Yu[1], Vivian Ma[1]
[1]Department of Radiology and Nuclear Medicine, Tuen Mun Hospital, HKSAR, China.
[2]Department of Clinical Oncology, Tuen Mun Hospital, HKSAR, China.

Objectives:
Increase in sensitivity in digital PET imaging offers a combination of radioactivity and scan time. This study evaluated the consistency in measurable image quality of standardized uptake values (SUV) as obtained from PET images of a phantom undergone different acquisition time and FDG concentration to ensure comparable lesion detectability in half-time half-dose acquisition protocol with full-time full-dose protocol for higher patient throughput and for less patient dose from FDG.

Materials and methods:
A 3D phantom with 6 spheres of different diameters was scanned with a digital PET scanner for different acquisition time and FDG concentration. Image reconstruction was performed with the Bayesian penalized likelihood iterative reconstruction method with β=350, with which SUV were evaluated and compared between the two acquisition protocols to compare lesion detectability between the two protocols. Reconstructed image quality of the spheres was evaluated with the use of contrast recovery, partial volume recovery coefficient and background variability to ensure image quality between the two protocols.

Results:
Reconstructed images of all six spheres were qualitatively visible as acquired with the two protocols. Inter-comparison of SUV among different concentrations for each sphere is of no statistically significant difference as a function of acquisition time (p>0.05), demonstrating comparable lesion detectability between the two protocols. Reconstructed phantom images will be presented to achieve these results. Parameters of image quality contrast recovery and partial volume recovery coefficient of each sphere were of no statistically significant different among different sphere concentrations along different acquisition times (p>0.05), reflecting the consistent reconstructed image quality for different FDG concentrations and acquisition times.

Conclusion:
SUV, image quality of contrast recovery and recovery coefficient and background variability are good measurable parameters to show that half-time half-dose acquisition can be achieved because of the gain in radioactivity detection with the use of digital PET scanners.

Poster 01

Introduction of Dual-Energy CT in the Characterisation of Abdominal Mass: Enhancing Lesion Conspicuity in Liver and Kidney with Dual-Energy CT

Author(s) and Institution(s):
Maggie HY Leung, Amy HC Wong, Matthew KK Law, Shiobhon Y Luk
Department of Radiology, Pamela Youde Nethersole Eastern Hospital

Objectives:
To illustrate our experience in a local centre using dual-energy CT (DECT) for characterising renal and liver masses, highlighting the diagnostic advantages of low-keV virtual monoenergetic images (VMI) and iodine overlay maps.

Materials and methods:
DECT cases were acquired in a local centre during July–August 2026. Consecutive patients referred for dedicated CT liver or CT kidney for suspected masses underwent DECT; obese patients and those with suboptimal breath-hold were excluded. A total of 18 patients were included. Examinations were performed on a Siemens SOMATOM X.cite TwinBeam DECT scanner using a gold/tin split-filter.
Liver protocol: single-energy CT (SECT) unenhanced, DECT arterial, DECT portal venous, SECT delayed.
Renal protocol: SECT unenhanced, DECT corticomedullary, DECT nephrographic, SECT delayed.
Post-processing generated VMI, virtual non-contrast images (VNC), iodine overlay maps, and mixed-energy images approximating 120 kVp single-energy CT. SECT unenhanced images allowed direct VNC comparison during early DECT implementation.

Images were analysed by two board-certified radiologists to compare lesion conspicuity.

Results:
Of 18 patients, 13 had hepatic or renal masses, all of which demonstrated improved conspicuity on DECT. Subtle lesions inconspicuous on mixed-energy images (approximating 120 kVp single-energy CT) were more conspicuous on VMI and iodine overlay maps. Two cases were selected for illustration.
Case 1: A 71-year-old male with elevated AFP – follow-up DECT improved conspicuity of an infiltrative hepatocellular carcinoma (HCC) in segment 7 on 40 keV VMI, with neoplastic thrombus in the right hepatic vein confirmed on iodine overlay maps.
Case 2: An 87-year-old male with urinary frequency – 40 keV VMI improved conspicuity of a hypoenhancing renal mass; iodine overlay maps demonstrated uptake within the lesion versus negligible uptake in an adjacent cyst, supporting renal cell carcinoma (RCC).

Conclusion:
DECT improves lesion conspicuity and characterisation in hepatic and renal masses, enhancing diagnostic confidence.

Poster 02

When Inflammation Masks Infiltration: A Pictorial Review of Pancreatic Cancer Presenting as Acute Pancreatitis

Author(s) and Institution(s):
KW Chan, KS Tam, KH Wong
Department of Radiology, North District Hospital, Hong Kong SAR

Objectives:
Pancreatic cancer may present as acute pancreatitis, potentially related to pancreatic duct obstruction and shared risk factors. Recognition of an underlying malignancy can be challenging, as CT findings such as peripancreatic fat stranding, lymphadenopathy and parenchymal necrosis may be seen in both conditions. This pictorial review illustrates atypical CT features of acute pancreatitis that should raise suspicion for an underlying malignancy.

Materials and methods:
Retrospective review of imaging studies of patients with biopsy-proven pancreatic adenocarcinoma presented as acute pancreatitis between 1/6/2024 and 31/5/2026.

Results:
Three representative cases were selected for illustration. All patients initially presented with clinical features of acute pancreatitis.

Case 1
Stage 4 pancreatic adenocarcinoma with nodal, peritoneal and bone metastases, initially misdiagnosed on CT as necrotizing pancreatitis.
Atypical features illustrated:
- Splenic vein encasement with collaterals formation
- Dilatation of main pancreatic duct
- Extensive lymphadenopathy disproportionate to the degree of pancreatic inflammation
- Multifocal sclerotic osseous lesions

Case 2
Recurrent pancreatitis with a pseudocyst and focal hypoenhancing area, misinterpreted as focal necrosis on serial CTs. EUS subsequently confirmed adenocarcinoma.
Atypical features illustrated:
- Progressive enlargement of the focal hypoenhancing area despite improvement in the pancreatic inflammatory changes and regression of the pseudocyst

Case 3
Pancreatic head adenocarcinoma presented as bulky pancreatic head with double-duct sign on initial

CT, without a discrete hypoenhancing mass.
Atypical features illustrated:
- Presence of double-duct sign, even in the absence of a clearly delineated pancreatic mass

Conclusion:
Pancreatic cancer may be obscured by the inflammatory changes of acute pancreatitis. Recognizing atypical imaging features should prompt further investigation for an underlying malignancy.

Poster 03

Tackle the Meckel's: Rare complications of Meckel's diverticulum

Author(s) and Institution(s):
KS Tam, KW Chan, TY Yuen, KH Wong
Department of Radiology, North District Hospital, Hong Kong SAR

Objectives:
To demonstrate features of less common complications of Meckel's diverticulum of adult patients with CT and angiography, apart from typical diverticulitis and perforation.

Materials and methods:
Retrospective review of images of patients who presented with complications of pathologically proven Meckel's diverticulum in the past 12 years from 2015 to 2026.

Results:
Three representative cases were selected for illustration.

Case 1
Femoral Richter's hernia of Meckel's diverticulum complicated with strangulation
67 years old female presented with sudden onset irreducible painful right groin mass.
Contrast CT: right femoral hernia with narrow neck externally compressing Meckel's diverticulum with distended distal part with edematous wall, reduced mucosal enhancement. Small amount of fluid in hernia sac without gas. No bowel dilatation.

Case 2
Internal hernia of Meckel's diverticulum twisting mesentery, causing small bowel obstruction
85 years old male presented with diffuse abdominal distension and pain.
Contrast CT: close loop small bowel obstruction with abrupt transition zone inseparable from Meckel's diverticulum. Intraoperatively found Meckel's diverticulum adherent to base of small bowel mesentery causing twisting.

Case 3
Active bleeding from base of non-distended Meckel's diverticulum not well discerned in contrast CT
52 years old male with hemorrhoid presented with PRB, anemia, shock. No accountable cause from

OGD and colonoscopy.
Contrast CT: Distal ileum intraluminal active contrast extravasation with suspected angiodysplasia.
DSA: Persistent vitelline artery suggestive of underlying Meckel's diverticulum. No active contrast extravasation or andiodysplasia. Embolization was performed due to unstable hemodynamics, followed by partial small bowel resection.
Careful retrospective CT review: subtle non-distended Meckel's divericultum without CT evidence of inflammation or intraluminal blood product.

Conclusion:
Remember Meckel's diverticulum as one of the differential diagnoses even in adult population and rare complications can also arise. Angiographic diagnosis is possible with typical finding of persistent vitelline artery.

Poster 04

Hit and run by hidden culprits: Foreign bodies in gastrointestinal tract

Author(s) and Institution(s):
KS Tam, CSJ Wong, TY Yuen, KH Wong
Department of Radiology, North District Hospital, Hong Kong SAR

Objectives:
By demonstrating a few interesting cases, to increase awareness for trying to detect foreign bodies in gastrointestinal tract for unexplained perforation or abscess.

Materials and methods:
Retrospective review of images revealing foreign bodies in gastrointestinal tract from 2022 to 2026.

Results:
There are more than expected foreign bodies detected in gastrointestinal tract by cross sectional imaging. These could be incidental findings or detected in symptomatic or complicated cases. In some patients, only the complications are detected while the foreign bodies themselves could be missed due to small size or unexpected migration distant from the relatively more eye-catching perforation or abscess.
All of the following patients presented with abdominal pain:
1)
USG & CT: Suspected concealed perforation of gastric antrum by a 3cm bone within an abscess extending to within liver segment 4b. Patient discharged against medical advice to private hospital and was lost to follow up.
2)
CT: 4cm thin hyperdense object close to but outside gastric antrum is inseparable from segment 4a/4b liver abscess. It is later proven to be fish bone.

3)
CT: Perforated small bowel. A 3cm bone within hepatic flexure lumen could be the cause but could not be found during operation possibly due to fecal loaded large bowel.
4)
CT: Retroperitoneal gas and fluid inseparable from 3rd & 4th segments of duodenum. A 2.5cm thin hyperdense object in ileum could be the cause but operation was not performed due to multiple co-morbidities.
5)
CT: Large pelvic tumor deposit. No dilated bowel. Edge of film showed lower esophagus perforation with pneumomediastinum. No pneumothorax or empyema. A 2.5cm irregular hyperdense object in small bowel. Patient refused operation due to metastatic disease with palliative intent.
6)
CT: Perforated distal ileum by a 5cm hyperdense object extending outside lumen, later proven to be a toothpick. Suspected D3 concealed perforation inseparable from left psoas abscess could also be caused by the same toothpick which later migrated distally.

Conclusion:
Foreign bodies in gastrointestinal tract are more common than expected and could be the hidden culprit for unexplained perforation or abscess.

Poster 06

Virtual Large Language Model Clinical Decision Support Improves Imaging Appropriateness and Guideline-Concordant Management of Incidental Pulmonary Nodules: A Proof-of-Concept Study

Author(s) and Institution(s):
HM Kwok[1], Lewey CH Cheung[1], MC Chan[2], WT Kong[3], John TK Wong[3], Amy PM Chung[3], LF Cheng[1]
[1]Department of Diagnostic and Interventional Radiology, Princess Margaret Hospital
[2]Department of Medicine and Geriatrics, Princess Margaret Hospital
[3]Artificial Intelligence System Team, Information Technology and Health Informatics Division, Hospital Authority

Objectives:
Incidental pulmonary nodules are detected in up to 50% of thoracic CTs, yet guideline adherence remains suboptimal. We evaluated an AI decision support tool that automates data extraction from radiology reports and electronic patient records for Fleischner 2017 risk stratification.

Materials and methods:
Fifty patients (21 male; mean age 66.5±12.2 years) with pulmonary nodules were randomly selected from 674 consecutive cases during 2025 at a regional hospital. Nodule types comprised 35 solid, 6 ground-glass, 2 subsolid, 3 mixed, and 4 non-target findings. An internally hosted open-source large

language model (LLM), using the virtual LLM inference framework, extracted nodule characteristics and clinical risk factors, then determined Fleischner applicability and supported follow-up recommendation. A radiologist, blinded to AI output, adjudicated ground truth. Primary outcomes were AI-expert agreement (Cohen's Kappa) and improvement in guideline concordance (McNemar's test).

Results:
Of 50 cases, 41 met Fleischner criteria and 9 were excluded (4 malignancy, 1 DCIS, 4 benign findings). Agreement was almost perfect for applicability (κ=0.93, 95%CI 0.79–1.00) and follow-up determination (κ=0.89, 95%CI 0.75–1.00). The single inclusion-exclusion disagreement involved DCIS classified by AI as non-malignant. Two follow-up disagreements involved rising tumor markers under investigation and prior post-inflammatory change. Baseline guideline concordance was 31.7% versus 97.6% with AI assistance (p=0.003). The AI correctly reclassified 27 of 28 baseline non-concordant cases (NNT=2). Of 12 cases with >2-year stability, AI identified 9; 3 failures occurred because the algorithm safety design restricting stability comparison to Hospital Authority studies. Limitations included single-reader ground truth, small sample size, single-center retrospective design, and absence of human-AI interaction assessment.

Conclusion:
AI-assisted decision support improved guideline-concordant management, with near-perfect agreement with expert adjudication. Disagreements occurred in clinically nuanced scenarios, underscoring the essential role of human oversight. These support further validation study.

Poster 07

From Chatbot to Clinical Workflow: A Framework for AI in Radiology Practice

Author(s) and Institution(s):
Kui Chiu YIP, Chung Wai WONG, Elaine Wing Shan FOK
Department of Radiology and Organ Imaging, United Christian Hospital

Objectives:
This poster aims to (1) introduce radiologists to current healthcare AI models via a practical categorization framework; (2) demonstrate actionable ways to integrate AI into daily workflows; (3) address key challenges surrounding hallucination, ethics, data privacy and legal issues.

Materials and methods:
We evaluated current medical AI models using a categorization framework that analyzed access models (open vs. closed-source, free vs. paid), architecture (general-purpose vs. special-purpose), and retrieval mechanisms (self-data Retrieval-Augmented Generation vs. preset search). This framework was applied across four core radiology workflows: examination prep, worklist triage, multidisciplinary team (MDT) literature synthesis, and clinical quality audits.

Results:
The analysis demonstrated that different AI models can be implemented into all aspects of radiology workflow, spanning from knowledge acquisition and clinical audit data analysis to vetting scans and appointment bookings. However, clinical implementation faces critical challenges, including AI hallucination risks, patient data privacy concerns, local regulatory barriers (e.g., regional tool unavailability), and legal requirements.

Conclusion:
AI represents a transformative shift in radiology and clinical practice. Radiologists should adopt these tools early to enhance practice while carefully navigating ethical and legal boundaries.

Poster 08

Fully Automated Pretreatment DCE-MRI Deep Learning for Three-Year Recurrence Risk Stratification in Breast Cancer

Author(s) and Institution(s):
Tong Su[1,2,3†], Kaidi Long[4†], Rui Wang[7], Wei Tang[1,2,3], Zhongxin Huang[1,2,3], Fajin Lv[4], Song Peng[1,2,3*]
† T.S. and K.L. contributed equally to this work.
* S.P. and Z.O. are co-senior authors.
[1]Department of Radiology, Chongqing Health Center for Women and Children, Chongqing, 401147, China
[2]Department of Radiology, Women and Children's Hospital of Chongqing Medical University, Chongqing, 401147, China
[3]NHC Key Laboratory of Birth Defects and Reproductive Health, Chongqing, 401147, China
[4]Department of Radiology, The First Affiliated Hospital of Chongqing Medical University, Chongqing, China
[7]Department of Radiology, People's Hospital of Chongqing Hechuan, Chongqing, 401520, China

Objectives:
To develop and externally evaluate a fully automated pretreatment dynamic contrast-enhanced MRI (DCE-MRI) deep learning pipeline for predicting 3-year recurrence in patients with primary invasive breast cancer.

Materials and methods:
This retrospective multicenter study included women with stage I–III invasive breast cancer who underwent pretreatment breast MRI and curative-intent surgery from January 2018 to December 2022. Automated tumor segmentation was performed using a pretrained 3D nnU-Net. Tumor-centered three-dimensional regions of interest were used to train six candidate imaging models across three architectures and two synthetic augmentation settings. The selected imaging score was integrated with clinicopathologic predictors using logistic regression. Model performance was assessed by discrimination, calibration, decision curve analysis, risk stratification, and reclassification.

Results:
Among 1726 screened patients, 1144 were included: 712 in the development cohort, 344 in external validation cohort 1, and 88 in external validation cohort 2. Recurrence within 3 years occurred in 321 patients. Swin-M1 showed the highest and most consistent external validation performance among six imaging models, with AUCs of 0.869 and 0.878 in the two external validation cohorts. In the pooled external validation cohort, the clinical plus Swin-M1 model achieved an AUC of 0.881, compared with 0.666 for the clinical model and 0.871 for the image-only model. The combined model also had a lower Brier score than the clinical model (0.114 vs 0.187), correctly reclassified 203 of 432 patients, and yielded a total net reclassification improvement of 0.652.

Conclusion:
A fully automated pretreatment DCE-MRI deep learning score improved 3-year recurrence prediction and risk stratification beyond clinicopathologic variables in multicenter external evaluation.

Poster 09

Artificial Intelligence Computer-Aided Diagnosis (AI-CAD) Performance in Mammographic Calcification-Only Lesions: Alignment with BI-RADS Risk Stratification, Histology, and Diagnostic Pitfalls

Author(s) and Institution(s):
Wu Lap Yin[1], Ellen Lok-man YU[2], Chau Chi Man[3], Fung Wai Yuk[3], Leng Yong Mei[3], Stephanie Cheri Woo[3], Christine Tang[3], Chan En Hao[3], Wong Ka Wai3, Wong Ting[3]
[1]Department of Radiology, Princess Margaret Hospital, Hong Kong SAR
[2]Community Health Care, Kowloon West Cluster, Hospital Authority, Hong Kong SAR
[3]Department of Radiology, Princess Margaret Hospital, Hong Kong SAR

Objectives:
Suspicious calcifications may be the sole imaging finding of breast cancer, posing diagnostic challenges when subtle. This study assessed the diagnostic performance of AI-CAD for biopsy-proven calcification-only lesions, correlating AI positive predictive values with BI-RADS descriptors and risk categories, and abnormality score with histology.

Materials and methods:
In this single-center retrospective study, 190 biopsy-proven calcification-only lesions (155 benign, 35 malignant: 19 DCIS, 16 invasive) in 175 women (median age 53.5 years) between January 2022 and July 2024 were analyzed. Pre-biopsy mammograms interpreted by breast radiologists were processed with a commercial AI-CAD (Lunit INSIGHT MMG). AI-CAD performance (scores ≥10 positive) was correlated with breast density, calcification morphology, distribution, BI-RADS category, and histology. Statistical comparisons and trend analyses were performed.

Results:
Radiologist PPV was 18.4% (95% CI: 13.6–24.5%). AI-CAD achieved a higher PPV of 26.4% (95% CI: 19.5–35.4%), particularly in non-dense breasts (50.0%, vs dense breasts 25.0%). AI-positive lesions consistently showed higher malignancy rates than AI-negative lesions across all BI-RADS descriptors and categories. PPV increased with BI-RADS category: 4A 15.4%; 4B 47.1%; 4C 75.0% ($p<0.001$). Median AI scores rose across pathology: benign 10.5; high-risk 28; DCIS 45; invasive 65.5 ($p < 0.001$).
Typical benign (round/punctate) morphology had a lower PPV than other morphologies (6.7% vs 63.4%, $p<0.0001$). PPVs for regional, grouped and linear/segmental distributions were 11.1%, 24.3% and 43.8% respectively.
Four cancers (11.4%; 3 DCIS, 1 invasive) were missed by AI-CAD; all scored 0 and occurred in dense breasts with grouped distribution. Three of them were amorphous <1cm span.

Conclusion:
AI-CAD PPVs align with BI-RADS risk stratification, and abnormality scores correlate with pathological severity, outperforming radiologist PPV. Nonetheless, vigilance is required, as false negatives occur, especially for small grouped amorphous calcifications in dense breasts, mirroring human diagnostic pitfalls.

Poster 10

Mind the AI Gap: Evaluation of Discrepancies Between Greulich-Pyle and Tanner-Whitehouse 3 Standards in Automated Bone Age Artificial Intelligence Reporting in a Local Hospital in Hong Kong

Author(s) and Institution(s):
CW Choi, LH Li, HM Mok, WS Fok
Department of Radiology and Oran Imaging, United Christian Hospital, Hong Kong SAR

Objectives:
Automated artificial intelligence (AI) software (BoneXpert 3.2.2) is currently adopted across public hospitals in Hong Kong to streamline paediatric bone age reporting. While AI eliminates inter-observer variability, clinicians may encounter discrepancies between the software's Greulich-Pyle (GP) and Tanner-Whitehouse 3 (TW3) outputs for the same hand-wrist radiograph. Understanding the pattern of discrepancy and the causation factors is essential for radiologists.

We aim to quantify the discrepancy between GP and TW3 standards generated by BoneXpert AI in a paediatric cohort in our hospital, identify any age-specific patterns associated with major divergences and look into the reasons behind.

Materials and methods:
A retrospective review of 50 consecutive paediatric hand-wrist radiographs analysed by BoneXpert AI

at our hospital in July 2026 was conducted. For each study, automated GP and TW3 bone ages, chronological age, indications and patient demographics were recorded. Differences between GP and TW3 values were calculated and stratified by age groups. Examples of discrepancy would be quoted.

Results:
11/50 (22%) radiographs showed major discrepancies (>1 year difference) and another 11/50 (22%) radiographs showed minor discrepancies (>0.5 year difference) in bone age evaluation by AI software using GP and TW3 standards. Most of the discrepancies involved children in peri-pubertal age (15/22; 68%). Factors resulting in systematic discrepancy between standards are discussed, with focus on difference in bone weighting between the standards. Ways to tackle the discrepancy are discussed, in particular use of the same standard to track serial bone age studies. If in doubt, we recommend use of GP standard by AI as this was validated locally in Hong Kong.

Conclusion:
AI is a powerful tool for workflow efficiency, but it does not replace expert radiological judgment. Radiologists shall actively verify AI outputs, understand the underlying differences between GP and TW3 standards, and contextualize reporting to guide paediatric endocrinologists effectively.

Poster 11

Thinking Beyond the Breast: Extra-Mammary Findings, Clinical Relevance, and Interpretation Pitfalls on Breast MRI

Author(s) and Institution(s):
WH Jim[1], SH Lee[1], L Xu[1], C Yang[1], OC Li[1]
[1]Department of Radiology and Nuclear Medicine, Tuen Mun Hospital

Objectives:
To illustrate the spectrum of extra-mammary findings encountered on breast magnetic resonance imaging (MRI), highlight recognition pitfalls related to breast MRI protocols, and emphasise the potential management implications of extra-mammary findings, e.g. cardiac findings. A systematic approach to imaging review is advocated.

Materials and methods:
We retrospectively reviewed breast MRI examinations performed within the New Territories West Cluster (NTWC) from 2020 to 2025. Cases were selected to highlight three domains: (1) protocol-related pitfalls, (2) extra-mammary abnormalities, (3) a systematic approach to image interpretation.

Results:
First, we demonstrate the inherent technical limitations/pitfalls associated with breast MRI protocols.

Dedicated breast coils optimize signal-to-noise ratio within the breasts but may result in signal drop-off and reduced conspicuity of adjacent extra-mammary structures. Furthermore, contrast timing is tailored to demonstrate early enhancement in breast lesions; be aware that extra-mammary lesions with differing enhancement kinetics may be incompletely characterised in some sequences. This exhibit illustrates a spectrum of extramammary abnormalities, including hepatic masses, mediastinal thymomas, and indeterminate lung nodules.

Second, conspicuous cardiomegaly, should be recognized and reported as appropriate, while acknowledging the limited capability of breast MRI for formal cardiac assessment. Such findings warrant early clinical correlation and dedicated cardiac evaluation for treatment planning before potential cardiotoxic therapy.

Third, to minimize overlooked abnormalities, we adopted a systematic approach proposed by Gao et al. (2017) for evaluating extra-mammary structures. This includes routinely scrutinizing scout views and evaluating all imaging planes to overcome potential concealment by saturation bands.

Conclusion:

Although breast MRI is tailored to evaluate the breasts and axillae, it includes portions of the thorax, upper abdomen, and skeleton. Familiarity with protocol-related limitations and a systematic review of the entire field of view facilitate recognition of clinically relevant extra-mammary findings and appropriate further evaluation.

Poster 12

Benign Mimickers of Male Breast Malignancy

Author(s) and Institution(s):

Katherine Wong[1], Stefanie W.Y. Yip[2], H. L. Chau[2], Winnie C.W. Chu[2] , Esther H.Y. Hung[2]

[1]Department of Radiology, North District Hospital, 9 Po Kin Road, Sheung Shui, Hong Kong

[2]Department of Imaging and Interventional Radiology, The Chinese University of Hong Kong, Prince of Wales Hospital, 30-32 Ngan Shing Street, Shatin, Hong Kong

Objectives:

Most males with a presenting breast complaint have an underlying benign pathology, yet the clinical presentation of benign male breast conditions overlaps with and can mimic malignancy. Hence the importance of imaging in characterizing the underlying lesion, which is benign in most cases. This review illustrates the imaging hallmarks of key benign male breast conditions in correlation with underlying disease pathophysiology, enabling a confident diagnosis of certain conditions without biopsy, while highlighting features that would warrant tissue sampling.

Materials and methods:

We retrospectively reviewed 503 male cases referred to three tertiary centers for breast imaging during Jan 2022 – Jan 2026 and selected representative images from cases with subsequent histopathology.

This pictorial review uses histologically proven cases to illustrate the key imaging features that define a broad spectrum of benign male breast conditions including gynecomastia (nodular, dendritic, and diffuse types), lipoma, angiolipoma, granulomatous mastitis, intraductal papilloma, fat necrosis, abscess, peripheral nerve sheath tumours, hamartoma, fibroadenoma, and cysts.

Results:
The spectrum of commonly encountered breast lesions in males differs from females due to the inherent absence of lobular tissue in male breasts. Gynecomastia, lipoma, fat necrosis, hamartoma, and simple cysts showing classical imaging appearances without atypical features can definitively be diagnosed based on imaging alone. However, granulomatous mastitis and intraductal papilloma can closely resemble malignancy in both radiological and clinical presentation, hence biopsy is required for diagnosis.

Conclusion:
A sound understanding of the radiological hallmarks of common benign male breast conditions is critical for appropriate decision-making, as certain benign entities can definitively be diagnosed based on imaging alone, potentially saving the patient from unnecessary intervention and concern. Meanwhile, biopsy should be the next step of action when appearances are not in line with the typical imaging manifestations of known common benign male breast entities.

Poster 13

"404 Mass Not Found" - Unravelling the Diagnostic Spectrum of Non-mass Lesions in Breast Ultrasound

Author(s) and Institution(s):
Pik Hey Lee[1] , Yu Ting Wong[1], Cherry Cheuk Yan Chan[1], Wai Pan Cheung[1], Lai Wan Lo[1], Wing Sze Mak[1], Lily Ka Man Wong[1], Eliza Po Yan Eliza Fung[1]
[1]Department of Diagnostic and Interventional Radiology, Kwong Wah Hospital, Hong Kong SAR

Objectives:
American College of Radiology (ACR) Breast Imaging Reporting & Data System (BI-RADS) atlas (v2025) formally recognises non-mass lesions (NML) on breast ultrasound as a primary finding, superseding historical and inconsistent descriptors such as 'focal hypoechoic area' or 'focal shadowing. Due to its subtle nature and the substantial morphological overlap of benign and malignant pathologies, NMLs pose a significant diagnostic challenge. This pictorial review provides a comprehensive overview of the diverse sonographic manifestations of NMLs across various pathologies, highlighting key imaging features predictive of benignity and malignancy to assist breast radiologists in optimising risk stratification and clinical management.

Materials and methods:
This retrospective study reviews the sonographic findings for NMLs with biopsy performed between 1

Jan 2010 and 31 July 2026. The following features are examined: Distribution, echogenicity, posterior features, associated sonographic findings and the presence of a mammographic correlate. The clinical presentation of patients are also reviewed.

Results:
Cases representative of various benign, high-risk and malignant pathologies were selected for demonstration.

Conclusion:
High-risk or malignant NMLs often show segmental or linear distributions, reflecting ductal spread. Other features associated with malignancy include calcifications, architectural distortion, posterior shadowing, ductal changes, echogenic rind and hypervascularity. Presence of small cysts is a strong indicator for benignity. The likelihood of malignancy is further elevated by mammographic correlates of calcifications or focal asymmetry, as well as clinical palpability.

Poster 15

Application of Echogenic Rind from BI-RADS 2025: Pearls and Pitfalls

Author(s) and Institution(s):
FCT Yip[1], HF Wong[1], HC Wong[1], YK Wong[1], SH Lee[1]
[1]Department of Radiology, Pok Oi Hospital, Hong Kong SAR

Objectives:
To differentiate the echogenic rind from the echogenic pseudocapsule as defined in the updated BI-RADS (2025) ultrasound lexicon, evaluating their distinct diagnostic significance, imaging characteristics, and impact on lesion measurement during breast ultrasound.

Materials and methods:
This study is a retrospective review of patients presenting with diagnostic breast imaging findings at Pok Oi Hospital, Hong Kong SAR, from 2024 to 2026. Utilizing the hospital's electronic patient record database, cases were selected based on ultrasound findings demonstrating either an echogenic rind or a pseudocapsule.

Results:
An echogenic rind is a thick, irregular, and often poorly demarcated hyperechoic band on breast ultrasound that partially or completely surrounds a mass or non-mass lesion. It disrupts adjacent tissue layers and likely reflects a desmoplastic reaction or peritumoral edema. This feature exhibits high specificity for malignancy. When measuring lesion size, the entire rind must be included, as this total diameter best correlates with true histologic tumor extent.

In contrast, an echogenic pseudocapsule is a thin, smooth, and well-defined echogenic rim surrounding benign lesions. It represents compressed adjacent fibrous stromal tissue and is most commonly observed bordering oval or lobulated, circumscribed benign masses. Radiologists should avoid classifying a lesion as having a pseudocapsule unless a complete, circumferential margin is definitively confirmed across all imaging planes.

Conclusion:
The echogenic rind and pseudocapsule are distinct ultrasound features with opposing diagnostic significance in breast lesions. The updated BI-RADS (2025) lexicon formalizes this distinction and mandates including the entire rind in tumor measurements to avoid size underestimation, a practice that closely correlates with true histologic and MRI extents. Accurate differentiation is critical for appropriate BI-RADS categorization, confident biopsy decisions, and precise surgical planning.

Poster 16

FDG Uptake in Breast Nodules: A Spectrum from Benign to Malignant

Author(s) and Institution(s):
MY Wong, SH Lee, KL Chiu, L Xu, C Yang, OC Li
Department of Radiology, Tuen Mun Hospital, Hong Kong SAR

Objectives:
FDG-PET/CT is widely used in oncologic imaging. However, FDG uptake is not specific for malignancy and may be observed in a broad spectrum of benign and inflammatory processes. Misinterpretation can lead to false positive diagnoses and unnecessary interventions. We present a case series to illustrate the spectrum of FDG-avid lesions across benign and malignant histologies, emphasizing that SUV alone may not accurately reflect the nature of a breast lesion.

Materials and methods:
This is a retrospective, single-centre case series based on review of imaging and histopathologic records. Cases of PET-CT detected breast lesions, with either histologic confirmation or benign assessment (BIRADS 2) on follow-up and at least one breast imaging performed at our center are identified for review. SUVmax was recorded for lesions with available PET data. SUVmax differences between benign, high risk and malignant lesions were compared using the Kruskal–Wallis test and post hoc Mann–Whitney U test, with $p<0.05$ considered statistically significant.

Results:
FDG-avid breast nodules encompass a broad histologic spectrum, including benign entities such as fibroadenoma, granulomatous mastitis, fibrocystic change; high risk entities such as atypical ductal hyperplasia, intraductal papilloma; malignant entities such as ductal carcinoma in situ, invasive ductal carcinoma, invasive lobular carcinoma, lymphoma, and metastatic disease.

53 PET-CT detected breast lesions were included. Median SUVmax was 2.6 for benign (n=21), 2.9 for high risk (n=12) and 4.1 for malignant (n=20). SUVmax across the three categories showed statistically significant difference (p = 0.047). Malignant lesions showed higher SUVmax vs benign lesions (p ≈ 0.048) but there is substantial overlap between malignant and benign lesions.

Conclusion:
FDG uptake reflect a wide range of histologies with overlapping SUVmax despite higher SUVmax in malignant compared with benign lesions. Dedicated breast imaging and histopathology is crucial to ensure appropriate management of PET-detected breast lesions.

Poster 17

Non-mass breast lesions: Unmasking the wide diagnostic spectrum

Author(s) and Institution(s):
HF Wong, FCT Yip, SH Lee
Department of Radiology, Tuen Mun Hospital, Hong Kong SAR

Objectives:
To review non-mass lesions in breast ultrasound, illustrate their broad differential diagnosis and emphasize the importance of radiologic-pathologic correlation for management.

Materials and methods:
Radiological cases of USG breast with diagnosis of non-mass lesions at Tuen Mun Hospital (NTWC) were retrieved from the RIS between January 2016 and September 2026.

Results:
Non-mass lesions on breast USG represent region of altered echotexture without definite shape of a mass. They encompass a wide spectrum from benign entities (e.g., fibroadenoma, fibrocystic changes, diabetic mastopathy) to high-risk and malignant lesions (e.g. atypical ductal hyperplasia, DCIS, invasive carcinoma), with substantial imaging overlap causing diagnostic ambiguity. Multi-modality imaging integration and close radiologic-pathologic correlation are essential for optimizing patient outcomes.

Conclusion:
Non-mass lesions on breast USG pose diagnostic challenges due to their diverse pathological spectrum. Evaluation combining sonographic features, multi-modality imaging, and timely histologic correlation is critical for distinguishing true pathology and prompting early intervention.

Poster 18

Spectrum of "Non-Mass Lesions" in Breast Ultrasound: A Single-Center Retrospective Review and Pictorial Essay

Author(s) and Institution(s):
JKC Lau[1], NITY Ho[1], YH Chan[1], CYM Young[1], HL Chau[1], HY Hung[1], WCW Chu[2]
[1]Department of Imaging and Interventional Radiology, Prince of Wales Hospital, Hong Kong SAR
[2]Department of Imaging and Interventional Radiology, Faculty of Medicine, the Chinese University of Hong Kong, HKSAR

Objectives:
Unlike standard space-occupying masses, "non-mass lesions" (NMLs) lack discrete outer margins, making their detection and characterization on ultrasound diagnostically challenging. As the BI-RADS lexicon continues to refine non-mass descriptors across modalities, recognizing their ultrasound imaging spectrum is crucial for distinguishing benign mimics from subtle malignancies.
The main objective is to illustrate the ultrasound imaging spectrum of breast non-mass lesions (NMLs), emphasizing key BI-RADS descriptors, diagnostic pitfalls, and radiologic-pathologic correlation through a single-center case series.

Materials and methods:
A retrospective database review identified 17 cases of non-mass lesions over a 1-year period in a tertiary center, evaluated via ultrasound. Imaging features were reviewed and correlated with subsequent histopathological results.

Results:
This pictorial essay showcases a diverse spectrum of pathologies. Common benign entities illustrated include fibrocystic change, adenosis with stromal fibrosis, and intraductal papilloma. Malignant counterparts include Ductal Carcinoma In Situ (DCIS), Infiltrating Lobular Carcinoma (ILC), and Invasive Ductal Carcinoma (IDC).

Conclusion:
Non-mass lesions encompass a wide pathologic spectrum ranging from benign mimics to high-grade malignancies. Familiarity with BI-RADS non-mass terminology and ultrasound imaging concordances is essential for radiologists to avoid delayed diagnosis or unnecessary interventions.

Poster 19

Contrast-Enhanced Mammography–Guided Biopsy versus MRI-Guided Biopsy for MRI-Only Detected Breast Lesions: Initial Experience from a Hong Kong Centre

Author(s) and Institution(s):
Dr. Janet Wong Hin Man, Dr. Leanne HQ Chin, Dr. Tina PW Lam, Dr. Grace Ho
Department of Radiology, Queen Mary Hospital, Hong Kong SAR

Objectives:
To evaluate the initial experience of CEM-guided biopsy compared with MRI-guided biopsy for MRI-only breast lesions in a single Hong Kong tertiary centre. Contrast-enhanced mammography (CEM)-guided biopsy is not only a feasible alternative to MRI-guided biopsy for MRI-only breast lesions, but may also show a higher malignancy rate, higher biopsy-based positive predictive value, and lower benign biopsy rate compared with MRI-guided biopsy in local practice.

Materials and methods:
In this retrospective study, we analyzed MRI-guided breast biopsies performed from January 2013 to June 2026 and all CEM-guided biopsies from January 2025 to June 2026 in a single centre. Patient demographics, indications, technical success, complications, histopathology, surgical upgrades were recorded.

Results:
MRI-guided biopsy achieved technical success in 67/72 lesions (86.1%). Five cases were excluded as the procedure was not performed for various reasons and these were excluded from outcome analysis. Amongst successful biopsies, histopathological showed twelve malignancies (17.9%, 12/67), ten high risk (14.9%, 10/67) and forty five benign lesions (67.2%, 45/67). One ductal carcinoma in situ was upgraded to invasive carcinoma at surgery.

CEM-guided biopsy achieved technical success in all thirteen lesions (100%, 13/13). CEM lesions were visible on both low-energy mammography and recombined images in five lesions (38.4%, 5/13) and recombined images in eight lesions (61.5%, 8/13). Histopathology showed four malignancies (30.8%, 4/13), two high risk (15.4%, 2/13) and seven benign lesions (53.8%, 7/13). One LCIS case was upgraded to invasive lobular carcinoma. Minor complications occurred in three patients, all small to medium hematomas that resolved with conservative management (23.1%, 3/13).

Conclusion:
Although limited by the small CEM cohort, this initial Hong Kong experience shows that CEM-guided biopsy achieved 100% technical success, higher malignancy and lower benign biopsy rates than MRI-guided biopsy cohort, and acceptable minor complication rates. CEM-guided biopsy appears to be a feasible and diagnostically efficient alternative to MRI-guided biopsy for MRI-only breast lesions.

Poster 20

"Non-Mass Lesions" in Breast Ultrasound Scan - What are they and what's the implication on BI-RADS v2025?

Author(s) and Institution(s):
Jacqueline Ching Man Sitt[1], Samantha Sum Yue Law[2], Julian Chun Yan Fong[1], Chun Ying Lui[1]
[1]Hong Kong Women's Imaging, Hong Kong SAR
[2]Medical Student, Li Ka Shing Faculty of Medicine, The University of Hong Kong, Hong Kong SAR

Objectives:
A new term "non mass lesion" has recently been introduced to the ultrasound section in the updated BI-RADS v2025 lexicon. While new to the reporting system, the sonographic findings have actually been recognized by breast radiologists and sonographers during our daily practice for long - just that there wasn't a recognized terminology to formally describe it in our prior reports.

This education exhibit aims to discuss the definition, appearance and sonographic features of non mass lesions, with a discussion on approach (cross modality correlation), differential diagnoses and common pathologies (malignant ones including DCIS, invasive lobular carcinoma, inflammatory cancer; benign entities eg PASH, DM mastopathy; and inflammatory conditions etc).

Materials and methods:

Results:

Conclusion:
Breast imagers should get ourselves familiarized with the new term "non-mass lesions" and learn to apply it in our ultrasound scanning and reporting.

Poster 21

USG-guided Non-wire localization technique: various options and how we do them.

Author(s) and Institution(s):
Jacqueline Ching Man Sitt[1], Anna Yuen Ying Lam[2], Julian Chun Yan Fong[1], Chun Ying Lui[1]
[1]Hong Kong Women's Imaging, Hong Kong SAR
[2]Medical Student, Li Ka Shing Faculty of Medicine, The University of Hong Kong, Hong Kong SAR

Objectives:
Non-wire localization techniques have opened up more flexible options for breast surgeons and their patients to prepare for elective breast cancer surgeries.

Such techniques have great advantages, including
- increasing patient's comfort without the need of witnessing / handling a needle wire on breast
- easy scheduling for the procedure, which can be done days or even weeks before the surgery, granting patient better flexibility and comfort (eg shower as usual before operation)

This education exhibit aims to give an introduction to the major devices our clinic use in daily practices, namely, SaviScout, MagSeed, RFID, as well as premium metallic markers which are highly visible on ultrasound scan (eg Twirl Marker, TuMark Vision and HydroMark). The discussion will cover the nature of the devices, the pros and cons of each product, and the pearls in patient selection. Tips on identifying contraindications and how to use such devices in combination, will also be discussed.

Materials and methods:

Results:

Conclusion:
Breast imagers should be familiarised with the various non-wire localization techniques, in order to work hand-in-hand with the breast surgeons and help facilitate their practices.

Poster 22

MRI Guided - SCOUT BX Localization of Breast Lesion (First Asian Experience)

Author(s) and Institution(s):
CSY Lo[1], VHG Ai[1], KK Wong[1], WSY Yu[1], YS Lee[1], R Lee[1], BWH Ho[1], PSY Cheung[2], PPK Tsui[3], KKM Lai[4], JCH Wong[5] and GG Lo[1]
[1]Department of Diagnostic and Interventional Radiology, Hong Kong Sanatorium & Hospital, Hong Kong SAR
[2]Department of Surgery, Hong Kong Sanatorium & Hospital, Hong Kong SAR
[3]Prism Technologies Limited, Hong Kong SAR
[4]Merit Medical Asia Company Limited, Hong Kong SAR
[5]Hologic Asia Pacific Limited, Hong Kong SAR

Objectives:
- To perform the first MRI guided insertion of SCOUT breast marker
- To assess the feasibility of using MRI for SCOUT insertion in the future

Materials and methods:
- MRI (Siemens 3T Skyra)
- Local anesthesia
- 9G Introducer Localization Set for ATEC
- SCOUT Bx Biopsy Delivery System (SCOUT Bx Reflector and Delivery System End Deploy 15G 12.3cm)

Results:
- Technically successful insertion of SCOUT breast marker
- Ability to see SCOUT marker on post-procedural MRI, mammogram and ultrasound

Conclusion:
- Technically successful insertion of SCOUT breast marker, which we think will be useful for future cases.

Poster 23

Developing asymmetry - why is it still important in BI-RADS v2025?

Author(s) and Institution(s):
Jacqueline Ching Man Sitt[1], Sherman Yin Man Chan[2], Julian Chun Yan Fong[1], Chun Ying Lui[1]
[1]Hong Kong Women's Imaging, Hong Kong SAR
[2]Medical Student, Li Ka Shing Faculty of Medicine, The University of Hong Kong, Hong Kong SAR

Objectives:
The term “developing asymmetry” has been taken down from the new version of BI-RADS v2025. Although the term is discouraged to be used in reporting, the concept is actually still crucial for early breast cancer detection and should remain on your check list when reading every mammogram.

Very often such asymmetries can be difficult to detect, especially in patients with prior surgical scars, patients with dense breasts, or very small cancers in fatty breasts.

This education exhibit showcases how developing asymmetries, when pursued by careful comparison with prior films, altogether with the use of artificial intelligence, MRI and accurate biopsy facilities, helped radiologists detect small cancers early.

Materials and methods:

Results:

Conclusion:
Although the term "developing asymmetry" has been taken out from the latest version of BI-RADS lexicon, the concept is still valid and should remain as part of the checklist for breast imagers when reading serial mammograms.

Poster 24

From Promise to Practice: Real-World Data shows ~18% intraindividual Radiation Dose Reduction using PCD-CT in Aortoiliac CT Angiography

Author(s) and Institution(s):
Tim Oechsner[1], Christopher Schuppert[1], Christopher L. Schlett[1]
[1]Department of Diagnostic and Interventional Radiology, Medical Center–University of Freiburg, Faculty of Medicine, University of Freiburg, Freiburg, Germany

Objectives:
Small cohort and phantom studies suggested photon-counting detector CT (PCCT) can reduce radiation dose in aortoiliac CT angiography (CTA), but real-world evidence in routine clinical practice is limited.

Materials and methods:
We retrospectively screened 14,603 aortoiliac CTAs performed at a single tertiary-care center between January 2021 and April 2025 using a dose M prefiltering combined with rule-based metadata categorization in R. In this IRB-approved study, we identified routine arterial-phase CTA and included patients with at least two CT scans per technology (PCD-CT and EID-CT). We selected the two most recent CT scans with each detector technology per patient allowing strict intraindividual comparison in a matched-pairs design. Dose-length product (DLP) and CTDIvol were compared using mixed-effects linear regression with random intercepts for patients to appropriately account for within-patient correlation.

Results:
The final matched-pairs cohort consists of 106 patients (mean age 65.4 ± 12.5 years, 66% male) with 424 CT scans in total. Median time interval between paired examinations was 220 days (IQR 167–372 days). Mean DLP decreased with PCD-CT from 359.1 ± 157.6
to 320.6 ± 97.8 mGy·cm (10.7% reduction; 95%; $p < 0.001$; Cohen's $d = 0.457$), and CTDIvol decreased from 5.10 ± 2.09 to 4.54 ± 1.23 mGy (11.0% reduction; $p < 0.001$; Cohen's $d = 0.492$). Intraindividual patient analysis after mixed-effects modeling showed greater dose reduction of 62.9 mGy·cm DLP (17.5% relative reduction; $p < 0.001$) after adjusting for body mass index, scan length, sex, age, and temporal trends. Dose reduction benefits were consistent across patient subgroups and additional testing was supporting appropriate model specification.

Conclusion:
This large intra-individual matched-pairs study provides a modest, but robust reduction in routine practice with PCD-CT. In arterial aortoiliac CTA, PCD-CT consistently reduced radiation exposure compared with state-of-the-art EID-CT, supporting broader clinical adoption and protocol optimization.

Poster 26

Ultrasonographic Analysis of Effects of Seated Stretching on Popliteal Venous Haemodynamics after Prolonged Sitting

Author(s) and Institution(s):
SYS Tin[1], HH Chan[1], YT Cheung[1], MY Chung[1], KCN Ho[1], KW Lai[1], WCW Chu[2] and C Chiyanika[1,2]
[1]Department of Health Technology and Informatics, The Hong Kong Polytechnic University, Hong Kong SAR
[2]Department of Imaging and Interventional Radiology, The Chinese University of Hong Kong, Hong Kong SAR

Objectives:
To quantify changes in popliteal vein haemodynamics after 1 hour of sitting and to determine whether a brief seated stretching protocol can improve venous return while maintaining the seated posture.

Materials and methods:
In this prospective repeated-measures study, 34 healthy adults aged 18-30 years (19 men, 15 women) underwent bilateral popliteal vein assessment after 60 minutes of sitting and again after completion of a brief seated stretching protocol comprising heel raises and hamstring/calf stretching. B-mode and triplex Doppler ultrasound were used to measure popliteal vein cross-sectional area (CSA) and time-averaged mean velocity (TAMV). Volume flow rate (VFR) was calculated as CSA × TAMV.

Results:
For the whole cohort, CSA did not change significantly ($p = 0.175$). In contrast, TAMV increased significantly from 2.40 to 4.04 cm/s (+68.3%, $p < 0.001$), and VFR increased from 0.77 to 1.62 cm^3/s (+110.4%, $p < 0.001$). No significant sex differences were observed in pre-stretching haemodynamic parameters or in post-stretching VFR ($p > 0.05$). However, post-stretching CSA was significantly higher in men (0.45 vs 0.31 cm^2, $p = 0.002$), whereas post-stretching TAMV was significantly higher in women (4.31 vs 3.65 cm/s, $p = 0.015$).

Conclusion:
A brief seated stretching protocol significantly improved popliteal venous return after prolonged sitting, primarily through increased blood flow velocity rather than alteration in venous calibre. This simple, equipment-free intervention may represent a practical strategy for reducing sitting-related venous stasis in sedentary settings. Further studies are required to confirm its clinical value in older and at-risk populations.

Poster 27

Audit of Entecavir Discontinuation and Post-Treatment Monitoring in Oncology Patients

Author(s) and Institution(s):
Ying Chan[1], Natalie Sean Man Wong[1], Winnie Wing Yan Tin[1], Ann Shing Lee[1]
[1]Department of Clinical Oncology, Tuen Mun Hospital, Hong Kong SAR

Objectives:
Hepatitis B virus (HBV) reactivation poses a known risk in oncology patients receiving immunosuppressive systemic anti-cancer therapy (SACT). The Hospital Authority (HA) guidelines (Version 3.0, effective 31 July 2024) recommend antiviral prophylaxis and structured monitoring. Following implementation of an electronic departmental template in September 2024, this quality improvement project assessed compliance with Entecavir (ETV) prescription and post-treatment monitoring in our centre.

Materials and methods:
Patients who completed radical intent SACT with ETV cover between December 2024 and March 2025 were included (initial audit, n=46). After identifying suboptimal compliance, the following improvement measures were implemented since May 2026: (1) departmental education and case sharing for oncologists, pharmacists and nurses; (2) promotion of template-based monitoring protocols; (3) clear documentation by CMS hepatitis alert, ETV keep-record in the prescription. A re-audit was performed on eligible patients from June to July 2026 (n=17).

Results:
Initial audit (n=46): Adequacy of ETV prescription post-SACT was 93.5% (43/46). Adequacy of post-ETV discontinuation blood monitoring was 51.4% (19/37 ; 9 patients were excluded as lifelong ETV was indicated). Referral to hepatologists for high HBV reactivation risk patients was 100% (9/9). Among the 19 patients who discontinued ETV and had monitoring, 5 (26.3%) developed HBV reactivation (all had HBsAg+ or detectable baseline HBV DNA). Utilisation of electronic departmental ETV prescription and discontinuation template was 34.8% (16/46).

Re-audit (n=17): Adequacy of ETV prescription post-SACT was 100% (17/17). Adequacy of post-ETV discontinuation blood monitoring was 60% (9/15 ; 2 patients were excluded as lifelong ETV was indicated). Utilisation of departmental template was 52.9% (9/17).

Conclusion:
Implementation of targeted interventions led to improvement in compliance with ETV prescription and post-treatment monitoring. This audit highlights the value of education, standardised electronic tools, and clear handover protocols in reducing HBV reactivation risk. Periodic re-audits are recommended to sustain these gains.

Poster 28

Salvage Image-Guided Interstitial Brachytherapy Using 3D-Printed Multichannel Applicator and Customized Perineal Template for Isolated Suburethral Vaginal Recurrence of High-Grade Endometrial Adenocarcinoma

Author(s) and Institution(s):
Cheng Ngan Sum Jean, Wu Wing Shan, Leung Ka Chun, Chan Suet Nga, Wong Hiu Ching Ada, Chan Ngai Yui, Lee Wan Yan Venus, Yip Wing Ling Winnnie, Wong Chi Sing Frank, Tung Yuk
Department of Clinical Oncology, Tuen Mun Hospital, Hong Kong

Objectives:
To report the technical feasibility, dosimetry, and early clinical outcome of salvage external beam radiotherapy (EBRT) plus high-dose-rate (HDR) image-guided interstitial brachytherapy (IGBT) using a 3D-printed multichannel applicator with customized perineal template in a virgin patient with isolated suburethral vaginal recurrence of endometrial carcinoma.

Materials and methods:
A 58-year-old virgin patient underwent TAHBSO + PLND for pT1bN0 G3 endometrial cancer with extensive LVSI, POLE wild-type, dMMR, ER-negative, and subclonal p53 mutation. Rapid suburethral vaginal recurrence was confirmed on biopsy after vaginal bleeding, prior to adjuvant radiotherapy. MRI showed a 3.6×2.6×4.2cm lower vaginal tumour invading the urethra and left puborectalis; PET-CT confirmed isolated disease. Salvage EBRT (45 Gy/25 fractions) was delivered. Pre-brachytherapy MRI showed still significant residual tumour (3.9×2.6×3.8 cm). Four fractions of IGBT were given using a 1.5cm 3D-printed multichannel applicator with perineal needles through a customized perineal template (14 needles in fractions 1–2; 11 in 3–4). Planning used MRI-CT fusion with applicator in situ.

Results:
Combined treatment (EQD2 α/β=10 for tumour) achieved GTV D98 82.5 Gy, HR-CTV D90 88.2 Gy, LR-CTV D90 62.3 Gy. OAR doses (α/β=3) were: Bladder D2cc 58.7 Gy, Rectum D2cc 66.5 Gy, Sigmoid D2cc 45.5 Gy, Bowel D2cc 46.1 Gy, Urethra D0.1cc 69.0 Gy. Acute toxicity was limited to dysuria that resolved conservatively. Follow-up MRI showed residual soft tissue thickening (1.2×0.8×0.9cm) without restricted diffusion, consistent with post-treatment change. Clinical exam revealed fibrotic scar with resolved induration and smooth mucosa.

Conclusion:
Salvage radiotherapy with 3D-printed multichannel interstitial brachytherapy and customized template provided excellent tumour coverage with good OAR sparing and minimal toxicity in this challenging virgin patient with suburethral recurrence. This demonstrates the value of customized applicators for optimal therapeutic ratio.

Poster 29

Intervendor performance comparison of two commercial deformable image registration software systems in the head and neck region

Author(s) and Institution(s):
Celina K W Li[1]
[1]Department of Clinical Oncology, Tuen Mun Hospital, Hong Kong

Objectives:
To compare the performance of deformable image registration (DIR) algorithms for head and neck patients between two widely used commercial software systems: MIM and RayStation.

Materials and methods:
Ten virtual phantoms from the Deformable Image Registration Evaluation Project library were used. These phantoms were derived from the clinical head and neck patient datasets. Each phantom contained a start-of-treatment CT image paired with an end-of-treatment CT image. Five organs at risk were delineated, including the mandible, spinal cord, brainstem, left parotid, and right parotid. DIRs between the CT datasets were performed using both MIM (Version 7.4.2, Build OA 10-09) and RayStation (v2025 SP1, v17.0.1.113). While the image registration accuracy of these two systems was benchmarked in a previous study in terms of target registration error, the MIM Deformable Image Registration Quality Assurance tool was deployed in this study to quantitatively compare the registration performance between these two systems. Multiple quantitative metrics recommended by AAPM TG-132 were used for the comparison, including Hausdorff Distance (HD), Mean Distance to Agreement (MDA), Dice Similarity Coefficient (DSC), and Jaccard Index (JI).

Results:
The overall registration discrepancies between the DIR algorithms from the two vendors were small. The mean intervendor differences in HD, MDA, DSC, and JI were 0.497 ± 0.983 mm, 0.110 ± 0.156 mm, 0.018 ± 0.023, and 0.032 ± 0.041, respectively. The registration differences were found to be the largest for the left and right parotid.

Conclusion:
Both DIR algorithms demonstrated comparable spatial registration performance under the AAPM TG-132 framework, with negligible mean differences in HD, MDA, DSC, and JI. Either system can be considered clinically acceptable for standard clinical contour propagation and adaptive radiotherapy, allowing clinicians to select platforms based on institutional workflow compatibility.

Poster 30

CT Radiomics Combined With Clinical and Imaging Features for Identifying High-Grade Serous Ovarian Carcinoma

Author(s) and Institution(s):
Yoo Kyung Choi, MD, PhD[2]; Sunmin Park, MD, PhD[2]
[2]Department of Radiation Oncology, Korea University Ansan Hospital, Ansan, Republic of Korea

Objectives:
Preoperative identification of high-grade serous carcinoma (HGSC) may support histologic risk stratification, surgical triage, and multidisciplinary treatment planning, although histopathologic confirmation remains the diagnostic standard. This study evaluated whether CT radiomics improves HGSC identification when combined with clinical parameters and radiologist-defined imaging features.

Materials and methods:
This retrospective study included 112 patients with histologically confirmed primary epithelial ovarian tumors who underwent preoperative contrast-enhanced CT from January 2010 to June 2024. A total of 143 ovarian lesions were analyzed. Radiologist-defined imaging features included bilateral disease, ascites, peritoneal seeding, omental cake, lymph node enlargement, and solid component. Radiomic features were extracted from whole-tumor, peritumoral, rim, and core regions of interest. Four random forest models were compared: clinical-only, imaging-only, radiomics-only, and all-combined models. The primary endpoint was binary classification of HGSC versus non-HGSC tumors. Performance was evaluated using 20 repetitions of stratified 70:30 holdout validation.

Results:
The all-combined model showed the best performance, with a macro-AUC of 0.927 ± 0.042, accuracy of 0.857 ± 0.058, balanced accuracy of 0.846 ± 0.064, and macro-F1 score of 0.849 ± 0.064. It outperformed the clinical-only model (macro-AUC, 0.795 ± 0.069), imaging-only model (0.694 ± 0.090), and radiomics-only model (0.785 ± 0.066). Log10-transformed CA-125 was the most important predictor. Key imaging-derived contributors included peritumoral, rim, and rim-to-core radiomic texture features, peritoneal seeding, bilateral disease, omental cake, lymph node enlargement, and solid component.

Conclusion:
Integration of clinical, radiologist-defined imaging, and CT radiomic features improved preoperative identification of HGSC. CT radiomics may provide complementary quantitative information to conventional clinical and visual imaging assessment and may support preoperative risk stratification, rather than replace definitive histopathologic diagnosis.

Poster 31

Baseline Cardiac Assessment before Anthracycline-Based Chemotherapy for Early Breast Cancer

Author(s) and Institution(s):
Vivian HM Tsang[1], Joyce JS Suen[1]
[1]Department of Clinical Oncology, Prince of Wales Hospital, Hong Kong SAR

Objectives:
To assess and improve adherence to baseline LVEF assessment before anthracycline-based chemotherapy in patients with HER2-negative early breast cancer.

Materials and methods:
A retrospective audit with planned re-audit was conducted. Baseline data were collected from October 2024 to March 2025, followed by implementation of workflow and educational interventions. Re-audit was performed from September 2025 to February 2026. Primary outcome was documented referral for baseline LVEF assessment. Secondary outcomes included completion of assessment and identification of barriers.

Results:
At baseline, 16/50 patients (32.0%) had documented referral for LVEF assessment. Over half of high-risk patients proceeded to anthracycline therapy without baseline assessment. Following intervention, referral rates improved to 83.1% (54/65), with high-risk referral rates of 88.9% (ASCO 2017 definition) and 91.3% (ESMO 2020 definition). Completion rates were 100% among those referred. The proportion of patients receiving anthracyclines without baseline LVEF assessment decreased from 62.7% to 7.5%. Residual non-compliance was associated with individual practice variation.

Conclusion:
Structured workflow changes and targeted education significantly improved adherence to baseline cardiac assessment. Baseline LVEF assessment is feasible when integrated into routine workflow and supports safer delivery of anthracycline-based chemotherapy. Continued monitoring is required to sustain improvement.

Poster 32

Fractionated Stereotactic Radiotherapy for Vestibular Schwannoma: Five-Year Outcomes from a single institution

Author(s) and Institution(s):
P Wong[1], WH Mui[1], NYV Chan[1], FCS Wong[1]
[1]Department of Clinical Oncology, Tuen Mun Hospital, Hong Kong SAR

Objectives:
To evaluate hearing preservation, toxicity, tumour control and early radiological volume change after reduced-dose FSRT predominantly advanced VS, and examine tumour size as a determinant of baseline hearing and early radiological response.

Materials and methods:
We retrospectively analysed 28 patients with VS treated with FSRT (41.4–45 Gy in 23–25 fractions) between January 2018 and May 2025. Eligibility required ≥12 months of clinical, audiometric, and gadolinium-enhanced MRI follow-up. Patients with neurofibromatosis type 2, prior VS irradiation, or incomplete follow-up data were excluded. Actuarial tumour control and serviceable hearing preservation rates were estimated by the Kaplan–Meier method. Serviceable hearing was defined as pure-tone average <50 dB with documented functional hearing. Mann-Whitney U and Fisher's exact tests were used to examine associations between tumour size metrics and baseline hearing or radiological response.

Results:
Median follow-up was 45.5 months (range 12–109). Most tumours were Koos grade IV (82.1%) and median maximal extrameatal diameter was 2.7 cm (0.98–4.5); 50% had prior surgery and 75% had non-serviceable hearing at baseline. Cochlear mean dose ≤45 Gy was achieved in 92.9% of patients. Actuarial tumour control rate was 88.6% at 1 year. Among the 7 patients with baseline serviceable hearing, 1- and 2-year serviceable hearing preservation rates were both 42.9%. Pseudoprogression occurred in 3 patients (10.7%) at a median of 7.98 months. No treatment-related cranial neuropathy was observed. Larger tumour size was independently associated with non-serviceable hearing at baseline (p=0.003) and with early radiological enlargement (p=0.023).

Conclusion:
Reduced-dose FSRT achieved durable tumour control and a favourable cranial nerve toxicity profile in a predominantly advanced VS cohort. Serviceable hearing preservation was modest, reflecting pre-existing auditory compromise driven by tumour size rather than FSRT toxicity. These findings support FSRT as an effective and well-tolerated modality for anatomically complex or surgically high-risk VS, where local control and cranial nerve preservation are the primary goals.

Poster 33

Efficacy and Safety of Stereotactic Body Radiotherapy for Unresectable Liver Metastases

Author(s) and Institution(s):
KY Lui[1], WL Chan[2]
[1]Department of Clinical Oncology, Prince of Wales Hospital, Hong Kong SAR
[2]Department of Clinical Oncology, Queen Mary Hospital, Hong Kong SAR

Objectives:
Technological advancements have established stereotactic body radiotherapy (SBRT) as a compelling therapeutic alternative for patients with unresectable liver metastases. While previous literature has demonstrated the efficacy of SBRT in achieving favourable clinical outcomes, this study evaluates the efficacy and safety of SBRT within local clinical practice and aims to discover independent prognostic factors.

Materials and methods:
This retrospective cohort study evaluated data of patients who underwent SBRT for liver metastases at the Prince of Wales Hospital and the Queen Mary Hospital between January 2015 and December 2023. 1- and 2-year local control (LC) rates and overall survival (OS) rates were estimated using the Kaplan-Meier method. Subgroup analysis was subsequently performed using the Cox proportional hazards model.

Results:
A total of 53 patients with 72 treated liver metastases were identified. The median local control duration was 24.5 months (range from 1 to 125 months), with actuarial 1- and 2-year LC rates of 77% and 67.3%, respectively. The median survival duration was 26 months (range from 3 to125 months), with actuarial 1- and 2-year OS rates of 84.6% and 61.5%, respectively. SBRT was well-tolerated by majority of the cohort. No grade 3 or grade 4 toxicity was reported. Breast cancer cohort demonstrated a significant reduction in risk of death, having 91.3% lower risk of death than colorectal cancer cohort (HR = 0.087, p = 0.032, 95% CI = 0.009-0.812).

Conclusion:
The results signified SBRT as a critical liver-directed therapy, proving effective in achieving local control and prolonging overall survival in patients with unresectable liver metastases, while maintaining an exceedingly low incidence of toxicities. While local control tended to correlate with tumour size, overall survival was predominantly determined by primary cancer type.

Poster 34

MRI Screening for Pulsatile Tinnitus: Initial Local Experience From Kowloon West Cluster

Author(s) and Institution(s):
BY Lee[1], HM Kwok[1], LF Cheng[1]
[1]Department of Diagnostic and Interventional Radiology, Princess Margaret Hospital, Kowloon West Cluster, Hong Kong SAR, China

Objectives:
Pulsatile tinnitus demands dedicated imaging screening for structural etiology, particularly clinically significant vascular causes. We describe a regionally-implemented pulsatile tinnitus (PT) MRI screening protocol in Kowloon West Cluster, and initial experience on diagnostic yield.

Materials and methods:
Inclusion criteria was initial PT imaging in Kowloon West Cluster. Exclusion criteria was indication other than initial PT imaging, or off-protocol scans. Data extracted from Radiology Imaging System.

The protocol comprised axial T1 and T2 and post-contrast T1 MPRAGE sequences of brain, 3-dimensional heavily T2-weighted sequences of internal acoustic meati, time-of-flight MR angiography from carotid bifurcation to circle of Willis, performed at 3 Tesla (MAGNETOM Vida, Siemens) and 1.5 Tesla (MAGNETOM Sola, Siemens; and Ingenia Ambition, Philips). All scans were interpreted using a standardised checklist.

30 consecutive patients (aged 14-79, 19 female) undergoing MRI for initial assessment of PT from 1/9/2024 to 31/7/2026 were included. 18 had left-sided PT, 8 right, and 4 bilateral. None had retrotympanic masses on otoscopy.

Results:
19 (63%) scans showed potential structural causes or PT. 9 (30%) had clinically significant vascular causes needing early attention, including intracranial hypertension with transverse sinus stenosis (n=2), dural arteriovenous fistulae (n=2), pre-auricular arteriovenous malformation (n=1), moderate or severe internal carotid artery stenosis (n=3), and basilar artery aneurysm (n=1).

10 (33%) scans showed less severe etiologies but still of clinical import with growing therapeutic options, such as superior semicircular canal dehiscence, transverse sinus stenosis without intracranial hypertension, prominent occipitomastoid emissary veins, jugular or sigmoid sinus dehiscence or diverticula, or mild internal carotid artery stenosis.

11 (37%) of scans were concluded negative after comprehensive assessment using the structured checklist.

Conclusion:
Our PT MRI screening protocol, coupled with a structured reporting checklist, demonstrates robust diagnostic yield for clinically significant vascular etiologies (30%).

Poster 35

Medication-related osteonecrosis of the jaw: role of multimodality imaging assessment

Author(s) and Institution(s):
ML Tsang[1], KY Li[2], SH Lee[1], Y Leng[2], WY Fung[2], HM Kwok[2]
[1]Department of Radiology, Tuen Mun Hospital, Hong Kong SAR
[2]Department of Diagnostic and Interventional Radiology, Princess Margaret Hospital, Hong Kong SAR

Objectives:
To review imaging features of medication-related osteonecrosis of the jaw (MRONJ), emphasising complementary roles of computed tomography (CT) and magnetic resonance imaging (MRI) in assessing disease extent and complications to support diagnosis and treatment planning.

Materials and methods:
Patients with MRONJ were retrospectively identified from the Radiology Information System between 1 January 2023 and 30 June 2026 across three hospitals in the Kowloon West Cluster. Clinical information and imaging were reviewed. Selected anonymised CT, cone-beam CT and MRI images from patients (n=6) illustrate osseous and soft-tissue manifestations.

Results:
MRONJ is a clinical diagnosis supported by imaging and requires correlation of relevant medication exposure, clinical examination and radiological findings. Panoramic radiography may underestimate early disease and osseous extent. CT provides high-resolution delineation of bony architecture and maps disease extent. Findings include osteolysis, osteosclerosis or mixed lytic-sclerotic change, altered trabecular architecture, persistent extraction sockets, cortical erosion or perforation, periosteal reaction, sequestrum and fragmentation. CT also demonstrates extension to the inferior alveolar canal, mandibular border, ramus or maxillary sinus, and complications including pathological fracture, abscess, sinus tract and oroantral communication. Cone-beam CT offers higher spatial resolution at a lower radiation dose. MRI assesses marrow abnormality and inflammatory soft-tissue extension, which may exceed clinical or CT-defined extent. Typical MRI findings include low T1-weighted and high T2-weighted marrow signal, low signal in sclerotic or devitalised bone, variable enhancement, and fistula, phlegmon or abscess.

Conclusion:
Multimodality imaging is integral to MRONJ assessment. CT defines osseous involvement and complications, while cone-beam CT offers higher spatial resolution at a lower radiation dose. MRI characterises marrow and soft-tissue extension. Together, these modalities define disease extent and facilitate multidisciplinary communication and treatment planning.

Poster 36

CT Assessment of Necrotizing Otitis Externa: From Early Canal Narrowing to Skull Base Destruction

Author(s) and Institution(s):
CSJ Wong[1], KO Cheung[1], KH Wong[1]
[1]Department of Radiology, North District Hospital, Hong Kong SAR

Objectives:
Necrotizing otitis externa (NOE) is a locally aggressive infection predominantly affecting elderly or

immunocompromised patients. Computed tomography (CT) plays an essential role in mapping disease extent. We aim to review its key anatomical spreading pathways and illustrate its spectrum of CT presentations, from early external auditory canal narrowing to advanced skull base destruction.

Materials and methods:
A retrospective review of CT temporal bone examinations performed in our institution from 1/1/2006 to 10/8/2026 for patients with clinically suspected necrotizing otitis externa. Representative imaging cases were selected to demonstrate how the infection propagates across different anatomical landmarks and spaces.

Results:
Our cases demonstrate varied presentations of NOE and highlight key anatomical spreading pathways to guide on-call reporting.

Anterior spread is more frequently seen with invasion through the anterior canal wall into the temporomandibular joint fossa, parotid gland, and masticator space. Medial and deep skull base spread may reach the parapharyngeal fat and carotid space, with potential erosion of the petrous and tympanic temporal bone, involving the carotid canal and petroclival junction. Posterior spread can result in erosion of the lateral mastoid cortex, coalescent mastoiditis and abscess formation beyond the mastoid tip, around the sternocleidomastoid muscle insertion site.

Advanced NOE often exhibits multidirectional spread and may lead to intracranial complications, including dural enhancement and deep venous sinus thrombosis.

Conclusion:
Necrotizing otitis externa may present with a variable imaging spectrum depending on the disease stage. Recognizing the various directions of deep structural spread enables radiologists to detect subtle involvement early, ensuring more accurate evaluation and reporting.

Poster 38

Updating the Lexicon: A Pictorial Review of the 2026 SSR Standardized MRI Nomenclature for Knee Menisci

Author(s) and Institution(s):
Jim WH[1], Wong YK[1], L Xu[1], A Pun[1], P Cheung[1], Chong WH[1]
[1]Department of Radiology & Nuclear Medicine, Tuen Mun Hospital, HKSAR

Objectives:
To update the current standardised nomenclature for magnetic resonance imaging (MRI) reporting of knee meniscal lesions suggested by the 2026 Society of Skeletal Radiology (SSR) consensus guidelines, aiming to improve consistency in communication and clinical care.

Materials and methods:
This pictorial review summarizes the consensus recommendations developed by an expert group of musculoskeletal radiologists and orthopaedic surgeons from the SSR.
To enrich the review and demonstrate practical application, we illustrate these key concepts using representative MRI cases sourced from our institution (Tuen Mun Hospital) across two main domains: (I) meniscal anatomy and anatomic variants, and (II) meniscal tears and associated findings. Key terminology changes and reporting best practices are highlighted.

Results:
The review emphasizes the use of descriptive text focusing on surfacing signal and morphologic distortion, abandoning numerical grading for intrameniscal signal.
Using institutional cases, we detail the updated 5-segment anatomical model (anterior root, anterior horn, body, posterior horn, posterior root) and clarify the root zone definition (enthesis plus adjacent 1 cm).
We illustrate the recommended transition from eponyms to anatomic terms for stabilizers (e.g., meniscotibial instead of coronary ligament).
Furthermore, we demonstrate the use of standardized tear descriptors (horizontal, longitudinal-vertical, radial, vertical flap, complex) over rigid classification systems, and clarify terms like "complete" and "partial."
Finally, standardized reporting of meniscal extrusion with numeric measurements at the mid-tibial plateau is showcased.

Conclusion:
Implementing the 2026 SSR consensus nomenclature minimizes ambiguity in knee MRI reporting.
By adopting standardized descriptive terminology illustrated through local clinical cases, radiologists can enhance the clinical utility of their reports, facilitating better interdisciplinary communication and guiding appropriate management.

Poster 39

Role of MRI in Characterising Bicipitoradial Bursitis: A Pictorial Essay

Author(s) and Institution(s):
Andrew Man Kwun Li[1], Yongmei Leng[2], Hing Ki Charmaine Wong[2], Nin-Yuan Pan[2]
[1]Department of Radiology, Queen Mary Hospital, Hong Kong
[2]Department of Radiology, Princess Margaret Hospital, Hong Kong

Objectives:
Bicipitoradial bursitis is an uncommon inflammatory pathology of the elbow that often presents as an ambiguous antecubital mass. Magnetic Resonance Imaging (MRI) plays a critical role in evaluating this pathology through superior soft-tissue resolution and multiplanar capabilities. This pictorial essay

uses cases from Hong Kong institutions to illustrate the role of MRI in characterizing bicipitoradial bursitis.

Materials and methods:
The cases highlight these three key roles of MRI in characterizing bicipitoradial bursitis:
(1) assess structural severity, internal architecture, and adjacent neurovascular compression;
(2) establish underlying etiology by differentiating mechanical from inflammatory drivers; and
(3) systematically distinguish bursitis from cystic and neoplastic mimics.

Results:
Role 1: MRI can evaluate bursal size and signal characteristics (homogeneity of T2-weighted signal), internal architecture (presence of internal septations), wall thickness and synovial proliferation, and adjacent neurovascular impact (relationship with radial nerve).

Role 2: MRI can confirm secondary mechanical bursitis by highlighting intrinsic distal biceps tendon pathology and osseous abnormalities (entheseal hypertrophy). Infectious or crystal-induced etiologies may also display distinct imaging hallmarks on MRI (presence of tophi in gout).

Role 3: Visualisation of the classical 'heart' sign on MRI, due to hugging of the bursa around the biceps tendon, is strongly indicative of bicipitoradial bursitis. MRI is also helpful in differentiating bursitis from other differential diagnoses, such as synovial chondromatosis and soft tissue tumours.

Conclusion:
Utilizing this systematic three-part diagnostic framework for MRI studies of the bicipitoradial region prevents unnecessary, potentially harmful biopsies of benign reactive bursae, while simultaneously ensuring prompt, accurate clinical interventions for complex infectious, crystal-induced, or nerve-compressing cases.

Poster 40

'Diagnosis by sight and sound': Utility of ultrasound at diagnosing the tumour type and malignant potential of soft tissue masses

Author(s) and Institution(s):
Yee Ling Or[1], Cina Shin Loong Tong[1], Stefanie Wai Ying Yip[1], Esther Hiu Yee Hung[1], King Kenneth Cheung[2], Mohammadreza Kosari[1], James Griffith[1]
[1]Department of Imaging and Interventional Radiology, Prince of Wales Hospital
[2]Department of Radiology, North District Hospital

Objectives:
To evaluate the ability of ultrasound to (a) confidently determine the specific type of superficial soft

tissue mass and assess the accuracy of a confident ultrasound diagnosis against histology, (b) accurately identify common individual soft tissue tumour types, and (c) recognise the possibility of malignancy in soft tissue masses.

Materials and methods:
This retrospective single-centre study included 3,853 non-nodal soft tissue masses examined with ultrasound between October 2013 and May 2026. When the reporting radiologist was confident of the lesion type, a single ultrasound diagnosis was recorded; otherwise, up to three differential diagnoses were provided with an assessment of the likelihood of malignancy. Histological confirmation was available for 1,097 (29%) masses. All malignant lesions underwent histological confirmation, while benign lesions were confirmed by histology and/or longitudinal clinical or imaging follow-up. Ultrasound diagnoses were compared with final diagnoses to assess diagnostic accuracy and performance for identifying malignancy.

Results:
A confident ultrasound diagnosis was provided for 2,564/3,853 (67%) masses overall and for 552/1,097 (50%) masses with subsequent histology. Of these 552 confidently diagnosed lesions, 526 (95%) were concordant with final histology. The accuracy of a confident ultrasound diagnosis compared with histology was 99% (257/259) for lipoma, 94% (45/48) for epidermoid cyst, 91% (21/23) for nerve sheath tumour, 91% (40/44) for ganglion cyst, and 39% (5/13) for vascular malformation. Overall, 160/3,853 (4.2%) masses were malignant. Ultrasound correctly identified the possibility of malignancy in 153/160 malignant lesions, corresponding to a sensitivity of 96%, specificity of 91%, accuracy of 91%, positive predictive value of 65%, and negative predictive value of 99%.

Conclusion:
Ultrasound can confidently diagnose the majority of superficial soft tissue masses and demonstrates high diagnostic accuracy for several common lesion types. It is also highly effective in distinguishing benign from malignant lesions, with excellent sensitivity and negative predictive value for identifying the possibility of malignancy.

Poster 41

MR Neurography: Enhancing diagnostic precision through advanced imaging

Author(s) and Institution(s):
Dr PM Chung, Dr ST Wong, Dr HM Kwok, Dr NY Pan
Department of Radiology, Princess Margaret Hospital, HKSAR

Objectives:
Magnetic resonance neurography (MRN) has advanced significantly with 3D acquisition techniques

such as SPACE and double-echo steady-state (DESS), enabling high-resolution visualization of peripheral nerves. This study evaluates the diagnostic and clinical utility of MRN across a broad spectrum of pathologies.

Materials and methods:
Retrospective review of MRN cases from three regional hospitals in the local cluster (May 2023–April 2026), performed at 1.5T or 3T using DESS/SPACE sequences with high spatial resolution and multiplanar reconstruction. Imaging and clinical data were assessed by subspecialized radiologists.

Results:
Cases were categorized into three groups:

Trauma: Facial nerve transection from assault, sciatic nerve compression secondary to rhanomyolysis after fall.

Tumor: Ulnar nerve neurogenic tumor, sciatic nerve infiltration from buttock squamous cell carcinoma.

Inflammatory/Entrapment: Infection related lumbosacral and sciatic neuritis, femoral nerve neuritis, posterior interosseous nerve entrapment, cubital tunnel syndrome, and brachial plexus neuropraxia post reverse shoulder arthroplasty.

MRN could provide detailed anatomical and etiological information to clinicians to guide surgical planning, and to decide on conservative vs interventional management in some cases.

Conclusion:
3T MRN with 3D sequences offers superior spatial resolution and multiplanar capability compared to 1.5T, providing guide to clinical decision making. Our findings underscore MRN's growing role as an essential, non invasive tool for peripheral nerve assessment.

Poster 42

Ultrasound of median nerve swelling in carpal tunnel syndrome: proximal-only measurements may lead to underdiagnosis

Author(s) and Institution(s):
Fran S.F Kwok, MBChB, FRCR[1], James F. Griffith, MD, FRCR[2]
[1]Department of Imaging and Interventional Radiology, Pamela Youde Nethersole Eastern Hospital, Hong Kong
[2]Department of Imaging and Interventional Radiology, Prince of Wales Hospital, The Chinese University of Hong Kong

Objectives:
To determine the frequency of distal assessment in published ultrasound protocols and the anatomical distribution of median nerve swelling in CTS.

Materials and methods:
This retrospective study comprised a structured review of ultrasound-based CTS protocols and analysis of patients with clinically suspected CTS. A 35-year literature review from January 1991 to February 2026 was performed using PubMed, Scopus, and the Cochrane Library. In addition, the ultrasound findings of 353 wrists in 225 patients with clinically suspected CTS between January 2018 and December 2025 were reviewed. Median nerve cross-sectional area was measured at predefined proximal and distal levels, and swelling patterns were classified by location. Statistical analysis was performed using chi-square test and one-way analysis of variance, with $p < .05$ considered significant.

Results:
Of 178 published studies, 62 (35%) incorporated distal median nerve assessment, while 116 of 178 (65%) evaluated proximal sites only ($p = .004$). A total of 225 patients (mean age, 58.8 years ± 13.4 years, 166 women) were evaluated. Median nerve swelling was present in 248 of 353 (70.3%) wrists. Combined proximal-and-distal median nerve swelling was most frequent (121 of 248 [49%] wrists), followed by distal-only (76 of 248 [31%] wrists) and proximal-only (51 of 248 [21%] wrists) swelling patterns ($p < .001$). Mean cross-sectional area was greatest in combined median nerve swelling (19.6 ± 3.4 mm^2) compared with distal-only (18.5 ± 3.7 mm^2) and proximal-only (18.0 ± 3.3 mm^2) swelling patterns ($p = .009$).

Conclusion:
One-third of wrists with median nerve swelling showed distal-only swelling. Proximal-only protocols risk overlooking distal ultrasound abnormalities in clinically suspected CTS. Routine inclusion of distal segments should be considered for assessment of CTS.

Poster 43

Pictorial Essay of SAPHO Syndrome and Mimickers

Author(s) and Institution(s):
FCT Yip[1], Y Leng[2], HK Wong[2], NY Pan[2]
[1]Department of Radiology & Nuclear Medicine, Tuen Mun Hospital, Hong Kong SAR
[2]Department of Radiology, Princess Margaret Hospital, Hong Kong SAR

Objectives:
To illustrate the multimodality imaging appearances of SAPHO syndrome across different organ systems.

Materials and methods:
A retrospective review was conducted of patients presenting with imaging findings of SAPHO syndrome and its diagnostic mimics at Princess Margaret Hospital, Hong Kong SAR, between 2023 and 2026. Relevant cases were identified and evaluated utilizing the hospital's electronic patient record database.

Results:
SAPHO syndrome is a rare, underrecognized autoinflammatory disorder characterized by a combination of synovitis, acne, pustulosis, hyperostosis, and osteitis. It bridges dermatological and osteoarticular manifestations, though skin and bone features do not always present simultaneously. Clinical-radiological diagnosis relies on the Kahn criteria, originally proposed in 1994 and modified at the 2003 American College of Rheumatology Annual Scientific Meeting.

Radiologists must recognize specific osteoarticular patterns to guide targeted management. Affected sites include, in decreasing order of frequency: anterior chest wall, axial spine, appendicular skeleton, and mandible.

When imaging findings tightly align with standard Kahn criteria alongside classic skin lesions, no further invasive investigation is warranted. However, atypical or skin-blank presentations often mimic pyogenic infection, tuberculous osteomyelitis, or osteosarcoma. In these ambiguous scenarios, a bone biopsy or joint aspiration remains mandatory to definitively exclude malignancy or active infection.

Conclusion:
The characteristic osteoarticular signatures of SAPHO syndrome are optimized through multimodality imaging utilizing radiography, bone scintigraphy, MDCT, and MRI. This integrated diagnostic approach is essential for accurately differentiating SAPHO from critical mimics like chronic osteomyelitis and ankylosing spondylitis, ultimately ensuring timely diagnosis and avoiding unnecessary invasive procedures.

Poster 44

The Great Masquerader: Multifocal Pediatric Skeletal Tuberculosis Simulating Bone Malignancy

Author(s) and Institution(s):
Shafora Bibi Samri[1,2]
[1]Department of Radiology, School of Medical Sciences, Universiti Sains Malaysia, 16150 Kubang Kerian, Kelantan, Malaysia
[2]Hospital Pakar Universiti Sains Malaysia, Universiti Sains Malaysia, Health Campus, Jalan Raja Perempuan Zainab 2, 16150 Kota Bharu, Kelantan, Malaysia

Objectives:
This case report aims to illustrate the deceptive clinical and radiological presentation of paediatric

osteoarticular tuberculosis involving the distal humerus in a moderate-burden endemic setting. By documenting this diagnostic journey from an initial suspicion of malignancy to definitive histopathological confirmation. We highlight the limitations of paucibacillary molecular assays, the diagnostic value of cross-sectional imaging features like the penumbra sign, and the imperative role of early tissue biopsy in securing prompt medical management and avoiding radical surgical intervention.

Materials and methods:
None

Results:
None

Conclusion:
Osteoarticular tuberculosis remains a diagnostic challenge due to its variable presentation and overlap with other musculoskeletal diseases. Humeral involvement, as in this case, is particularly uncommon and may closely resemble malignant bone tumours. A high index of suspicion, especially in endemic settings, combined with early biopsy and molecular testing, enables rapid confirmation and prevents unnecessary surgical interventions. Prompt initiation of anti-tuberculous therapy leads to excellent outcomes and minimises long-term morbidity.

Poster 45

Pictorial Essay of Supraspinatus Tendon Tears and Associated Pathologies - Areas to Review

Author(s) and Institution(s):
FCT Yip[1], HC Wong[1], SH Lee[1], YK Wong[1]
[1]Department of Radiology & Nuclear Medicine, Tuen Mun Hospital, Hong Kong SAR

Objectives:
To illustrate the spectrum of rotator cuff tear severity, with a focus on the supraspinatus tendon, and the associated complications.

Materials and methods:
A retrospective review of cases with imaging findings of rotator cuff pathologies at Tuen Mun Hospital (Hong Kong SAR) from 2024 to 2025, using the hospital's electronic patient record database.

Results:
Rotator cuff tears are common injuries that can lead to pain and weakness in the shoulder joint. The supraspinatus tendon is the most commonly affected structure. However, due to the complex anatomy of the shoulder, supraspinatus tendon pathology often occurs together with injuries to other structures.

Commonly associated structures include the infraspinatus tendon, the subscapularis tendon, the long head of the biceps tendon, and the shoulder joint capsule.
Magnetic resonance imaging (MRI) and ultrasonography (USG) are crucial diagnostic tools for evaluating rotator cuff tears. In particular, MRI provides clear visualization of the tendons and surrounding structures, and it helps define the extent and location of tears to guide appropriate treatment planning.
Treatment options for rotator cuff tears include conservative management, such as pain medication and physical therapy, as well as surgical repair for more severe tears or when conservative measures fail. Early diagnosis and timely intervention are essential to prevent further complications and to optimize patient outcomes.

Conclusion:
Supraspinatus tendon tears are frequently associated with other shoulder pathologies, including infraspinatus tendon tears and dislocation of the long head of the biceps tendon. These concomitant conditions can complicate both diagnosis and treatment, underscoring the need for comprehensive assessment and management strategies.

Poster 46

Differentiating Insufficiency Fractures from Bony Metastases in Gynecologic Malignancies: An MRI Pitfall in Patients Undergoing Chemoradiation

Author(s) and Institution(s):
YM Chong[1], G Ho[1]
[1]Department of Radiology, Queen Mary Hospital, Hong Kong SAR

Objectives:
Magnetic Resonance Imaging (MRI) is increasingly used for the initial staging and follow-up of gynecologic malignancies. Patients undergoing pelvic radiation and/or chemotherapy are at high risk for developing pelvic insufficiency fractures due to treatment-induced osteoporosis. The MRI appearance of these fractures, characterized by bone marrow edema and enhancement, can be strikingly similar to that of osteoblastic bony metastases. Misinterpretation can lead to incorrect cancer staging, inaccurate assessment of treatment response, and unnecessary invasive procedures or changes in therapy. The aim of this educational exhibit is to highlight this critical diagnostic challenge and provide a framework for accurate differentiation.

Materials and methods:
We retrospectively reviewed cases from our institution, identifying patients with gynecological cancer who were undergoing chemoradiation and whose surveillance pelvic MRI demonstrated new bony lesions initially suspicious for metastasis by residents. Cases where the final diagnosis was confirmed as a benign insufficiency fracture via imaging follow-up (PET-CT) were selected. We present these as representative case examples to illustrate the key imaging findings.

Results:
Our review clearly demonstrates the characteristic features of pelvic insufficiency fractures on MRI in contrast to true bony metastases. We will showcase side-by-side comparisons to illustrate distinguishing features .

Conclusion:
Pelvic insufficiency fractures are a common benign sequelae of treatment in gynecologic oncology patients and a potent mimic of metastatic disease on MRI. Recognizing their characteristic linear morphology and typical anatomic distribution is essential for radiologists to avoid this diagnostic pitfall. Accurate differentiation prevents false-positive diagnoses, ensures correct cancer staging and response evaluation, and guides appropriate patient management towards conservative fracture care rather than unwarranted changes in oncology treatment.

Poster 47

MRI and Clinical Characteristics Associated with Growth or Complication of Cavernoma

Author(s) and Institution(s):
SY Sze[1], HS Leung[1], WH Hui[1], WC Law[1], TY So[2], NR Mahboobani[2], MH Lai[1], JM Abrigo[2]
[1]Department of Imaging and Interventional Radiology, Prince of Wales Hospital, Hong Kong SAR
[2]Department of Imaging and Interventional Radiology, Faculty of Medicine, The Chinese University of Hong Kong, Hong Kong SAR

Objectives:
To evaluate clinical and imaging characteristics of patients with cavernoma in local population, and correlation between these features with cavernoma growth or presence of symptoms.

Materials and methods:
Retrospective cohort study included patients with cavernoma on magnetic resonance imaging (MRI) performed between 2015 and 2016. Patients' demographics and attributable symptoms were recorded. Serial MRIs were reviewed for number, location, size, presence of T1-weighted (T1w) hyperintensity and other MRI characteristics. Lesion-based analysis was performed with up to three cavernoma per patient. Correlation of above parameters with significant growth of each lesion (defined as ≥10% and ≥2mm increase in size) were performed using Kaplan-Meier analysis and log-rank test. Comparison of baseline demographics and imaging features on initial MRI between patients with or without attributable symptoms by Mann-Whitney U test or Fisher's exact test (reported with odds ratios [OR] or 95% confidence intervals [CI]).

Results:
Using MRI performed between 2015 and 2016 as baseline, 69 patients had subsequent follow-up MRI with 88 cavernomas assessed for growth with median follow-up of 82.4 months. Cavernoma growth

was detected in 17.3% (12/69) patients and was associated with size ≥10mm on baseline scan (p=0.035), age <40 years (p=0.029), and T1w hyperintensity (p=0.049).
Analysis of 83 patients with initial MRI available around time of diagnosis showed 20.5% (17/83) patients were symptomatic upon presentation, including haemorrhage (n=9) and seizure (n=8); these are in patients of younger age (p=0.003), larger lesion size (p<0.001), brainstem location (OR 6.46, 95% CI 1.51-27.6, p=0.015) or T1w hyperintensity (OR 4.67, 95% CI 1.23-17.8, p=0.026). Of the remaining 66 patients who were asymptomatic on presentation, 12.1% (8/66) developed symptoms on follow-up at median duration of 2.73 years.

Conclusion:
Cavernoma growth is only observed in less than 20% of patients. Younger age, larger initial size and T1w hyperintensity were associated with both symptomatic presentation and lesion growth. Brainstem cavernoma was also associated with symptomatic presentation.

Poster 48

Quantitative 99mTc-PYP SPECT/CT at 180 Minutes: An Alternative Approach for Diagnostic Stratification in Transthyretin Cardiac Amyloidosis

Author(s) and Institution(s):
Tong THC, Chan KWG, Hui YH
Nuclear Medicine Unit, Department of Radiology, Queen Mary Hospital, Hong Kong SAR

Objectives:
While the semi-quantitative Perugini grading scale is currently the standard for diagnosing transthyretin cardiac amyloidosis (ATTR-CM) in 99mTc-Pyrophosphate (PYP) scintigraphy, it is limited by inter-observer variability and potential confounding from blood pool activity. This study evaluates the diagnostic utility of a quantitative approach, using myocardium-to-vertebra (M:V) and myocardium-to-rib (M:R) ratios derived from 180-minute SPECT/CT, as objective alternatives to the visual grading.

Materials and methods:
This retrospective, single-centre study analysed one year of clinical data from patients who underwent 99mTc-PYP scintigraphy for suspected ATTR-CM. Both planar and SPECT/CT images, acquired at 180 minutes post-injection, were reviewed for scintigraphically positive and negative cases. Quantitative myocardial uptake was calculated using M:V and M:R ratios. Statistical analyses were conducted to compare the quantitative ratios between the positive and negative cohorts and to assess their correlation with Perugini grades.

Results:
The 180-minute quantitative SPECT/CT analysis successfully stratified patients according to

myocardial radiotracer uptake. Calculated M:V and M:R ratios demonstrated statistically significant differences between scintigraphically positive and negative cases. Additionally, both quantitative ratios demonstrated a strong positive correlation with the visually assessed, semi-quantitative Perugini grades.

Conclusion:
Calculating M:V and M:R ratios from 180-minute 99mTc-PYP SPECT/CT offers a highly effective and objective alternative to the semi-quantitative Perugini grading scale. By reliably differentiating positive from negative cases and correlating closely with established visual grading, this quantitative approach minimises reader subjectivity and improves diagnostic stratification for patients with suspected ATTR-CM.

Poster 49

Comparison of radiation-induced cancer risks for Japan and Hong Kong adult patients from common whole-body PET/CT examinations in oncology

Author(s) and Institution(s):
Celina K W Li[1], Martin Law[1,2]
[1]Department of Clinical Oncology, Tuen Mun Hospital, Hong Kong
[2]Department of Radiology and Nuclear Medicine, Tuen Mun Hospital, Hong Kong

Objectives:
To estimate and compare the radiation-induced cancer risks for adult patients from the Japanese and Hong Kong populations undergoing two commonly used whole-body PET/CT examinations in oncology: (1) ^{18}FDG and (2) dual-tracer ^{18}FDG and ^{11}C-acetate PET/CT.

Materials and methods:
Organ absorbed doses from radiotracers and CT acquisitions were simulated using MIRDcalc and MIRDct software, respectively. Effective doses were calculated based on the ICRP-103 recommendations. Radiation-induced cancer risk in the form of lifetime attributable risk (LAR) of cancer incidence was estimated using the excess absolute risk model and excess relative risk model across specific cancer sites recommended in the BEIR VII report. To compare regional risks, organ-specific LARs of cancer incidence were calculated for adult male and female patients aged 20 to 80 at exposure in Japan and Hong Kong, using the respective national cancer statistics and life table. Calculations for both populations were standardized to 2020 statistics to align with Japan's latest available cancer incidence data.

Results:
LAR of cancer incidence depends on sex, age at exposure, and population. Data from both populations demonstrate that females exhibit a higher excess risk than males across most cancer sites, except the colon, liver, and leukemia. This risk is elevated at younger ages and decreases with advancing age. For a typical whole-body PET/CT protocol (120 kV, 200 mAs) on a commercial 64-slice CT scanner, a dual-tracer of 10 mCi ^{18}FDG and 10 mCi ^{11}C-acetate scan results in the LAR of total cancer incidence of

0.232% in Hong Kong and 0.249% in Japan for 60-year-old females, and 0.180% in Hong Kong and 0.203% in Japan for 60-year-old males. In comparison, using ^{18}FDG alone results in corresponding values of 0.167% and 0.180% for females, and 0.134% and 0.151% for males, respectively. Despite comparable life expectancies and lifestyle, Japan exhibits a higher risk than Hong Kong due to its significantly higher baseline cancer incidence rates.

Conclusion:
These region-specific LAR estimates can be a tool for optimizing clinical justification of PET/CT scan for cancer diagnosis and predicting PET/CT utilization in healthcare policy planning.

Poster 50

IMAGING CLUES TO DETECTING GYNAECOLOGICAL LYMPHOMA

Author(s) and Institution(s):
Christina C.T. Ng[1], Elaine Y.P. Lee[2]
[1]Department of Radiology, Queen Mary Hospital
[2]Department of Diagnostic Radiology, University of Hong Kong

Objectives:
To provide a pictorial review of primary and secondary gynaecological lymphoma, highlighting the multimodality radiological features at diagnosis and follow-up.

Materials and methods:
A retrospective review of female patients with histologically-confirmed gynaecological lymphoma of the ovaries, uterus, vagina, vulva or pelvic sidewall between 2010 and January 2026. Histology, as well as CT, PET-CT and MRI findings at diagnosis and follow-up were reviewed.

Results:
24 patients in total with histology-confirmed gynaecological lymphoma were reviewed, with diffuse large B-cell lymphoma (DLBCL) being the most common histological subtype. Primary gynaecological or pelvic lymphoma constituted nearly 40% of the cases, with the remaining cases categorised as secondary and indeterminate primary/secondary origin based on imaging findings. Common imaging findings include soft tissue mass or a diffusely enlarged organ without overt destructive features, coupled with FDG avidity on PET-CT where available.

Conclusion:
Imaging plays a vital role in guiding diagnosis prior to histological diagnosis, staging and disease monitoring. Overlaps between gynaecological lymphoma and epithelial carcinoma can create diagnostic uncertainty. However, awareness of key imaging features can help include or exclude gynaecological lymphoma as a differential diagnosis.

Poster 51

Ovarian teratoma: a pictorial review on imaging findings and complications

Author(s) and Institution(s):
CK Chan, OL Chan, WH Chong, KY Kwok
Department of Radiology & Nuclear Medicine, Tuen Mun Hospital, Hong Kong SAR

Objectives:
To highlight the imaging features of ovarian teratoma subtypes and their associated complications.

Materials and methods:
Cases of ovarian teratoma with imaging (USG or CT or MRI) performed during 1 Jul 2017 to 30 Jun 2026 were identified from RIS using keyword "teratoma". Cases other than ovarian teratomas were excluded. In addition, cases of pathologically proven ovarian teratoma during
the same period was obtained from the Department of O&G with imaging findings reviewed.

Results:
There are several subtypes of ovarian teratoma including mature teratoma, immature teratoma, struma ovarii and mixed germ cell tumour. The presence of macroscopic fat within a cystic ovarian mass or a fat-fluid level is almost diagnostic of a mature teratoma, which may also contain calcification or teeth. Immature teratomas are predominantly solid masses, with fat or calcification being less commonly detected or smaller compared with mature teratomas. Struma ovarii usually contains high density solid components with intense contrast enhancement. Mixed germ cell tumours can present as heterogenous masses and their diagnosis is often supported by elevated AFP and HCG levels.

Acute and oncological complications may occur with an ovarian teratoma, including rupture, torsion, malignant transformation, and gliomatosis peritonei. Torsion of an ovarian teratoma often demonstrates twisted ovarian vascular pedicle, enlarged ovary with peripheral
arrangement of follicles, and uterine deviation towards the twisted side. The presence of intraperitoneal fat lobules and a distorted cyst is pathognomonic of a ruptured ovarian teratoma. Malignant transformation is suggested by the presence of heterogeneously enhancing irregular solid components with or without locally invasive features, particularly in patients of older age or with larger lesions. Gliomatosis peritonei usually presents with peritoneal soft tissue nodules, for which pathological examination is required for definitive diagnosis.

Conclusion:
Ovarian teratoma demonstrate a wide range of imaging features and can present with acute and oncological complications. Timely imaging diagnosis is thus important to facilitate clinical management.

Poster 52

Hidden in Plain Sight: Vaginal Metastasis as the Initial Manifestation of Renal Cell Carcinoma

Author(s) and Institution(s):
CHEUNG Ka Yuet[1], HO Grace[1], LEE Elaine Yuen Phin[2]
[1]Department of Radiology, Queen Mary Hospital
[2]Department of Diagnostic Radiology, The University of Hong Kong

Objectives:
Vaginal and vulvar metastases from renal cell carcinoma (RCC) are extremely rare and can histologically mimic primary gynecologic clear cell malignancies. Initial vaginal biopsies can mislead clinicians and are prone to diagnostic pitfalls. If imaging is limited strictly to the pelvis, the true primary source will be missed. This case illustrates how comprehensive abdominopelvic MRI trumps initial histopathology by exposing a retrograde venous tumor thrombus pathway, ultimately guiding the correct systemic treatment. We demonstrate upper abdominal imaging is mandatory when staging atypical pelvic lesions.

Materials and methods:
Retrospective review of electronic health records was performed to review the clinical history, diagnostic workup, and imaging findings. Literature review established the prevalence and clinical presentation of vaginal metastases as the primary presentation of metastatic RCC.

Results:
A 69-year-old female patient who presented with a palpable vulvar mass. Initial biopsy slide review of the mass was interpreted by pathology as a high-grade carcinoma likely gynaecological origin. However, a subsequent staging and characterisation pelvic/abdominal MRI revealed a malignant right renal mass with associated renal venous thrombosis. Crucially, the MRI tracked a tumour thrombus extended retrograde down a dilated thrombosed right ovarian vein.
Literature review shows that vaginal metastasis from RCC predominantly manifests as disease recurrence. Primary presentation of vaginal mass from metastatic RCC is even rarer, with vaginal bleeding or palpable mass as typical presenting symptoms.

Conclusion:
Most primary vaginal cancers are squamous cell carcinoma, with primary adenocarcinoma comprising only 10% of vaginal neoplasms. This case highlights that while pathology is often considered the gold standard, it is blind to macro-vascular pathways. When evaluating atypical vaginal masses, radiology does not just support pathology—it leads the diagnosis. Combined upper abdominal and pelvic MRI is essential to trace macro-vascular pathways, catch occult renal primaries, override localized biopsy results when discrepant, and prevent consequential pathology-guided misdiagnosis.

Poster 53

The Role of Whole-Body MRI in Multiple Myeloma – A Single-institution Experience

Author(s) and Institution(s):
Muhammad Izzat Bin Mohd Hayazi, Chern Yue Glen Ong
Department of Radiology, Tan Tock Seng Hospital, Singapore

Objectives:
To review the role of whole-body magnetic resonance imaging (WBMRI) in multiple myeloma (MM) as practised in our institution, focusing on imaging manifestations, diagnostic utility, and performance relative to that of FDG PET/CT.

Materials and methods:
A case-based pictorial essay and selected literature review addressing WBMRI in MM, including studies comparing WBMRI and FDG PET/CT. Focal, diffuse and mixed marrow patterns were reviewed. The principles of diffusion-weighted imaging and Dixon techniques, the Myeloma Response Assessment and Diagnosis System (MY-RADS), and the imaging component of the SLiM-CRAB diagnostic criteria are discussed. Selected illustrative cases demonstrate areas of concordance and discordance between imaging modalities.

Results:
Contemporary WBMRI incorporating diffusion-weighted imaging demonstrates high sensitivity for focal and diffuse disease. Our experience concurs with published comparisons that report superior sensitivity of WBMRI compared to FDG PET/CT. This lends support to our current practise of utilising WBMRI as the primary modality for skeletal survey in suspected multiple myeloma. Although MY-RADS provides a framework for response assessment, blood and urine markers remain the mainstay for determining and monitoring treatment response.

Conclusion:
WBMRI provides a sensitive whole-body assessment of marrow disease and plays an increasing role in the modern imaging evaluation and treatment follow-up of MM.

Poster 54

Sonographic Evaluation of Testicular Masses: Pictorial Review of Primary Testicular Tumour and Benign Mimics

Author(s) and Institution(s):
Pui Man Yeung, Oi Ling Chan, Wing Ho Chong, Kai Yan Kwok
Department of Radiology and Nuclear Medicine, Tuen Mun Hospital, Hong Kong SAR

Objectives:
To illustrate sonographic features of primary testicular tumours—including seminomas, non-seminomatous germ cell tumours (NSGCTs), and lymphomas—and differentiate them from common benign mimics.

Materials and methods:
All scrotal ultrasounds performed at Tuen Mun Hospital, Pok Oi Hospital, and Tin Shui Wai Hospital (1 June 2016–30 June 2026) were retrospectively reviewed. Relevant cases were identified using keywords "mass" or "tumour". Clinical notes, sonographic findings, and histopathology or clinical follow-up records were evaluated.

Results:
In Hong Kong, testicular cancer accounts for <0.5% of male cancers but ranks among the top 5 malignancies in young males <44 years. Common primary tumours include seminomas, NSGCTs, and lymphomas. Germ cell tumours predominate in males aged 15–40 years (seminoma peaking at 30–40 years), whereas lymphoma predominates in men >50 years. Primary malignancies exhibited distinct signatures: seminomas presented as well-circumscribed, homogeneously hypoechoic, hypervascular masses; NSGCTs showed marked heterogeneity and microlithiasis (teratomas/yolk sac tumours showed solid-cystic architecture with calcifications; choriocarcinomas showed hypervascular mixed lesions with central necrosis/hemorrhage); and lymphomas displayed diffuse or multinodular hypoechoic replacement preserving testicular contour. Benign mimics showed key features: epididymo-orchitis demonstrated hypervascularity matching focal tenderness; segmental infarction appeared as a wedge-shaped avascular zone pointing to the mediastinum testis; and abscesses presented as complex fluid collections with a hypervascular rim and central avascularity.

Conclusion:
Ultrasound is a reliable first-line modality to differentiate primary testicular tumours from common benign mimics. Nevertheless, correlation with clinical presentation and interval follow-up imaging remains essential in cases of diagnostic uncertainty.

Poster 55

Multivendor comparison of quantification accuracy of effective atomic number between fast kVp-switching and twin-beam dual-energy computed tomography scanners: A phantom study

Author(s) and Institution(s):
KW Li[1], OL Chan[2], MC Mau[2], CY Yeung[2], WH Chong[2]
[1]Department of Clinical Oncology, Tuen Mun Hospital, Hong Kong
[2]Department of Radiology and Nuclear Medicine, Tuen Mun Hospital, Hong Kong

Objectives:
To evaluate the quantification accuracy of effective atomic number (Z_{eff}) across three commercial dual-energy computed tomography (DECT) scanners from three vendors, comprising two fast kVp-switching systems and one twin-beam system, and to assess how radiation dose levels and reconstruction algorithms impact this accuracy.

Materials and methods:
An elliptical Multi-Energy CT phantom (Sun Nuclear) consisting of various material inserts, including water, iodine, and soft-tissue- and bone-equivalent materials, was scanned using three DECT scanners: GE Revolution CT (fast kVp-switching) at 80/140 kVp, United Imaging uCT 820 (fast kVp-switching) at 80/140 kVp and Siemens SOMATOM Definition Edge (twin-beam) at 120 kVp with gold (Au) and tin (Sn) filters. A standard dual-energy abdominal protocol was employed with the acquisition parameters adjusted to achieve four incremental dose levels ($CTDI_{vol}$ = 5, 10, 15, and 20 mGy). Images were reconstructed using filtered back projection and iterative reconstruction of medium strength with standard reconstruction kernel. Mayneord's power-law formula was used to calculate the theoretical Z_{eff} of 14 inserts based on their elemental compositions as the ground truth.

Results:
At a $CTDI_{vol}$ >= 10 mGy, the mean Z_{eff} error ranges for GE Revolution CT, United Imaging uCT 820, and Siemens SOMATOM Definition Edge were [-0.12%, 10.87%], [-9.95%, 7.89%], and [-22.18%, -1.79%], respectively. Decreasing the $CTDI_{vol}$ to 5 mGy increased the mean Z_{eff} errors across all three scanners, whereas the choice of reconstruction algorithm had no impact on Z_{eff} accuracy.

Conclusion:
Z_{eff} accuracy varies significantly between vendors and scanning methods. Fast kVp-switching DECT offers better Z_{eff} accuracy compared to twin-beam DECT, which suffers from limited spectral separation. Consequently, selecting an optimal DECT scanner can enhance diagnostic accuracy for specific clinical applications. However, differentiating materials with highly similar Z_{eff}, such as subtypes of non-uric acid renal stones, remains a clinical challenge.

Poster 56

Unfolded Rib Computed Tomography (URCT): A pictorial review of common rib pathologies, advantages, and technical limitations.

Author(s) and Institution(s):
Ho Man To Jason[1], Yeung Tsz Wai[1], Fung Sin Yue Cindy[1], Wong Hei Tung Jamie[1], Archie Bill Lo[1], Hon Yu Wai[1], Chan Wai Yee[1], Lam Cheuk Kwan[1], Li Jing Woei[1]
[1]Department of Diagnostic Radiology, Tseung Kwan O Hospital, Hong Kong SAR

Objectives:
Evaluation of all 24 ribs on conventional axial CT is often challenging and time-consuming due to rib curvature. URCT is an advanced processing technique that flattens the rib cage into a single panoramic 2D plane, allowing rapid and systematic assessment. This pictorial review illustrates the typical appearance of common rib lesions on URCT and discusses its advantages and potential pitfalls.

Materials and methods:
We retrospectively reviewed thoracic CT at Tseung Kwan O Hospital from 1st of August 2023 to 1st of August 2026. Using the radiology information system, studies with the keyword "rib" were identified, and those with rib pathology were processed with Siemens Healthineer automated rib-unfolding software. Representative cases on axial CT and UR CT were selected to illustrate a spectrum of common rib conditions. Imaging features were summarized, and the strengths and pitfalls of URCT were analyzed.

Results:
A total of 341 cases were identified: 190(55.7%) traumatic, 88(25.8%) benign, and 63(18.5%) malignant rib conditions were acquired. URCT reliably and efficiently depicted a range of rib conditions on single panoramic images.
Advantages include:
1.Time efficiency: reduced image evaluation and reading time.
2.Automated rib labelling: eliminated tedious manual rib counting.
3.Easy screening: rapid screening of the ribcage for acute pathologies at a glance.
Limitations include:
1.Reconstruction artefact: folding errors can produce missing rib, discontinuities or misplaced segments.
2.Loss of 3D spatial context: flattening can distort shape and spatial relationships, hindering assessment with adjacent structures and extra-osseous lesions.
3.Reduced diagnostic conspicuity: subtle cortical irregularities, periosteal reactions, and small lytic lesions may not be visible on URCT.

Conclusion:
UR CT is a valuable adjunct for rapid and systematic review of the rib cage, but it should complement conventional axial and multiplanar reformats due to its reconstruction and interpretative limitations.

Poster 57

Three-Dimensional CT Volumetry for Predicting Node-Specific Pathological Response after Neoadjuvant Therapy in Lung Cancer

Author(s) and Institution(s):
Zhebing Lin[1], Hanxiao Zhang[2], Mario Pezzella[3], Dominik V. Flury[4,5], Yuyao Zhu[6], Xinghua Cheng[1]
[1]Department of Oncology, Shanghai Chest Hospital, Shanghai Jiao Tong University School of Medicine, Shanghai, China
[2]Institute of Medical Robotics, Shanghai Jiao Tong University, Shanghai, China
[3]Thoracic Surgery Unit, Department of Cardiac, Thoracic and Vascular Sciences and Public Health, University of Padua, Padua, Italy
[4]Department of Thoracic Surgery, Shanghai Chest Hospital, Shanghai Jiao Tong University School of Medicine, Shanghai, China
[5]Department of Thoracic Surgery, St. Claraspital, University Hospital Basel, University of Basel, Basel, Switzerland
[6]Department of Anesthesiology, Shanghai Chest Hospital, Shanghai Jiao Tong University School of Medicine, Shanghai, China

Objectives:
We assessed 3D CT volumetric regression of biopsy-proven metastatic lymph nodes for predicting **node-specific pathological response (nsPR)** after neoadjuvant therapy, compared with conventional diameter-based measurements, and developed a multivariable model.

Materials and methods:
We retrospectively included 144 patients with biopsy-confirmed nodal metastasis treated with neoadjuvant therapy followed by surgery from 2021 to 2023, with one target node per patient. If multiple biopsy-proven nodes were present, the node with the largest CT short-axis was selected. The target node underwent repeat biopsy after treatment. **nsPR required concordant absence of residual tumour on repeat biopsy and surgical pathology**; discordant cases were classified as non-nsPR. Pre- and post-treatment contrast-enhanced CT underwent automated 3D segmentation with manual correction. Changes in nodal volume, 2D/3D diameters, primary-tumour long-axis diameter, and serum tumour markers were analysed. Logistic regression with variable selection identified independent predictors, followed by 1,000-bootstrap internal validation.

Results:
Among 144 target nodes, 89 met nsPR criteria and 55 were non-nsPR. nsPR nodes showed greater reductions in nodal volume (64.06% vs 31.23%), 2D long-axis diameter (37.68% vs 10.89%), 2D short-axis diameter (39.79% vs 13.91%), and primary-tumour long-axis diameter (51.72% vs 24.24%; all $p<0.001$). Although multiple nodal diameter measures were significant on univariable analysis, nodal volume reduction remained in the final multivariable model with primary-tumour long-axis and CYFRA21-1 reductions (OR 1.046 per percentage-point increase; 95% CI 1.026–1.070;

p<0.001). Nodal volume reduction alone achieved an AUC of 0.8178 (95% CI 0.7479–0.8876). **The combined model achieved an AUC of 0.8787 (95% CI 0.8191–0.9382)**, with 86.51% sensitivity and 72.72% specificity. Calibration was satisfactory.

Conclusion:

3D CT volumetry may provide a more comprehensive assessment of nodal treatment response than conventional diameter-based measurements. Combining nodal volumetric regression with primary-tumour shrinkage and CYFRA21-1 provides accurate, clinically interpretable prediction of nsPR.

Poster 58

Artificial Ascites During Microwave Ablation of Hepatocellular Carcinoma: A Practical Guide from a Tertiary Interventional Oncology Centre

Author(s) and Institution(s):

Yueyang Tian[1], Wa Cheung[1], Bruno Di Muzio[1,2]

[1]Department of Radiology, Alfred Hospital, Bayside Health, Melbourne, Victoria, Australia

[2]Department of Surgery, Monash University School of Clinical Sciences, Melbourne, Victoria, Australia

Objectives:

To review the role of Artificial Ascites (AA) as a thermoprotective adjunct during microwave ablation (MWA) of hepatocellular carcinoma (HCC) in anatomically challenging locations and to demonstrate a simplified single-step ultrasound-guided technique for establishing AA.

Materials and methods:

AA facilitates thermal ablation of HCCs adjacent to critical structures by creating separation between the liver and surrounding viscera, reducing the risk of thermal injury while improving sonographic visualization. This exhibit reviews the current evidence supporting AA, discusses indications, contraindications, and technical limitations. Unlike most guidewire-assisted techniques, we present a practical single-step technique using direct ultrasound-guided placement of a 6.3 Fr Dawson-Mueller catheter. The procedural workflow is illustrated with representative cases, highlighting technical tips, common pitfalls including perihepatic adhesions and inadequate hydrodissection, and troubleshooting strategies.

Results:

AA is established under ultrasound guidance, favouring a left lobe or gallbladder/segment V window where feasible for broad peritoneal access while avoiding bowel. Using the liver capsule, gallbladder, or gastric wall as landmarks, a 6.3 French Dawson-Mueller catheter is advanced directly into the perihepatic space without guidewire exchange. Correct positioning is confirmed by visualization of the catheter tracking along the liver capsule with subsequent free distribution of infused sterile saline

around the liver. The end point is the creation of a continuous fluid layer with displacement of adjacent viscera confirmed on before-and-after images, providing both thermal protection and an improved acoustic window for MWA.

Conclusion:
AA is a safe and effective thermoprotective adjunct that enables MWA of anatomically high risk HCCs. The described single-step technique provides a simple, efficient, and reproducible approach to AA creation that reduces procedural complexity while maintaining safe and effective hydrodissection.

Poster 59

Initial Local Experience with the Contour Neurovascular System for MCA Bifurcation Aneurysms

Author(s) and Institution(s):
Chun Kit Richard Chan[1], Cherry Cheuk Yan Chan[2], Lok Hang Yeung[2], Danny Hing Yan Cho[2]
[1]Department of Radiology and Organ Imaging, United Christian Hospital, Hong Kong SAR
[2]Department of Diagnostic & Interventional Radiology, Kwong Wah Hospital, Hong Kong SAR

Objectives:
Intrasaccular flow-disrupting devices treat saccular bifurcation aneurysms, commonly at the middle cerebral artery (MCA) bifurcation, internal carotid artery (ICA) terminus, anterior communicating artery complex, and basilar apex. The Woven EndoBridge is typically sized to occupy the sac; Contour instead covers the neck rather than filling the sac, preserving parent and branch vessels. We report our initial local experience using Contour for MCA bifurcation aneurysms of differing neck configurations.

Materials and methods:
We retrospectively reviewed patients treated with Contour at Kwong Wah Hospital in 2026, recording aneurysm morphology, device sizing, technique, complication and angiographic outcomes.

Results:
Two patients with unruptured MCA bifurcation aneurysms were treated.

Case 1 (N2.2mm, D5.0mm, H2.9mm): Straight-tipped microcatheter cannulation was unstable at the bifurcation. Steam-shaping the tip improved stability, enabling deployment of a 5mm Contour device at the neck. Angiography showed satisfactory position, patent M2 divisions, and intrasaccular contrast stasis.

Case 2 (N4.3 mm, D4.6 mm, H7.8mm; superior M2 incorporated at the neck): After deploying a 9mm Contour device, reduced opacification of the superior M2 raised concern for branch compromise. A parallel microcatheter was kept in the branch, and a Neuroform Atlas stent was deployed from the

superior M2 to M1 as salvage. Angiography showed restored M2 opacification with intrasaccular contrast stasis.

Conclusion:
In our initial local experience, Contour was technically feasible for selected MCA bifurcation aneurysms, achieving immediate intrasaccular contrast stasis while preserving daughter-branch flow. Microcatheter stability is a key technical consideration, while branch incorporation at the neck represents a higher-risk configuration in which device deployment may affect branch inflow. Rigorous pre-procedural assessment, careful case selection, and contingency planning are therefore essential. If post-deployment angiography shows reduced branch opacification, parallel branch catheterisation with adjunctive stenting may provide an effective rescue strategy. Follow-up imaging will assess occlusion durability.

Poster 60

Lymphangiographic Anatomy for Intervention: A Practical Case-Based Pictorial Review

Author(s) and Institution(s):
Dr. Janet Wong Hin Man, Dr. Alan YM Chong, Dr. Wisely HH Tang, Dr. John CY Chan, Dr. Dr. Kelvin KH Choi
Department of Raidology, Queen Mary Hospital, Hong Kong SAR

Objectives:
To provide a practical, case-based pictorial review of lymphatic anatomy encountered during intranodal and upper-limb lymphangiography, emphasizing anatomical landmarks, variants, and access routes relevant to contemporary lymphatic intervention.

Materials and methods:
A retrospective single-centre pictorial review of lymphangiographic procedures was performed. Selected fluoroscopic and cone-beam CT/DynaCT cases demonstrated intranodal access, pelvic and retroperitoneal lymphatic pathways, cisterna chyli, thoracic duct, terminal lymphovenous drainage, retrograde thoracic duct access, and right upper-limb lymphatic drainage.

Results:
The selected cases demonstrate the lower-body central lymphatic roadmap from inguinal nodal access to the left lymphovenous junction. Early images confirm correct intranodal needle placement and opacification of efferent lymphatic channels. Progressive contrast ascent demonstrates pelvic lymphatic pathways and transition to retroperitoneal/lumbar lymphatic trunks.

The exhibit will illustrate the cisterna chyli as a key central lymphatic landmark and highlight its range of appearances and anatomical variation on lymphangiography. The thoracic duct component will demonstrate its course through the posterior mediastinum and terminal drainage into the left subclavian vein or left lymphovenous junction.

Retrograde access cases show left upper-limb venous access, selective engagement of the thoracic duct termination, and caudal catheter advancement toward the lower thoracic duct/cisterna chyli. A right upper-limb lymphangiographic case demonstrates drainage through the right axillary and subclavian lymphatic pathways toward the right jugulosubclavian venous region, illustrating the anatomically distinct right upper-quadrant lymphovenous drainage route.

Conclusion:
Lymphangiography provides dynamic, procedure-relevant depiction of peripheral and central lymphatic anatomy. This educational exhibit will illustrate key landmarks from inguinal nodal access to the cisterna chyli, thoracic duct, and left lymphovenous junction, with emphasis on variable cisterna chyli appearances, terminal drainage, and alternative retrograde access routes.

Poster 62

Straight to the Point: Techniques, Feasibility, and Safety of Single-Stick Tunneled Central Venous Catheter Insertion in Adults

Author(s) and Institution(s):
Lester WH Shiu
Department of Radiology, Pamela Youde Nethersole Eastern Hospital, Hong Kong

Objectives:
Tunneled central venous catheter (CVC) insertion—frequently required for chemotherapy, hemodialysis, and long-term intravenous therapies—is a common interventional procedure performed by Interventional Radiologist (IR). The traditional technique typically requires separate sites: one for initial venous access and a secondary site or incision for creating the subcutaneous tunnel. While the single-stick technique has gained popularity in pediatric populations for offering lower infection rates, improved cosmetic outcomes, and shorter procedure times, its feasibility and safety in adult patients remain less well-established.

This study describes the techniques and assesses the safety and feasibility of tunneled central venous catheter placement using a single-stick technique in adult patients.

Materials and methods:
A retrospective search of the Radiology Information System (RIS) and Picture Archiving and Communication System (PACS) was conducted over a 6 months period (March 2026 to August 2026). Technical details of tunnelled central venous catheter insertions, technical success rates, and safety profiles were retrospectively analyzed.

Results:
A total of 51 tunneled central venous catheters were inserted during the study period, comprising 48 cases utilizing the traditional double-stick technique and 3 cases utilizing the single-stick technique

(including 2 Hickman catheters and 1 hemodialysis catheter). The overall technical success rate for the single-stick cohort was 100% (3/3). No procedural complications were observed.

Conclusion:
The single-stick technique is a safe and feasible approach for tunneled central venous catheter placement in adult patients, with the potential to reduce infection rates and shorten procedure times. Further large-scale studies are warranted to validate its broader clinical utility.

Poster 63

Management of Lower Limb Pseudoaneurysms from an IR Perspective: A Single-Centre 6-Year Clinical Experience

Author(s) and Institution(s):
CK Chan[1], James K Fung[1], SY Leung[1], CK Li[1], Lester WH Shiu[1], Kevin H Chin[1]
[1]Department of Radiology, Pamela Youde Nethersole Eastern Hospital, Hong Kong SAR

Objectives:
To primarily evaluate the effectiveness and safety of image-guided(percutaneous/endovascular) treatments in lower limb pseudoaneurysms(PSAs), with a secondary focus on reperfusion risk factors and the differential success rates between applied treatments.

Materials and methods:
All symptomatic or large(>2cm) PSAs receiving image-guided treatments were retrospectively retrieved from RIS and PACS over a 6-year period(Aug2020-Jul2026). The etiology spectrum, clinical setting, technical specifications and safety profiles were analyzed.

Results:
The cohort included 29 PSAs in 29 consecutive patients, featuring iatrogenic(93.1%,n=27), traumatic(3.4%,n=1), and unknown(3.4%,n=1) causes, distributed around the groin in the majority(89.7%,n=26) of cases(vs thigh 10.3%,n=3). Iatrogenic etiologies often involved the use of large-bore vascular sheaths(≥6 Fr) and most(75.9%,n=22) were associated with underlying impaired hemostasis.
The median aneurysmal size and neck diameter were 24mm(6-46mm) and 2.2mm(1-5mm) respectively. 2 cases had a wide neck(>3mm). None had a sac size ≥5cm or multilobed complex appearance.
The PSAs were treated with thrombin in 82.8%(n=24) and with glue in 17.2%(n=5). Hybrid US/fluoroscopy was used to guide thrombin injection in 1 case, glue embolization in 2 cases. Balloon assisted occlusion was used in 1 glue embolization case.
Technical success(immediate intra-saccular flow cessation) was achieved in 100%(n=29). 1 recurrence occurred 3 days following thrombin injection for a post-thrombectomy PSA in a patient receiving thrombolytics and anticoagulation; subsequent hybrid imaging identified an additional branch vessel supply which was controlled with glue embolization. This resulted in a primary clinical success rate of

96.6% and an overall secondary clinical success rate of 100%. Satisfactory overall safety profile over a median follow up of 4.1 wks(1-16 wks), with 1 minor complication of a secondary access-site PSA. Intended secondary analyses were limited by the small sample size in corresponding minor subgroups.

Conclusion:
Image-guided management of lower limb PSAs with thrombin or glue proved safe and effective despite recognized reperfusion risk factors in most cases.

Poster 64

Splenic Artery Embolization in Blunt Splenic Trauma: A Review of Evidence and Experience at a High-Volume Australian Level 1 Trauma Centre

Author(s) and Institution(s):
Yueyang Tian[1], Fatimath Zaha Ikram[1], Gerard S. Goh[1,3], Matthew Lukies[1,2,3]
[1]Department of Radiology, Alfred Hospital, Bayside Health, Melbourne, Victoria, Australia
[2]Department of Medical Imaging, Monash Health, Melbourne, Victoria, Australia
[3]Department of Surgery, Monash University School of Translational Medicine, Melbourne, Victoria, Australia

Objectives:
This presentation reviews imaging findings and grading systems for blunt splenic trauma, and synthesises literature and institutional experience from a major Australian trauma centre on the indications, efficacy and practice of splenic artery embolization (SAE).

Materials and methods:
The spleen is the most commonly injured solid organ in blunt abdominal trauma. Given its haematological and immunological importance, management has shifted from splenectomy towards splenic preservation. SAE is a minimally invasive endovascular procedure that reduces splenic arterial pressure to promote physiological haemostasis while preserving splenic function. The revised 2018 American Association for Surgery of Trauma (AAST) Organ Injury Scale incorporates parenchymal and vascular injury to guide management. Significant heterogeneity exists regarding whether SAE should be performed prophylactically (pSAE) by injury grade or reserved for salvage. At our institution, a multidisciplinary protocol considers pSAE for AAST grade IV-V injuries and grade III with significant haemoperitoneum. Proximal, distal and tandem embolization approaches and technique are described.

Results:
SAE demonstrates technical success rates exceeding 95% and splenic salvage rates of 92-97%. At our institution, 85% of splenic injuries are managed non-surgically, of which 38% undergo SAE and 3% require splenectomy after initial SAE. Our retrospective data also support the safety of SAE in haemodynamically unstable patients responsive to initial resuscitation, achieving 98% salvage rate with no significant mortality difference versus upfront splenectomy. Long-term follow-up at a median of

8.5 years post-embolization demonstrated preserved immune function via IgM memory B cell levels. Recognised complications, including post-embolization syndrome, rebleeding, infarction and abscess, are discussed alongside recommended post-procedural care.

Conclusion:
SAE is an effective, evidence-based alternative to splenectomy in high-grade blunt splenic injury, with multiple benefits over surgery. Further expansion of outcomes in pSAE, haemodynamically unstable patients, and long-term splenic function will inform guideline development and practice.

Poster 65

Evaluation of Safety and Efficacy of Bronchial Artery Embolization Using NBCA-Glue for Patients with Hemoptysis: A Single Center Experience

Author(s) and Institution(s):
Wu Lap Yin[1], Pan Nin Yuan[1], Ng Fung Him[1], Wong Ka Hon Stephen[1], Wong Ho Lim[1], Stephanie Cheri Woo[1], Kwok Hoi Ming Kenneth[1], Cheng Lik Fai[1]
[1]Department of Radiology, Princess Margaret Hospital, Hong Kong SAR

Objectives:
Bronchial artery embolization (BAE) is a critical, life-saving intervention for managing massive hemoptysis. While particulate agents are commonly used, N-butyl cyanoacrylate (NBCA) glue provides rapid, permanent occlusion of target vessel with capability to embolize even small-diameter vessels. However, concerns remain regarding its technical complexity and risk of ischemic complications especially spinal cord infarction. This study evaluates the technical success, clinical efficacy, and safety profile of NBCA-glue for BAE in patients with hemoptysis at a single institution.

Materials and methods:
We retrospectively reviewed data from 21 consecutive patients who underwent BAE using NBCA-glue for hemoptysis at our center between 01 Jan 2018 and 31 May 2026. NBCA was mixed with iodized oil (Lipiodol) at varying ratios (from 1:4 to 1:2). Technical success was defined as complete angiographic occlusion of target vessels. Clinical success was defined as the immediate cessation of hemoptysis within 24 hours post-procedure. Recurrence rates and procedural complications were evaluated during a median follow-up period of 14 months.

Results:
A total of 26 bronchial arteries in 21 patients were embolized using NBCA. The technical success rate was 100%, and the immediate clinical success rate was 100%. During the follow-up period, recurrent hemoptysis occurred in 23.8% of patients (5/21) at a median time of 6 months. Of the recurrent cases, only 1 of them required re-intervention at 36 months after the initial embolization, and rest of them resolved with medical treatment. Minor complications occurred in 4.7% (1/21) of cases, which

manifested as transient pleuritic chest pain resolved with analgesics. No major complications, such as spinal cord infarction, bronchial wall necrosis, or non-target systemic embolization, were observed.

Conclusion:
Bronchial artery embolization using NBCA-glue is a highly effective and safe treatment option for patients with hemoptysis. It offers excellent immediate technical and clinical success rates, alongside a favourable safety profile.

Poster 66

Central venous recanalisation: a pictorial review on tips and tricks

Author(s) and Institution(s):
YM Chong[1], JCY Chan[1], K Choi[1]
[1]Department of Radiology, Queen Mary Hospital, Hong Kong SAR

Objectives:
Central vein stenosis and occlusion arise from diverse causes, ranging from extrinsic compression to local venous injury related to indwelling devices. These lesions can produce significant symptoms and are often amenable to endovascular treatment. This pictorial review aims to highlight adjunctive measures that increase the success of recanalisation of central venous stenosis/occlusion, from the diagnostic imaging perspective to the choice of devices and techniques for intervention.

Materials and methods:
We retrospectively reviewed cases from our institution to identify illustrative examples demonstrating the benefit of diagnostic imaging and adjunctive interventional techniques that improved procedural planning and technical success in crossing critically stenotic or occluded central veins. Cases were selected to illustrate the complementary role of imaging in assessing the extent of central venous occlusion and adjunctive measures in recanalisation of central vein.

Results:
This pictorial review illustrates the complementary role of cross-sectional imaging and conventional contrast venography in assessing the degree of central venous occlusion and in procedural planning for recanalisation. Conventional and advanced techniques for establishing central vein recanalisation, from crossing catheters, rendezvous procedure and the use of intravascular ultrasound, are presented as means to improve the technical success rate of central venous recanalisation.

Conclusion:
Central vein stenosis/occlusion pose significant morbidity to patients and can often be treated effectively by endovascular recanalisation. We discuss strategies from pre-procedural planning to interventional techniques that help improve technical success in challenging cases, with the goal of achieving sustainable and favourable patient outcomes.

Poster 67

Artificial Pleural Effusion for Microwave Ablation of Hepatic Dome Tumours: A Single-Centre Experience

Author(s) and Institution(s):
CHAN Ka Yu, CHIN Hoi Kevin
Department of Radiology, Pamela Youde Nethersole Eastern Hospital, Hong Kong SAR

Objectives:
To evaluate local experience with artificial pleural effusion (AP) for percutaneous ultrasound (US)-guided microwave ablation (MWA) of hepatic dome tumours at a local tertiary centre, focusing on technical feasibility, lesion visualization, local tumour control, and safety outcomes.

Materials and methods:
Search of "artificial pleural effusion" in Radiology Information System was performed from 1 July 2025 to 30 June 2026. Cases are retrospectively reviewed for technical success rate, and whether enhanced visibility and alternative safe percutaneous window can be achieved after AP. Complications are graded according to the SIR Classification System. Follow-up period and local treatment outcome are also recorded.

Results:
Six patients with primary hepatocellular carcinoma or liver metastases located in subdiaphragmatic segments (S7, S8, S7/S8) underwent AP-assisted MWA over a 12-month period. Creation of AP was achieved in all patients (6/6, with a technical success rate of 100%). Enhanced visualization of tumour is observed in 6/6 (100%) of patients. Alternative percutaneous access was feasible in 3/6 (50%) of patients, allowing a percutaneous path without major blood vessels.
One minor complication occurred (1/6, 16%; SIR Grade B) due to delayed post-procedural pneumothorax, which was treated with percutaneous drainage and resolved within 1 day. No intra-operative desaturation or haemothorax. No major complication was observed.
Median follow-up period with CT is 1–2 months (median 1 month). All patients achieved complete response according to RECIST 1.1 criteria. No local recurrence is observed in the follow-up period. Pleural fluid spontaneously reabsorbed within 1 week in all patients.

Conclusion:
Artificial pleural effusion appears to be a safe and effective procedure to allow percutaneous MWA of right liver dome lesion. Further large-scale study could be considered with longer follow-up period.

Poster 68

Treating Unicameral Bone Cysts under Fluoroscopy: A Technical Pictorial Review of Aspiration and Intralesional Steroid Injection

Author(s) and Institution(s):
KDD Leung[1]
[1]Department of Diagnostic and Interventional Radiology, Queen Elizabeth Hospital, Hong Kong SAR

Objectives:
Unicameral bone cysts (UBCs), also termed simple bone cysts (SBCs), are benign fluid-filled osteolytic lesions that occur predominantly in children and adolescents, with a male predominance. They most commonly arise in the metaphysis of the proximal humerus and proximal femur, where progressive cortical thinning may predispose to pathological fracture. UBCs account for approximately 3% of biopsied bone tumours, and around 85% occur in children and adolescents.

Management ranges from observation for low-risk lesions to percutaneous injection therapies, mechanical decompression, curettage with grafting, and internal fixation for structurally high-risk lesions. Intralesional methylprednisolone acetate injection is an established minimally invasive option; it may be used alone or as part of a staged approach, although repeat procedures are frequently required and reported healing rates vary because of heterogeneity in technique, lesion characteristics, and outcome definitions.

This pictorial review describes the fluoroscopic-guided technique of cyst aspiration and intralesional methylprednisolone acetate injection in UBCs, highlighting procedural planning, dual-needle access, morphology, technical endpoints, and serial radiographic assessment of healing or the need for repeat intervention.

Materials and methods:
A retrospective review and case illustration of patients with UBCs treated by fluoroscopic-guided aspiration and intralesional steroid injection in our institution. Pre-procedure imaging, procedural and adjunct techniques, and serial radiographic appearances are presented as a pictorial review.

Results:
Dual-needle technique facilitated aspiration, lavage, pressure control, and assessment of intracystic communication during the procedure. No immediate major procedure-related complication occurred. Serial radiographic assessment of healing reviewed. Repeat intervention was performed in one case due to interval enlargement of cyst cavity.

Conclusion:
This pictorial review highlights practical technical considerations for radiologists performing image-guided UBC treatment.

Poster 69

Beyond the Basics: A Pictorial Essay of Advanced Percutaneous Vertebral Augmentation Techniques

Author(s) and Institution(s):
FCT Yip[1], HL Wong[2], NY Pan[2]
[1]Department of Radiology & Nuclear Medicine, Tuen Mun Hospital, Hong Kong SAR
[2]Department of Radiology, Princess Margaret Hospital, Hong Kong SAR

Objectives:
Vertebral augmentation procedures are minimally invasive, image-guided interventions designed to restore mechanical stability and alleviate pain in compromised spinal segments. Traditionally utilized as vertebroplasty or balloon kyphoplasty for osteoporotic, traumatic, or neoplastic compression fractures, these techniques have evolved to manage complex spinal hardware failures. A prime example is periprosthetic cementoplasty, used to stabilize interbody fusion cage subsidence into weakened endplates. Across all applications, the core biomechanical goals remain identical: the targeted delivery of polymethyl methacrylate (PMMA) bone cement to achieve rapid pain relief, immediate rigid segment stabilization, and the prevention of progressive spinal deformity or construct migration.

Materials and methods:
A retrospective review was conducted of patients who underwent percutaneous vertebral augmentation procedures at Princess Margaret Hospital, Hong Kong SAR, between 2025 and 2026. Relevant cases were identified utilizing the hospital's electronic patient record database, and post-procedural imaging findings were evaluated to assess structural outcomes.

Results:
Percutaneous vertebral cementation is a highly versatile, image-guided intervention that utilizes high-viscosity polymethyl methacrylate (PMMA) to restore mechanical stability and alleviate severe pain in compromised spinal segments. This clinical spectrum includes standard vertebroplasty, balloon kyphoplasty for height restoration in acute vertebral compression fractures (VCFs), and advanced periprosthetic cementoplasty. The latter is an emerging salvage technique specifically deployed to manage interbody fusion cage subsidence by targeted delivery of PMMA into the compromised bone-implant interface to halt further hardware migration.

Conclusion:
Ultimately, polymethyl methacrylate (PMMA) cementation remains an indispensable, versatile tool in the interventionalist's arsenal, offering customizable, minimally invasive solutions that restore immediate mechanical stability and provide rapid pain relief across a diverse spectrum of structural spinal pathologies.

Poster 70

Endovascular Embolization of Chest Wall Elastofibroma with Spontaneous Bleeding: Case Report & Literature Review

Author(s) and Institution(s):
Wong Hei Tung Jamie, Salimin Lisley, Lo Bill Archie, Fung Sin Yue Cindy, Ho Man To Jason, Li Jing Woei, Lam Cheuk Kwan
Department of Radiology, Tseung Kwan O Hospital, Hong Kong SAR

Objectives:
We repot a rare case of elastrofibroma dorsi presenting with spontaneous bleeding. Elastofibroma dorsi is a benign soft tissue tumour located in the infra or subscapular region where surgical treatment is rarely indicated unless the lesion is enlarging and symptomatic. To our knowledge, there have been no previously reported cases presenting with spontaneous bleeding.

Materials and methods:
Retrospective review of a rare case of elastofibroma with spontaneous bleeding treated with endovascular embolization. Representative pre-procedural and procedural images are selected for demonstration.

Results:
A 79 year-old lady on anticoagulation therapy (low molecular heparin) presented with severe spontaneous chest wall ecchymosis, transfusion-refractory anemia and subsequent hypovolemic shock, warranting an urgent endovascular embolization.

Pre-procedural CT imaging revealed bilateral elastofibroma dorsi along the posterior chest walls. The culprit lesion was associated with a massive hematoma extending from the T3 to T11 vertebral levels, exhibiting active contrast extravasation but no identifiable culprit artery, while the contralateral side remained indolent.

A left subclavian arteriogram was performed via right transfemoral approach. Super-selective Gelfoam (EGgel) embolization of the left thoracodorsal arterial branch supplying the elastofibroma achieved technical success. No procedure-related complications were reported.

Conclusion:
This case highlights a rare case of elastofibroma dorsi presenting with bleeding, which was successfully managed with endovascular Gelfoam embolization. Radiologists should maintain a high index of suspicion in the appropriate clinical setting and consider diagnostic angiogram to guide optimal management.

Poster 71

A microfluidic system enhances the culture of biliary exfoliated tumor cells from PTCD drainage

Author(s) and Institution(s):
Shenbo Zhang[1], Jie Tang[2], Kui Zhao[1], Zhonghe Zhao[1], Zhengyu Jin[1], Zhiwei Wang[1], Rui Chen[2], Sihang Cheng[1]
[1]Department of Radiology, Peking Union Medical College Hospital, Chinese Academy of Medical Sciences & Peking Union Medical College, Beijing 100730, China
[2]Clinical Pharmacology Research Center, State Key Laboratory of Complex Severe and Rare Diseases, NMPA Key Laboratory for Clinical Research and Evaluation of Drug, Beijing Key Laboratory of Clinical PK & PD Investigation for Innovative Drugs, Peking Union Medical College Hospital, Chinese Academy of Medical Sciences & Peking Union Medical College, Beijing 100730, China

Objectives:
This study aimed to validate the necessity and feasibility of isolating exfoliated biliary cells using a microfluidic system prior to downstream culture.

Materials and methods:
The inhibitory effect of bile on tumor cell proliferation was assessed using PANC-1 cells co-incubated with bile from four donors, followed by Cell Counting Kit-8 assay for cell viability. The isolation efficiency of the microfluidic system was compared with conventional PBS washing using PANC-1-spiked bile samples. Patients undergoing percutaneous transhepatic cholangial drainage were prospectively enrolled. Exfoliated cells were isolated via the microfluidic system and subjected to either 2D culture or patient-derived organoid (PDO) development. To confirm the malignant origin of cultured cells, seven established PDOs were subcutaneously injected into NVSG immunodeficient mice (n = 3 per PDO).

Results:
Bile inhibited PANC-1 proliferation in a concentration-dependent manner, with marked inter-donor variability. The microfluidic system achieved superior bile sludge removal compared to PBS washing. In the 2D culture cohort (n = 105), the overall culture positivity rate was 59.0% (62/105). In the PDO cohort (n = 41), the overall culture positivity rate was 85.4% (35/41), of which four were positive but contaminated. All seven transplanted PDOs successfully formed subcutaneous tumors in immunodeficient mice.

Conclusion:
The microfluidic system effectively isolates exfoliated biliary cells by removing inhibitory bile components while maintaining cell viability. The cultured cells are confirmed to be of malignant origin, supporting the potential of this approach for downstream functional studies and personalized medicine applications.

Poster 72

A Novel Therapeutic Approach for Dialysis-Refractory Hypotension in Massive ADPKD via Salvage Renal Artery Embolization (RAE): A Case Report

Author(s) and Institution(s):
JUNHO AN, MD
Division of Interventional Radiology, Department of Radiology, SMG Yeonse Hospital, Republic of Korea

Objectives:
In advanced Autosomal Dominant Polycystic Kidney Disease (ADPKD), refractory hypotension often complicates life-sustaining hemodialysis (HD). When alternative modalities such as peritoneal dialysis (PD) also fail and surgery is precluded, clinicians face a therapeutic impasse.

To evaluate the clinical efficacy and feasibility of bilateral RAE as a salvage strategy for patients who have exhausted conventional dialysis options and are considered ineligible for surgery.

Materials and methods:
Patient:
A 73-year-old female with massive ADPKD and polycystic liver disease.

Clinical Status:
Failed maintenance HD due to severe intradialytic hypotension (SBP < 90 mmHg).
Transitioned to PD but failed due to limited peritoneal space with abdominal symptoms and recurrent peritonitis.
A liver lobectomy was proposed for IVC decompression but was deemed unfeasible due to high risk.

Procedure:
Planned bilateral RAE as a salvage strategy to alleviate bulk abdominal symptoms and attempt to improve circulatory stability.
Bilateral RAE performed using a combination of PVA particles (710–1000 μm) for distal bed occlusion and metallic coils (Nester and Tornado) for proximal trunk sacrifice.

Results:
Renal Volume:
Total kidney volume (TKV) reduced by 43.6% (1,740.2 to 980.7 mL) at 6-month follow-up.

Hemodynamic Improvement:
Mean intradialytic SBP significantly increased from 86.3 ± 7.4 to 117.5 ± 7.8 mmHg ($p < 0.001$).

Clinical Outcomes:
Successful and stable transition back to HD. Improvement in metabolic state (Serum albumin: 2.28 ± 0.23 to 3.18 ± 0.08 g/dL).

Hemodynamic stability was achieved despite persistent mechanical IVC compression on follow up imaging.

Conclusion:
Feasible Salvage Option:
Bilateral RAE is a powerful salvage therapy for elderly ADPKD patients who have exhausted all conventional dialysis modalities and are ineligible for surgery. RAE can facilitate a successful transition back to hemodialysis through improved physiological stabilization.

Limitation:
As a single-case report, these findings do not provide definitive clinical guidelines and should be interpreted with caution.

GROUND FLOOR

Exhibition Hall

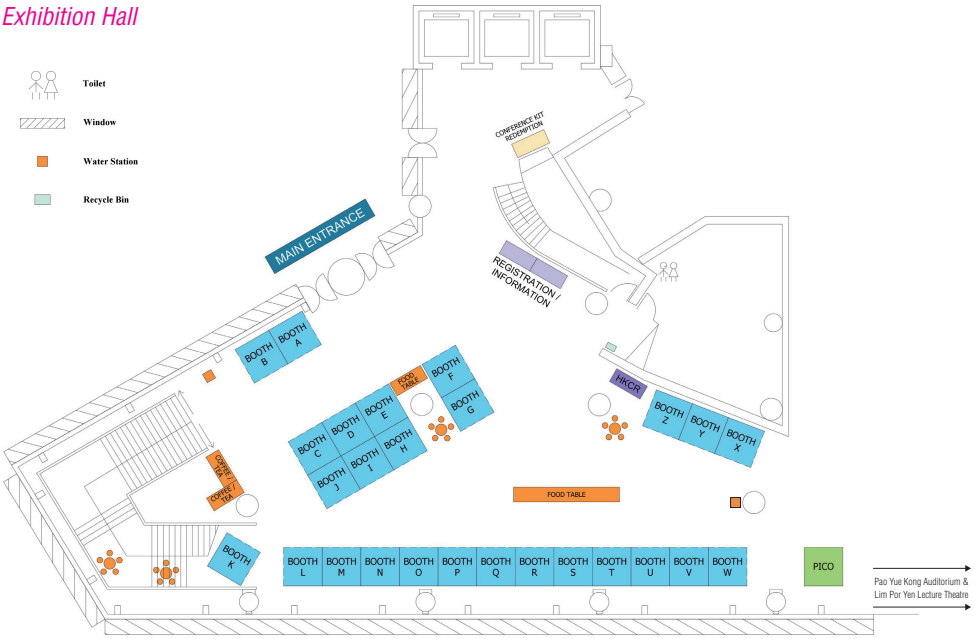

FIRST FLOOR

Run Run Shaw Hall & Foyer

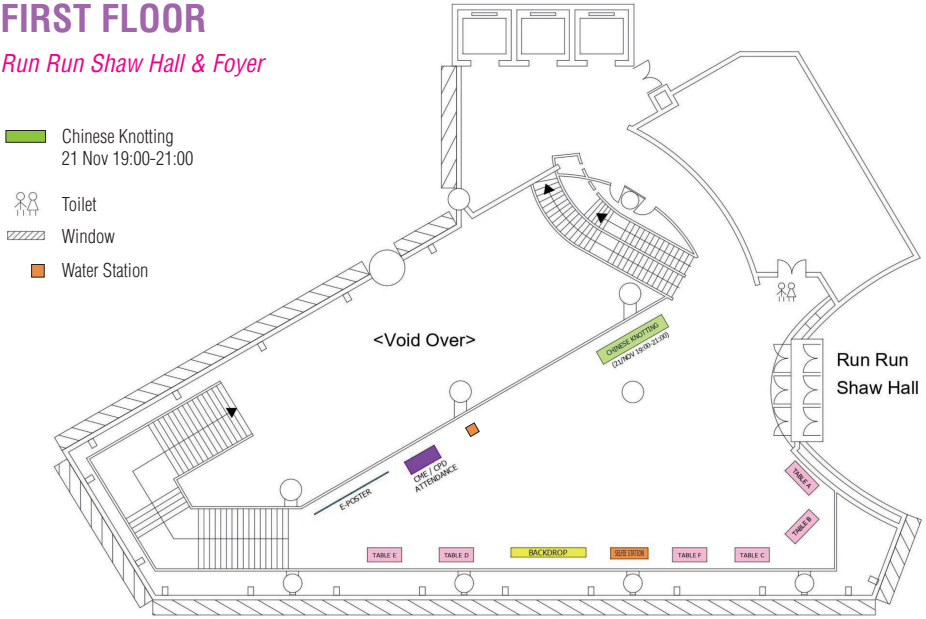

Technical Exhibitions

Booth A	Celltrion Healthcare Hong Kong Limited
Booth B	GSK Hong Kong
Booth C	Gilead Sciences Hong Kong Limited
Booth D	AstraZeneca Hong Kong Limited
Booth E	Johnson & Johnson (Hong Kong) Ltd.
Booth F	Bristol-Myers Squibb Pharma (HK) Limited
Booth G	Merck Sharp & Dohme (Asia) Ltd.
Booth H	Penumbra, Inc.
Booth I	DKSH Hong Kong Limited
Booth J	Pierre Fabre
Booth K	Guerbet Asia Pacific Ltd.
Booth L	Novartis Pharmaceuticals (HK) Limited
Booth M	GE HealthCare
Booth N	Roche
Booth O	Merck Pharmaceutical (HK) Ltd.
Booth P	Prism Technologies Limited
Booth Q	Astellas Pharma Hong Kong Co., Ltd.
Booth R	Pfizer Corporation Hong Kong Limited
Booth S	Bayer HealthCare Limited (Oncology Division)
Booth T	Bayer HealthCare Limited (Radiology Division)
Booth U	BeOne Medicines (Hong Kong) Ltd.
Booth V	Eisai
Booth W	Siemens Healthineers
Booth X	United Imaging Healthcare Hong Kong Limited
Booth Y	Boehringer Ingelheim (Hong Kong) Ltd.
Booth Z	TopAlliance Biosciences
Table A	Ipsen Pharma (Hong Kong)
Table B	Takeda Pharmaceuticals (Hong Kong) Limited
Table C	Jacobson Pharma Corporation Limited
Table D	Elsevier
Table E	Zai Lab (Hong Kong) Limited
Table F	Fosun Industrial Co. Limited

Technical Exhibition Lucky Draw

Visit all Technical Exhibition (Exhibition Booths and Display Desks on G/F & 1/F) to collect E-stamps **on or before Sunday, 22 November 2026, 12:00 noon** to enter the lucky draw.

Lucky draw prizes will be drawn on Sunday, 22 November 2026 **during the Lunch Break at 1:30pm at Banquet Rooms (3/F)**.

Winners must claim their prizes in person. If any winner fails to do so, an alternative winner will be drawn immediately for the unclaimed prize.

The Grand prize is kindly sponsored by Dr. Hector Ma.



Grand Prize

13-inch MacBook Neo 256GB - Silver

Photo source: Apple.com

and many more prizes for our lucky winners.

Don't miss the chance!

Booth Q

Astellas Pharma Hong Kong Co., Ltd.

Company Name	Astellas Pharma Hong Kong Co., Ltd.
Company Address	Unit 1103-08, 11/F, Tower 1, Grand Century Place 193 Prince Edward Rd. West, Mongkok, Kowloon, Hong Kong
Telephone	+852 6092 8813
E-Mail	Jamie.hung@astellas.com
URL	https://www.astellas.com/en/

Company Information:

Astellas Pharma Hong Kong Company Limited plays an important role in the Hong Kong Pharmaceutical Industry. Being a full member of The Hong Kong Association of the Pharmaceutical Industry, we focus on sales and marketing of our products in both Hong Kong and Macau markets for the treatment of five major therapeutic areas – Immunology, Anti-infective, Urology, Oncology and Metabolic.

Booth D

AstraZeneca Hong Kong Limited

Company Name	AstraZeneca Hong Kong Limited
Company Address	11/F China Taiping Finance Centre King Wah Road North Point, HK
Telephone	+852 6693 0095
E-Mail	Justin.li1@astrazeneca.com
URL	https://astrazeneca.com.hk/

Company Information:

AstraZeneca is a global, science-led pharmaceutical company committed to improving the health of people, society and the planet. AstraZeneca Hong Kong, established in 1990, serves Hong Kong and Macau, delivering innovative medicines across Oncology, Cardiovascular & Metabolic Disease, Respiratory and Rare Disease. Beyond medicines, we work with government, healthcare partners and patient organizations to improve access, advance clinical research and strengthen the healthcare ecosystem. Through continued investment in innovation, R&D and sustainability, we aim to transform patient outcomes and contribute to Hong Kong's development as a leading healthcare and medical innovation hub.

Booth S

Bayer HealthCare Limited (Oncology Division)

Company Name	Bayer HealthCare Limited
Company Address	14/F, Oxford House, Taikoo Place, 979 King's Road Quarry Bay, Hong Kong
Telephone	+852 2814 4809
E-Mail	audrey.wan.ext@bayer.com
URL	https://www.bayer.com/en/hong-kong

Company Information:

Bayer is a life science company and a global leader in healthcare, agriculture and nutrition. Our innovative products are designed to address the challenges of a rapidly growing and aging population. We are helping farmers to produce more while restoring nature, working towards treating the untreatable and curing disease, as well as empowering billions to live healthier lives with trusted self-care solutions.

Booth T

Bayer HealthCare Limited (Radiology Division)

Company Name	Bayer HealthCare Limited
Company Address	14/F, Oxford House, Taikoo Place, 979 King's Road Quarry Bay, Hong Kong
Telephone	+852 2814 5215
Fax	+852 3526 4752
E-Mail	bayerhkradiology@bayer.com
URL	https://radiology.bayer.com.hk/

Company Information:

Bayer Radiology team are committed to advancing diagnostic imaging through innovation, expertise and close collaboration with healthcare professionals. With more than 100 years of experience in radiology, Bayer provides solutions across contrast media, injection systems, workflow solutions and medical education to support efficient, high-quality and patient-focused imaging. In Hong Kong, our Radiology team brings together commercial, product, marketing and customer-support expertise, working closely with healthcare professionals and partners to address evolving needs in CT, MRI and other areas of diagnostic imaging.

Booth U

BeOne Medicines (Hong Kong) Ltd.

Company Name	BeOne Medicines (Hong Kong) Ltd.
Company Address	Room 1002, Level 10, Two Chinachem Central 26 Des Voeux Road Central, Central, Hong Kong
Telephone	+852 9045 3894
E-Mail	eric.fung@beonemed.com
URL	https://beonemedicines.com/

Company Information:

At BeOne Medicines we are relentlessly innovating to accelerate the development and delivery of transformative medicines for cancer to reach more people around the world. From clinical trial enrollment to each stage of the treatment journey, we are building the infrastructure, partnerships, and programs to deliver innovative cancer therapies faster, reliably, and at scale.

Booth Y

Boehringer Ingelheim (Hong Kong) Ltd.

Company Name	Boehringer Ingelheim (Hong Kong) Ltd.
Company Address	Suites 1504-9, Great Eagle Centre 23 Harbour Road, Wanchai
Telephone	+852 2596 1358
E-Mail	jacky.loo@boehringer-ingelheim.com tiffy.chan@boehringer-ingelheim.com
URL	https://www.boehringer-ingelheim.com/hk/en

Company Information:

Boehringer Ingelheim (Hong Kong) Ltd.
Boehringer Ingelheim is working on breakthrough therapies that transform lives, today and for generations to come. As a leading research-driven biopharmaceutical company, we create value through innovation in areas of high unmet medical need. Founded in 1885 and family-owned ever since, Boehringer Ingelheim takes a long-term, sustainable perspective. More than 53,000 employees serve over 130 markets in the two business units: Human Pharma and Animal Health. Learn more at www.boehringer-ingelheim.com.

Booth F

Bristol-Myers Squibb Pharma (HK) Limited

Company Name	Bristol-Myers Squibb Pharma (HK) Limited
Company Address	Room 3001-3002, 30/F, Windsor House 311 Gloucester Road, Causeway Bay, Hong Kong
Telephone	+852 9674 9332
E-Mail	Hayes.Law@bms.com
URL	https://www.bms.com

Company Information:

Bristol Myers Squibb is a global biopharmaceutical company dedicated to discovering, developing and delivering innovative medicines that help patients overcome serious diseases.

Booth A

Celltrion Healthcare Hong Kong Limited

Company Name	Celltrion Healthcare Hong Kong Limited
Company Address	Suite 3305, 33rd Floor, Tower 5, The Gateway Harbour City, 15 Canton RD, TST, Kowloon, HK
Telephone	+852 9431 6375
E-Mail	nelson.chan@celltrionhc.com
URL	https://www.celltrion.com/en-us

Company Information:

Celltrion is a leading global biopharmaceutical company dedicated to improving the health and well-being of patients focusing on biosimilar.

Booth V

Eisai

Company Name	Eisai
Company Address	Unit A, 29F, Lee&Man Commercial Center
Telephone	+852 5792 1348
E-Mail	y-ryan@eisaihk.com
URL	https://eisaihk.com/

Company Information:

With a commitment to innovation and patient care, Eisai Hong Kong focuses on developing solutions that enhance the quality of life for patients facing various health challenges. Through its global expertise and local presence, the company aims to make a lasting impact on the healthcare landscape in the region.

Booth I

DKSH Hong Kong Limited

Company Name	DKSH Hong Kong Limited
Company Address	19th Floor, Dah Sing Financial Tower 36 Heung Yip Road, Wong Chuk Hang, Hong Kong
Telephone	+852 9140 8952
E-Mail	angela.zheng@dksh.com
URL	https://www.dksh.com/hk-en//home

Company Information:

DKSH markets, sells, and distributes high-quality products and brands for multinational and Fortune 500 companies in Asia Pacific, Europe, and North America. Through our Business Units Consumer Goods, Healthcare, Performance Materials, and Technology, we deliver sustainable growth for our partners.

Table D

Elsevier

Company Name	Elsevier
Company Address	11/F., Oxford House, Taikoo Place, 979 King's Road Quarry Bay, Hong Kong
Telephone	+852 2965 1323
Fax	+852 2976 0778
E-Mail	k.lai@elsevier.com
URL	https://www.elsevier.com/about

Company Information:

Elsevier is a global leader in advanced information and decision support for science and healthcare. We believe that by working together with the communities we serve, we can shape human progress to go further, happen faster, and benefit all.

Table F

Fosun Industrial Co. Limited

Company Name	Fosun Industrial Co. Limited
Company Address	Rm 2C&2E, Beverly House, 93-107 Lockhart Road Wan Chai, HK
Telephone	+852 9263 3004
E-Mail	wilsonwong@fosunpharma.com
URL	https://www.fosunpharma.com/en/

Company Information:

Fosun Pharma
Founded in 1994, Fosun Pharma is an innovation-driven global pharmaceutical and healthcare group spanning pharmaceuticals, medical devices and diagnostics, and healthcare services. With innovative medicines at its core, the company addresses major unmet needs in oncology, immune-inflammatory and neurodegenerative diseases through leading platforms in antibodies, ADCs, small molecules, cell therapy. Innovation for Good Health—Fosun Pharma is committed to becoming a global leading healthcare innovation integrator.

Booth M

GE HealthCare

Company Name	GE HealthCare
Company Address	Unit 506, 5/F, Tower A, 83 King Lam Street Cheung Sha Wan, Kowloon, Hong Kong
Telephone	+852 9383 2729
E-Mail	Cathy.choi@gehealthcare.com
URL	gehealthcare.com

Company Information:

GE HealthCare is a leading global healthcare solutions provider of advanced medical technology, pharmaceutical diagnostics, and AI, cloud and software solutions that help clinicians tackle the world's most complex diseases.

Serving patients and providers for 130 years, GE HealthCare is delivering bold innovations designed for the next era of medicine across its Advanced Imaging Solutions, Pharmaceutical Diagnostics, and Patient Care Solutions segments to help clinicians deliver more personalized, precise patient care.

We are a $20.6 billion business with approximately 54,000 colleagues working to create a world where healthcare has no limits.

Booth C

Gilead Sciences Hong Kong Limited

Company Name	Gilead Sciences Hong Kong Limited
Company Address	26/F, Hysan Place, 500 Hennessy Road Causeway Bay, HK
Telephone	+852 6013 9076
E-Mail	fiona.wong2@gilead.com
URL	https://www.gilead.com/zh-hk/

Company Information:

At Gilead, "Creating possible" is more than a belief - it is a mission embraced by every employee. With a strong foundation and a diverse culture enriched by home-grown talent, we will continue to work alongside our partners to deliver innovative therapies and strive for a healthier community.

Booth B

GSK Hong Kong

Company Name	GSK Hong Kong
Company Address	Suites 1004-10, 10/F, Tower 6, The Gateway 9 Canton Road, Tsim Sha Tsui
Telephone	+852 9369 6621
E-Mail	monica.x.tsang@gsk.com
URL	http://gsk.com.hk

Company Information:

At GSK, we prevent and treat disease with specialty medicines, vaccines and general medicines. We're a focused biopharma company with strong momentum and big ambitions. We're pursuing research and development across four core therapeutic areas: respiratory, immunology and inflammation; oncology; HIV and infectious diseases.

Booth K

Guerbet Asia Pacific Ltd.

Company Name	Guerbet Asia Pacific Ltd.
Company Address	Room 3603–06, Chubb Tower, Windsor House 311 Gloucester Road, Causeway Bay, HONG KONG
Telephone	+852 9513 1057
E-Mail	ext.suki.wong@guerbet.com hayden.li@guerbet.com
URL	https://www.guerbet.com/

Company Information:

Guerbet offers a comprehensive range of contrast media, medical devices, and digital and AI solutions for diagnostic and interventional imaging.

Consistent with its purpose - the Group has been a pioneer in contrast products for nearly a century. In a world that is changing at an accelerating pace - with an ageing population, rising healthcare costs, growth in the MRI and X-ray markets - Guerbet intends, through its solutions, to help prescribers, radiologists and patients meet the new challenges of medical imaging.

Hologic Asia Pacific Ltd.

Company Name	Hologic Asia Pacific Ltd.
Company Address	Unit 01-03A, 13/F, No. 909 Cheung Sha Wan Road Cheung Sha Wan, Kln, Hong Kong
Telephone	+852 3748 7700
Fax	+852 3526 0723
E-Mail	HK_Mktg@Hologic.com
URL	https://www.hologic.com/

Company Information:

Hologic helps women around the world live healthier lives. We develop innovative medical technologies that effectively detect, diagnose and treat health conditions and raise the standard of care globally. We know women face unique health challenges at every stage of life, and we are passionate about being a force for good.

Hong Kong Society of Clinical Oncology

Company Name	Hong Kong Society of Clinical Oncology

Company Information:

Hong Kong Society of Clinical Oncology was formed in 1970, by a group of Clinical Oncologists with the aim to promote and draw public attention to Clinical Oncology. It was originally named as the Hong Kong Society of Radiology and Oncology, and was officially renamed as the Hong Kong Society of Clinical Oncology in 2000. The majority of the society members are Clinical Oncologists. Associate members include medical professionals such as Pathologists, Hematologist and Radiologists.

Hong Kong Society of Interventional Radiology

Company Name	Hong Kong Society of Interventional Radiology
Company Address	Department of Diagnostic and Interventional Radiology Kwong Wah Hospital, 25 Waterloo Road, Kowloon, Hong Kong SAR, China
Telephone	+852 3517 5189
Fax	+852 3517 5454
E-Mail	info@hksir.org.hk
URL	http://www.hksir.org.hk

Company Information:

Hong Kong Interventional Radiology (HKSIR) was founded in 2000.

The objectives of HKSIR are as follow:

1) To engage and support education, research, study and survey in respect of issues relating to interventional radiology.
2) To promote and establish close contacts among medial professionals who are interested and working in the field of interventional radiology.
3) To promote honourable interventional radiology practice, and to establish an ethical and health environment for the practice of interventional radiology in the interest of the general public of Hong Kong.

Hong Kong Society of Nuclear Medicine and Molecular Imaging

Company Name	Hong Kong Society of Nuclear Medicine and Molecular Imaging
Company Address	Unit C, 17/F, Silvercorp Int'l Tower 713 Nathan Road, Kowloon, Hong Kong
Telephone	+852 3506 6543
Fax	+852 2780 4451
E-Mail	Nil (Enquiry through website)
URL	http://www.hksnmmi.org

Company Information:

Hong Kong Society of Nuclear Medicine and Molecular Imaging was formed in 1985. It was a milestone of nuclear medicine as a distinctive specialization in the medical profession in Hong Kong. Nuclear Medicine is a clinical specialty that applies radioactive materials in "unsealed form" for the diagnosis and treatment of diseases. Molecular imaging, including Positron emission tomography (PET), has become the essential component in cancer diagnosis and treatment monitoring, as well as in other disease entities. In addition, radionuclide therapy has progressed remarkably in recent years. The Society has involved in great effort in the development of these new technologies and provides a great platform to promote professional development and training to members, specialty certification, local accreditation and international recognition for professionals practicing Nuclear Medicine in Hong Kong.

Table A

Ipsen Pharma (Hong Kong)

Company Name	Ipsen Pharma (Hong Kong)
Company Address	34/F, Tower 1, Times Square, Causeway Bay
Telephone	+852 9493 9596
E-Mail	alex.tong.ext@ipsen.com
URL	https://www.ipsen.com/

Company Information:

Founded in 1929 as a family business, Ipsen has almost a century of experience and expertise and focuses in three therapeutic areas: Oncology, Rare Disease and Neuroscience.

Table C

Jacobson Pharma Corporation Limited

Company Name	Jacobson Pharma Corporation Limited
Company Address	Unit 2313-18, 23/F, Tower 1 Millennium City 1 388 Kwun Tong Road, Kwun Tong, Kowloon, Hong Kong
Telephone	+852 6886 5402
E-Mail	charmain_hong@pharmason.com.hk
URL	https://jacobsonpharma.com/html/index.php

Company Information:

Jacobson is a leading pharmaceutical company in Hong Kong vertically integrated in the research, development, production, sale and distribution of essential medicines and specialty drugs, with a dedicated team of over 1,500 employees. Tracing its European origin back to 1960's when first founded as a pharmaceutical trading house, Jacobson has grown notably since which has been driven by its unwavering commitment to serving the needs of medical professionals and consumers in Hong Kong. Today, the name of Jacobson is synonymous with product quality, service excellence and professional partnership in the healthcare arena.

Booth E

Johnson & Johnson (Hong Kong) Ltd.

Company Name	Johnson & Johnson (Hong Kong) Ltd.
Company Address	13/F, Tower 1, Grand Century Place, 193 Prince Edward Rd West Mongkok, Hong Kong
Telephone	+852 9554 6530
E-Mail	dho6@its.jnj.com
URL	https://www.jnj.com/

Company Information:

J&J Innovative Medicine Asia Pacific is here to transform the future of health with you. The experiences of patients around the world inform and inspire our science-based innovations, which continue to change and save lives.

Booth O

Merck Pharmaceutical (HK) Ltd.

Company Name	Merck Pharmaceutical (HK) Ltd.
Company Address	Suites 3801–2, 38/F, AIA Kowloon Tower Landmark East, Kwun Tong
Telephone	+852 9505 8883
E-Mail	kay.yuen@merckgroup.com
URL	https://www.merckgroup.com/en

Company Information:

As a vibrant science and technology company, we believe in science as a force for good. We uniquely combine three specialized, innovation-driven businesses: Life Science, Healthcare, and Electronics. In Healthcare, we help to create, improve and prolong lives worldwide with pioneering therapies that address unmet medical needs.

Booth G

Merck Sharp & Dohme (Asia) Ltd.

Company Name	Merck Sharp & Dohme (Asia) Ltd.
Company Address	27/F, Lee Garden Two, 28 Yun Ping Road Causeway Bay, Hong Kong
Telephone	+852 9730 7186
E-Mail	twinnie.lo@msd.com
URL	https://www.msd.com.hk/

Company Information:

At MSD, we are unified around our purpose: We use the power of leading-edge science to save and improve lives around the world. For more than a century, we've been at the forefront of research, bringing forward medicines, vaccines and innovative health solutions for the world's most challenging diseases.

Booth L

Novartis Pharmaceuticals (HK) Limited

Company Name	Novartis Pharmaceuticals (HK) Limited
Company Address	2303-2305, 23 Floor, 1111 King's Rd, Taikoo Shing Hong Kong Island
Telephone	+852 9685 7280
E-Mail	cat.chan@novartis.com
URL	https://www.novartis.com/hk-zh/

Company Information:

Novartis is an innovative medicines company. Every day, we work to reimagine medicine to improve and extend people's lives so that patients, healthcare professionals and societies are empowered in the face of serious disease. Our medicines reach nearly 300 million people worldwide.

Booth H

Penumbra, Inc.

Company Name	Penumbra, Inc.
Company Address	1351 Harbor Bay Pkwy, Alameda, CA 94502
Telephone	+852 6149 3476
E-Mail	oyip@penumbrainc.com
URL	https://www.penumbrainc.com/

Company Information:

Founded in 2004 and headquartered in Alameda, California, Penumbra, Inc. is a global medical technology company focused on designing, developing, and manufacturing innovative interventional devices. The company specializes in computer-assisted vacuum thrombectomy systems, aspiration catheters, and access tools utilized primarily to treat severe, time sensitive vascular conditions such as acute ischemic stroke, pulmonary embolisms, and deep vein thrombosis. By providing advanced minimally invasive solutions for hospitals and clinicians globally, Penumbra aims to improve clinical outcomes for patients suffering from complex vascular and neurovascular diseases.

Booth R

Pfizer Corporation Hong Kong Limited

Company Name	Pfizer Corporation Hong Kong Limited
Company Address	21/F, Kerry Centre, 683 King's Road, Quarry Bay, HK
Telephone	+852 9540 8844
E-Mail	phebe.pao@pfizer.com
URL	www.pfizer.com.hk

Company Information:

Pfizer Hong Kong office established in 1956, primarily responsible for marketing of Pfizer's products and business operations in Hong Kong and Macau. Pfizer Hong Kong strives to work for a healthier world, by providing reliable and quality products to the citizens and assisting healthcare professionals in providing the most suitable treatment for patients.

Pfizer is celebrated worldwide for its community care, and Pfizer Hong Kong is no different. The company utilizes the resources and knowledge owned with the business advantage of Pfizer global network in organizing and implementing different social projects in the community with partners.

Philips Electronics Hong Kong Limited

PHILIPS

Company Name	Philips Electronics Hong Kong Limited
Company Address	Level 19, Tower I, Grand Century Place 193 Prince Edward Road West, Mong Kok, Kowloon
Telephone	+ 852 2821 5888
Fax	+ 852 2219 7016
E-Mail	corporate.communications.hk@philips.com
URL	https://www.philips.com.hk/healthcare

Company Information:

As a leading health technology company, it is our purpose to improve people's health and well-being through meaningful innovation. We aim to improve 2.5 billion lives per year by 2030. We will be the best place to work for people who share our passion, promoting personal development, inclusion and diversity. Together we will deliver superior, long-term value to our customers and shareholders, while acting responsibly towards our planet and society, in partnership with our stakeholders.

Booth J

Pierre Fabre

Pierre Fabre Pharma

Company Name	Pierre Fabre
Company Address	10th Floor, Luk Kwok Centre, 72 Gloucester Road Wanchai, Hong Kong
Telephone	+852 6897 3730
Fax	+852 2267 5661
E-Mail	connie.ho@pierre-fabre.com
URL	www.pierre-fabre.com

Company Information:

Pierre Fabre is the 2nd largest dermo-cosmetics company in the world and one of the leading pharmaceutical laboratories in Europe. Founded in the Tarn in 1962 by a humanist, visionary pharmacist, the company is owned by a humanitarian foundation.

Booth P

Prism Technologies Limited

Company Name	Prism Technologies Limited
Company Address	Unit 603-605, 6/F, Yee Kuk Industrial Centre 555 Yee Kuk Street, Cheung Sha Wan, Kowloon, Hong Kong
Telephone	+852 2786 3233
Fax	+852 2786 3812
E-Mail	admin@prismtech.com.hk
URL	https://www.prismtech.com.hk/

Company Information:

Established in 2008, Prism Technologies Limited is engaged in sales, marketing and distribution of a range of leading-technology medical products to Hong Kong and Macau. Our extensive Radiology portfolio features collaborations with pioneering medtech innovators, including:

- Bayer Medical Care (contrast injectors and dose management),
- GE Healthcare (digital mammography & DXA),
- Candelis (mini-PACS),
- Lunit (AI) and
- CompAI (specimen radiography)

Together, these partnerships enable Prism Technologies Limited to deliver a comprehensive suite of state-of-the-art medical products designed to empower healthcare professionals with enhanced precision, operational efficiency, and improved patient outcomes.

Booth N

Roche

Company Name	Roche
Company Address	Unit 1-2, 24/F, Central Plaza,18 Harbour Rd Wan Chai, Hong Kong
Telephone	+852 6117 2320
E-Mail	tony.shum@roche.com
URL	https://www.roche.com

Company Information:

Founded in Basel, Switzerland, in 1896, Roche is a global healthcare leader combining diagnostics, medicines, and digital solutions to prevent and cure diseases. Operating in over 150 countries, Roche focuses on critical areas including oncology, neurology, cardiovascular health, infectious diseases, and immunology to improve patients' lives worldwide.

The Roche Group includes Genentech in the United States as a wholly owned subsidiary and holds a majority stake in Japan's Chugai Pharmaceutical.

For more information, please visit www.roche.com.

Booth W

Siemens Healthineers

Company Name	Siemens Healthineers
Company Address	Units 901-903 & 908B, 9/F Tower B, Manulife Financial Centre 223 Wai Yip Street, Kwun Tong Kowloon, Hong Kong
Telephone	+852 9020 1279
Fax	+852 2814 0355
E-Mail	monique.yeung@siemens-healthineers.com
URL	www.siemens-healthineers.com

Company Information:

Siemens Healthineers pioneers breakthroughs in healthcare. For everyone. Everywhere. Sustainably. The company is a global provider of healthcare equipment, solutions and services, with activities in more than 180 countries and direct representation in more than 70. The group comprises Siemens Healthineers AG, listed as SHL in Frankfurt, Germany, and its subsidiaries. As a leading medical technology company, Siemens Healthineers is committed to improving access to healthcare for underserved communities worldwide and is striving to overcome the most threatening diseases. The company is principally active in the areas of imaging, diagnostics, cancer care and minimally invasive therapies, augmented by digital technology and artificial intelligence.

Snowhill Science Limited

Company Name	Snowhill Science Limited
Company Address	Units 801-803, Level 8, Core C, Cyberport 3 100 Cyberport Road, Hong Kong SAR
Telephone	+852 9301 5180
E-Mail	admin@snowhillscience.com
URL	www.snowhillscience.com

Company Information:

A dedicated start-up focusing on high-end diagnostics in the field of wellness and longevity. We take a data-driven approach, utilising machine learning and AI for accurate prediction — across blood-based biomarkers, medical imaging, genomics and wearables.

Table B

Takeda Pharmaceuticals (Hong Kong) Limited

Company Name	Takeda Pharmaceuticals (Hong Kong) Limited
Company Address	RM1801, Lee Garden One, 33 Hysan Ave Causeway Bay, Hong Kong
Telephone	+852 9758 6945
E-Mail	LESLIE.YEUNG@TAKEDA.COM
URL	https://www.takeda.com/en-hk/

Company Information:

A global values-based, R&D-driven biopharmaceutical leader, Takeda is committed to creating better health for people and a brighter future in Hong Kong.

With a dedicated workforce in Hong Kong, the work we do transforms lives, helping patients with limited or no treatment options in our therapeutic and business areas of oncology, rare diseases, neuroscience, gastroenterology, plasma-derived therapies, and vaccines.

Takeda is headquartered in Tokyo, Japan, with a global hub in Cambridge, MA, United States. We have a presence in approximately 80 countries and regions, a network of manufacturing sites around the world, and major research centers in Japan and the United States. In Hong Kong, our local headquarters is based in Causeway Bay.

The Hong Kong Society of Diagnostic Radiologists

Company Name	The Hong Kong Society of Diagnostic Radiologists
Company Address	Department of Diagnostic and Interventional Radiology Kwong Wah Hospital, 25 Waterloo Road, Kowloon
Telephone	+852 3517 5189
Fax	+852 3517 5454
E-Mail	hksdr.adm@gmail.com

Company Information:

The Hong Kong Society of Diagnostic Radiologists (HKSDR) was founded in 1977.

The HKSDR objectives are as follows:

1. To promote the exchange of scientific knowledge and information concerning diagnostic radiology, and to establish close personal and professional contacts among those medical doctors who are interested and working in the field of diagnostic radiology.
2. To organize and hold scientific meetings and lectures concerning diagnostic radiology and to encourage research in that field.
3. To promote honourable radiodiagnostic practice, and to establish an ethical and healthy environment for the practice of diagnostic radiology in the interest of the general public of Hong Kong.

HKSDR members are all registered medical doctors in Hong Kong who are actively engaged in the practice of diagnostic radiology.

Booth Z

TopAlliance Biosciences

Company Name	TopAlliance Biosciences
Company Address	35/F, Central Plaza, 18 Harbour Road Wan Chai, Hong Kong
Telephone	+852 5498 2093
E-Mail	PakMing_Chim@topalliancebio.com
URL	https://www.topalliancebio.com/

Company Information:

An innovation-driven biopharmaceutical company dedicated to the discovery and development of innovative drugs

Booth X

United Imaging Healthcare Hong Kong Limited

Company Name	United Imaging Healthcare Hong Kong Limited
Company Address	Suite 918, 9th Floor, Tower 3, China Hong Kong City No.33 Canton Rd, Tsim Sha Tsui, KL, HK
Telephone	+852 6676 1368
Fax	+852 3150 8096
E-Mail	brian.lee@united-imaging.com
URL	https://global.united-imaging.com/en/about-united-imaging

Company Information:

United Imaging (UIH) is dedicated to providing, developing and producing high-performance advanced medical imaging, radiotherapy equipment, life science instruments and offers intelligent digital solutions to customers worldwide. UIH is committed to creating more value for our customers and constantly improving the global accessibility of high-end medical equipment and services through in-depth cooperation with hospitals, universities, research institutions, and industry partners.
Our vision: Leading Healthcare Innovation
Our mission: To Bring Equal Healthcare for All

Table E

Zai Lab (Hong Kong) Limited

Company Name	Zai Lab (Hong Kong) Limited
Company Address	Room 2301, 23/F, Island Place Tower, 510 King's Road North Point, Hong Kong
Telephone	+852 6210 2200
E-Mail	natalie.hui@zailaboratory.com
URL	https://www.zailaboratory.com/

Company Information:

Zai Lab is a patient-focused, innovative, commercial-stage, global biopharmaceutical company based in China and the United States. We are dedicated to discovering, developing, and commercializing best-in-class and first-in-class therapies that address medical conditions with significant unmet needs in oncology, immunology, neuroscience, and infectious disease.

Acknowledgement

The College gratefully acknowledges the following companies / organisations for their support and contributions:

HKCR ASM Corporate Partners

Gold

Bristol-Myers Squibb Pharma (HK) Limited

Johnson & Johnson (Hong Kong) Ltd.

Merck Sharp & Dohme (Asia) Ltd.

TopAlliance Biosciences

Guerbet Asia Pacific Ltd.

AstraZeneca Hong Kong Limited

Boehringer Ingelheim (Hong Kong) Ltd.

Gilead Sciences Hong Kong Limited

United Imaging Healthcare Hong Kong Limited

Silver

DKSH Hong Kong Limited

GSK Hong Kong

Bronze

Astellas Pharma Hong Kong Co., Ltd.

BeOne Medicines (Hong Kong) Ltd

GE HealthCare

Merck Pharmaceutical (HK) Ltd.

Novartis Pharmaceuticals (HK) Limited

Pfizer Corporation Hong Kong Limited

Pierre Fabre

Roche

Siemens Healthineers

Bayer HealthCare Limited

Hologic Asia Pacific Ltd.

Celltrion Healthcare Hong Kong Limited

Eisai

Penumbra, Inc.

Prism Technologies Limited

Fosun Industrial Co. Limited

Ipsen Pharma (Hong Kong)

Jacobson Pharma Corporation Limited

Takeda Pharmaceuticals (Hong Kong) Limited

Zai Lab (Hong Kong) Limited

Philips Electronics Hong Kong Limited

Snowhill Science Limited

Elsevier

Hong Kong Society of Clinical Oncology

Hong Kong Society of Interventional Radiology

The Hong Kong Society of Diagnostic Radiologists

Hong Kong Society of Nuclear Medicine and Molecular Imaging

HKCR Education & Research Fund

DISCLAIMER

The abstracts contained in this publication are printed verbatim as they are submitted; they have not been edited in any manner or form by the organisers of the 34th ASM of HKCR. The organisers of the 34th ASM of HKCR will not assume responsibility for the contents of the abstracts. All the advertising materials provided by the sponsors have not been edited in any manner by the organisers of the 34th ASM of HKCR. The organisers of the 34th ASM of HKCR will not assume responsibility for the contents of the advertising materials.

NOW APPROVED

VYLOY®
zolbetuximab
for infusion 100mg vial

A new target.
A new therapy.

A new way to treat advanced* G/GEJ cancer has come into focus.[1]

VYLOY is a first-in-class monoclonal antibody that targets Claudin 18.2, a novel biomarker in advanced* G/GEJ adenocarcinoma.[1-3]

*Locally advanced unresectable or metastatic.[1]
G/GEJ=gastric/gastro-oesophageal junction.

Please find the abbreviated prescribing information here
Email us at pv@hk.astellas.com when there is any Adverse Event

References: 1. Vyloy (Zolbetuximab) Hong Kong Prescribing Information. **2.** Shitara K, Lordick F, Bang YJ, et al. Zolbetuximab plus mFOLFOX6 in patients with CLDN18.2-positive, HER2-negative, untreated, locally advanced unresectable or metastatic gastric or gastro-oesophageal junction adenocarcinoma (SPOTLIGHT): a multicentre, randomised, double-blind, phase 3 trial. *Lancet* (Epub ahead of print) 04-14-2023. **3.** Shah MA, Shitara K, Ajani JA, et al. Zolbetuximab plus CAPOX in CLDN18.2-positive gastric or gastroesophageal junction adenocarcinoma: the randomized, phase 3 GLOW trial. *Nat Med* (Epub) 07-31-2023.

astellas
ONCOLOGY

Astellas Pharma Hong Kong Co., Ltd.
Unit 1103 - 08, 11/F, Tower 1, Grand Century Place,
193 Prince Edward Road West, Mongkok, Kowloon
Tel: (852) 2377 9801 Fax: (852) 2856 1440
MAT-HK-ZOL-2025-00001 | September 2025
©2025 ASTELLAS PHARMA INC. ALL RIGHTS RESERVED.

IMFINZI®
英飛凡®
(durvalumab)

IMJUDO®
(tremelimumab)
Concentrate for Solution for Infusion

HCC

FIRST-LINE UNRESECTABLE

The first dual IO combination in first-line advanced or unresectable HCC

FOR SURVIVAL

with STRIDE[1,2]*

LATEST OVERALL SURVIVAL AT 7 YEARS[4]

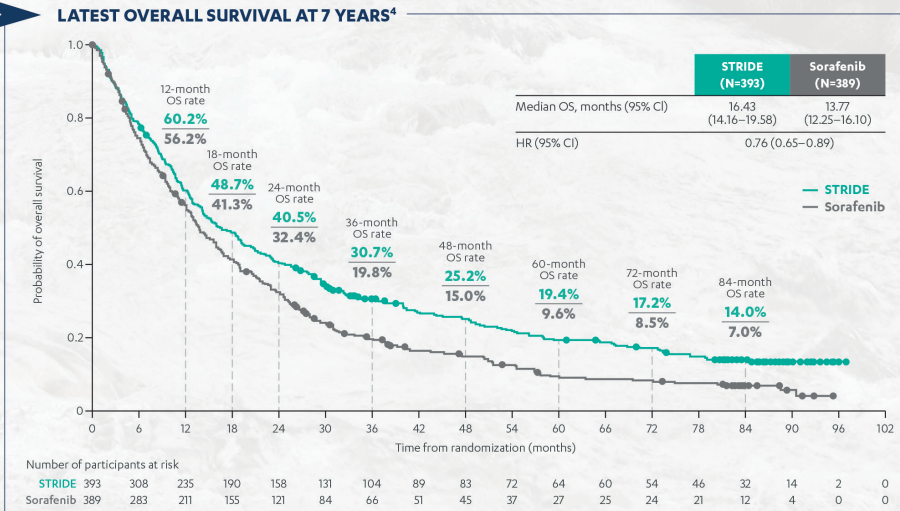

	STRIDE (N=393)	Sorafenib (N=389)
Median OS, months (95% CI)	16.43 (14.16–19.58)	13.77 (12.25–16.10)
HR (95% CI)	0.76 (0.65–0.89)	

Number of participants at risk

STRIDE	393	308	235	190	158	131	104	89	83	72	64	60	54	46	32	14	2	0
Sorafenib	389	283	211	155	121	84	66	51	45	37	27	25	24	21	12	4	0	0

Adopted from Abou-Alfa. ESMO Congress 2026[4]

STRIDE achieved a statistically significant 24% reduction in the risk of death versus sorafenib (HR = 0.76; 95% CI: 0.65-0.89). The number of events was 262 (66.7%) with STRIDE and 293 (75.3%) with sorafenib. Median OS: 16.43 months (95% CI: 14.16-19.58) with STRIDE 13.77 months (95% CI: 12.25-16.13) with sorafenib

Summary: STRIDE demonstrated durable 6-year survival benefits in unresectable HCC, reducing the risk of death by 24% versus sorafenib and improving median OS to 16.4 vs 13.8 months. The safety profile remained manageable and consistent with previous analyses, with no new safety signals observed during extended follow-up

In advanced or unresectable hepatocellular carcinoma (uHCC)

THE UNPRECEDENTED LONGEST FOLLOW-UP OS DATA AT 6 YEARS[3]

*STRIDE: Single Tremelimumab Regular Interval Durvalumab

References: 1. IMJUDO Hong Kong Prescribing Information. Dec 2023. **2.** IMFINZI Hong Kong Prescribing Information. March 2026. **3.** Sangro B, et al. Presented at: European Society for Medical Oncology (ESMO) Congress; 17–21 October, 2025; Berlin, Germany. **4.** Abou-Alfa GK et al. Presented at: European Society for Medical Oncology (ESMO) Congress; 23-27 October, 2026; Madrid, Spain

For healthcare professional use only.
Please visit contactazmedical.astrazeneca.com, for (1) enquiring Medical Information (MI), (2) reporting Individual Case Safety Report (ICSR) and/or (3) reporting Product Quality Complaint (PQC) to AstraZeneca Hong Kong Limited.
IMJUDO, IMFINZI and 英飛凡, are registered trademarks of the AstraZeneca group of companies.
©2026 AstraZeneca. All rights reserved.

AstraZeneca 阿斯利康

AstraZeneca Hong Kong Limited
Unit 1-3, 11/F, China Taiping Finance Centre, 18 King Wah Road, North Point, Hong Kong
Tel. no.: (852) 2420 7388 Fax. no.: (852) 2422 6788
HK-13214 AUG-30-2026

IMFINZI® 英飛凡® (durvalumab)

IMJUDO® (tremelimumab) Concentrate for Solution for Infusion

TEVIMBRA®
(tislelizumab)
100 mg concentrate for solution for infusion

A TREATMENT OPTION RECOMMENDED BY **ESMO+NCCN GUIDELINES**[6,9,10]

FOR YOUR PATIENTS WITH **UPPER GI CANCER**

LOOK FURTHER WITH TEVIMBRA

A unique PD-1 inhibitor optimised for lasting inhibition, through potent PD-1 binding and robust T-cell activation[1–5]*



TEVIMBRA is approved in 3 upper GI cancer indications: 1L OSCC, OSCC after prior platinum-based chemotherapy and 1L G/GEJ adenocarcinoma[7]

More than 2 million patients have been treated globally to date across all indications[8]

A well-characterised safety profile established across all approved indications in a broad population of nearly 3,000 patients[7]

INDICATIONS

Gastric / gastroesophageal junction (G/GEJ) adenocarcinoma[7]

TEVIMBRA, in combination with platinum and fluoropyrimidine-based chemotherapy, is indicated for the first-line treatment of adult patients with HER-2-negative locally advanced unresectable or metastatic G/GEJ adenocarcinoma whose tumours express PD-L1 with a tumour area positivity (TAP) score ≥5%.

Oesophageal squamous cell carcinoma (OSCC)[7]

TEVIMBRA, in combination with platinum-based chemotherapy, is indicated for the first-line treatment of adult patients with unresectable, locally advanced or metastatic OSCC whose tumours express PD-L1 with a TAP score ≥5%.

TEVIMBRA as monotherapy is indicated for the treatment of adult patients with unresectable, locally advanced or metastatic OSCC after prior platinum-based chemotherapy.

Abbreviated Prescribing Information:

Abbreviated Prescribing Information: Presentation: Tevimbra (Tislelizumab) Injection 100mg/10ml. Indication: Tevimbra is indicated for the treatment of patients with (1) In combination with Paclitaxel plus Carboplatin or Paclitaxel for Injection (Albumin Bound) plus Carboplatin as first-line treatment in patients with unresectable, locally advanced or metastatic squamous NSCLC; (2)Tevimbra in combination with pemetrexed and platinum-containing chemotherapy is indicated for thefirst-line treatment of adult patients with non-squamous NSCLC whose tumours have PD-L1 expression on ≥50% of tumour cells with no EGFR or ALK positive mutations and who have locally advanced NSCLC and are not candidates for surgical resection or platinum-base chemoradiation, or metastatic NSCLC;(3) As monotherapy is indicated for the treatment of adult patients with locally advanced or metastatic non squamous non-small-cell lung cancer (NSCLC), with EGFR genomic tumor aberrations negative and ALK genomic tumor negative, that has progressed after or did not tolerate prior platinum-based chemotherapy and of adult patients with locally advanced or metastatic squamous non-small-cell lung cancer (NSCLC), with EGFR and ALK negative or unknown, that has progressed after or did not tolerate prior platinum-based chemotherapy. (4) in combination with platinum-based chemotherapy, is indicated for the first-line treatment of adult patients with unresectable, locally advanced or metastatic OSCC whose tumours express PD-L1 with a TAP score ≥ 5% ; (5)the treatment of locally advanced or metastatic esophageal squamous cell carcinoma who have disease progression following or are intolerant to first-line standard chemotherapy;(6) In combination with with platinum and fluoropyrimidine-based chemotherapy, is indicated for the first-line treatment of adult patients with HER-2-negative locally advanced unresectable or metastatic gastric or gastroesophageal junction (G/GEJ) adenocarcinoma whose tumours express PD-L1 with a tumour area positivity (TAP) score ≥ 5%. Dosage & Administration: Tevimbra is administered by intravenous infusion. The recommended dose of Tevimbra is 200 mg every 3 weeks. The treatment should last until disease progression or intolerable toxicity. Contraindications: Hypersensitivity to the active substance or to any of the excipients. Special Precautions: Immune-related adverse reactions, Immune-related pneumonitis, Immune-related hepatitis, Immune-related skin reactions, Immune-related colitis, Immune-related endocrinopathies, Thyroid disorders, Adrenal insufficiency, Hypophysitis, Type I diabetes mellitus, Immune-related nephritis with renal dysfunction, Other immune-related adverse reactions, Solid organ transplant rejection, Infusion-related reactions, Patients excluded from clinical studies and Patients on controlled sodium diets. Adverse Reactions: The most commonly occurring adverse reactions (≥ 10%) were anaemia, hypothyroidism, cough, rash, pruritus, fatigue, decreased appetite, aspartate aminotransferase increased, alanine aminotransferase increased, blood bilirubin increased. Refer to the full prescribing information for other undesirable effects

*Based on preclinical data.[1-5] †TEVIMBRA is recommended in both 1L OSCC and OSCC after prior platinum-based chemotherapy treatment settings by the ESMO 2025 guidelines.[6]

Abbreviations: 1L, first-line; ESMO, European Society for Medical Oncology; G/GEJ, gastric or gastroesophageal junction; GI, gastrointestinal; OSCC, oesophageal squamous cell carcinoma; PD-1, programmed cell death protein 1; PD-L1, programmed death-ligand 1; TAP, tumour area positivity.

References: 1. Hong Y, et al. *FEBS Open Bio.* 2021;11(3):782–792; 2. Feng Y, et al. AACR annual meeting. March 29–April 3, 2019. Abstract 4048; 3. Zhang T, et al. *Cancer Control.* 2022;29:10732748221110296; 4. Desai J, et al. *J Immunother Cancer.* 2020;8(1):e000453; 5. Zhang T, et al. *Cancer Immunol Immunother.* 2018;67:1079–1090; 6. Obermannova R, et al. *ESMO Open.* 2025;10(2):104134; 7. TEVIMBRA. Hong Kong Abbreviated Prescribing Information, BeOne (Hong Kong); 2025; 8. Data on file - BeOne annual report 2026; 9. NCCN Guidelines Esophageal and Esophagogastric Junction Cancers Version 2.2026 10.NCCN Guidelines Gastric Cancer Version 2.2026

TEVIMBRA and BeOne are registered trademarks owned by BeOne(Hong Kong), Ltd. Copyright © 2026, BeOne(Hong Kong), Ltd All rights reserved.

Document Number - 0726-TEV-PRC-197

BeOne

HERNEXEOS®
zongertinib tablets | 60 mg

HERNEXEOS®, A once-daily oral TKI targeting HER2 (ERBB2)-mutant mNSCLC

after prior systemic therapy[1]



HERNEXEOS® is indicated for the treatment of adult patients with unresectable or metastatic non-squamous non-small cell lung cancer (NSCLC) whose tumors have HER2 *(ERBB2)* tyrosine kinase domain activating mutations, as detected by a validated test, and who have received prior systemic therapy.[1]

This indication is registered under "1+" mechanism.[3]

ORR and PFS by RECIST v1.1 as assessed by BICR.[2]

*HERNEXEOS® was evaluated in BEAMION® LUNG-1, a single-arm, open-label, multi-center trial. Major efficacy outcome measures include ORR and PFS.[2]

BICR=blinded independent central review; CI=confidence interval; ERBB2=erb-b2 receptor tyrosine kinase 2; HER2=human epidermal growth factor receptor 2; mPFS=median progression-free survival; mNSCLC=metastatic non-small cell lung cancer; NE=not evaluated; ORR=objective response rate; PFS=progression-free survival; RECIST=Response Evaluation Criteria In Solid Tumors; TKI=tyrosine kinase inhibitor.

References: 1. HERNEXEOS® Hong Kong Prescribing Information. **2.** Heymach JV, et al. Zongertinib in Previously Treated HER2-Mutant Non-Small-Cell Lung Cancer. N Engl J Med. 2025;392(23):2321-2333. **3.** Pharmacy & Poisons Board of Hong Kong. List of Pharmaceutical Products Registered Under "1+" Mechanism. Available at: https://www.drugoffice.gov.hk/eps/do/en/consumer/news_informations/relicList2.html?indextype=1PLUS. Accessed on 7 May 2026.

© 2026 Boehringer Ingelheim (Hong Kong) Limited. All rights reserved. PC-HK-101824 (05/2026)

Boehringer Ingelheim

Boehringer Ingelheim (HK) Ltd.
Suites 1504-9, Great Eagle Centre,
23 Harbour Road, Wan Chai, Hong Kong
Tel: (852) 2596 0033 Fax: (852) 2827 0162

Please scan the QR code to access the abbreviated prescribing information of HERNEXEOS®



OPDIVO® (nivolumab) + YERVOY® (ipilimumab)

BUILT TO LAST

OPDIVO® + YERVOY®, the dual immunotherapy to provide the opportunity for longer life* and all the moments in between

Durable survival and deeper responses with OPDIVO® + YERVOY® in 1L u/aHCC*†‡1-4

OS at 4 years[4]

Patients alive at 4 years

31% vs 18%

OPDIVO® + YERVOY® | Lenvatinib/sorafenib§

Median OS (Primary endpoint)
Extended analysis

OPDIVO® + YERVOY®		Lenvatinib/sorafenib
23.7 months	vs	20.6 months
(n=335; 95% CI: 18.8-29.4)		(n=333; 95% CI: 17.7-22.5)

HR=0.78 (95% CI: 0.65-0.93)

Responses achieved[¶,4]

ORR# (Secondary endpoint)

OPDIVO® + YERVOY®		Lenvatinib/sorafenib
36%	vs	13%
(n=335; 95% CI: 31-42)		(n=333; 95% CI: 10-17)

DOR‖ (Secondary endpoint)
Median DOR

OPDIVO® + YERVOY®		Lenvatinib/sorafenib
34.3 months	vs	12.9 months
(n=122; 95% CI: 22.6-47.7)		(n=44; 95% CI: 10.2-33.9)

* Vs investigator's choice of lenvatinib/sorafenib in CheckMate 9DW.[3,4]
† CheckMate 9DW was an open-label, randomised, phase 3 trial that enrolled patients aged ≥18 years with unresectable HCC without prior systemic therapy. They were randomly assigned 1:1 to receive OPDIVO® 1 mg/kg + YERVOY® 3 mg/kg Q3W for up to 4 doses, followed by OPDIVO® 480 mg Q4W (n=335) or investigator's choice of either oral lenvatinib or sorafenib (n=333). Primary endpoint was OS; Secondary endpoints included ORR, DOR and time to symptom deterioration. Median follow-up was 52.5 months (range: 44.0-66.1).[3,4]
‡ Study was not designed to independently compare OPDIVO® + YERVOY® vs lenvatinib or OPDIVO® + YERVOY® vs sorafenib.[3,4]
§ Among 325 patients treated with lenvatinib or sorafenib, 275 patients (85%) received lenvatinib, and 50 patients (15%) received sorafenib.[3,4]
¶ Responses achieved in ORR and DOR assessed by BICR based on RECIST v1.1.[3,4]
# ORR includes CR (primary analysis: 7% vs 2%; extended analysis: 8% vs 2%) and PR (primary analysis: 29% vs 11%; extended analysis: 28% vs 11%).[3,4]
‖ In confirmed responders.[4]

1L=first-line; BICR=blinded independent central review; CI=confidence interval; CR=complete response; DOR=duration of response; HCC=hepatocellular carcinoma; HR=hazard ratio; ORR=objective response rate; OS=overall survival; PR=partial response; Q3W=every 3 weeks; Q4W=every 4 weeks; RECIST v1.1=Response Evaluation Criteria in Solid Tumours version 1.1; u/aHCC=unresectable or advanced HCC.

References: 1. OPDIVO® (nivolumab) Hong Kong Prescribing Information. **2.** YERVOY® (ipilimumab) Hong Kong Prescribing Information. **3.** Yau T, et al. Nivolumab plus ipilimumab versus lenvatinib or sorafenib as first-line treatment for unresectable hepatocellular carcinoma (CheckMate 9DW): an open-label, randomised, phase 3 trial. Lancet. 2025;405(10492):1851-1864. **4.** Galle PR, et al. Nivolumab plus ipilimumab vs lenvatinib or sorafenib as first-line treatment for unresectable hepatocellular carcinoma: 4-year follow-up of CheckMate 9DW. Oral presentation at ASCO GI 2026. Abstract LBA479.

OPDIVO® YERVOY®

Please scan to read full prescribing information.

Bristol Myers Squibb™

Bristol-Myers Squibb Pharma (HK) Ltd.
Room 3001-3002, 30/F, Windsor House,
311 Gloucester Road, Causeway Bay, Hong Kong
Tel: (852) 2510 6188 Fax: (852) 2510 6199

735E-HK-2600039 10/9/2026

VERZENIO® DELIVERS
NEW BREAKTHROUGH OVERALL SURVIVAL DATA

Verzenio® abemaciclib
A Lilly Medicine



SHE'S ON TRACK FOR THE EXECUTIVE BOARD

NOT RECURRENCE

In node-positive, high-risk HR+/HER2- EBC,*
Verzenio® is proven to increase survival and **deliver long-lasting protection** from recurrence with 2 years of treatment, so you can help give **her a future of opportunity.**[†,1,2]

In monarchE cohort 1

Verzenio® is the first CDK4/6 inhibitor with a proven overall survival benefit in the curative setting and 2 years of treatment[*,†,1,2]

Increasing overall survival benefit seen at 7 years[†]

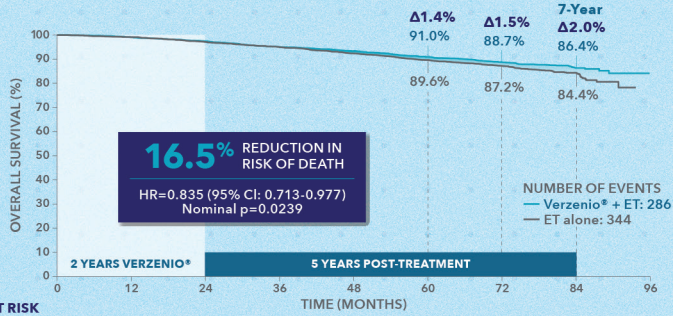

NUMBER AT RISK									
Verzenio® + ET	2555	2381	2290	2186	2123	2030	1798	423	0
ET alone	2565	2416	2305	2211	2117	2005	1753	431	0

Kaplan-Meier curve depicting OS rates at 7 years in Cohort 1 for the monarchE phase 3 global trial.

In monarchE cohort 1

Verzenio® delivers 7 years of sustained IDFS & DRFS benefits and 2 years of treatment[*,2]

- At the 7-year IDFS analysis, **77.0% of patients remained recurrence-free with Verzenio® + ET** vs 70.1% with ET alone (HR=0.726 [95% CI: 0.648-0.815]; nominal p<0.0001).[2]
- At the 7-year DRFS analysis, **79.5% of patients remained recurrence-free to incurable metastatic disease with Verzenio® + ET** vs 74.0% with ET alone (HR=0.736 [95% CI: 0.651-0.832]; nominal p<0.0001).[2]

[*]Verzenio® in combination with ET (AI or tamoxifen) is indicated for the adjuvant treatment of adult patients with HR+/HER2-, node-positive EBC at a high risk of recurrence. High-risk EBC in Cohort 1 was defined as patients who had ≥4 positive nodes or 1–3 positive nodes and tumors that were ≥5 cm, histological Grade 3—or both.[1,2]

[†]A statistically significant OS benefit was seen in the ITT population. Following regulatory consultation at the primary IDFS analysis, the OS analysis plan was amended to increase final events from 390 to 650 to ensure ≥5 years' follow-up. Verzenio® is approved for Cohort 1 (91% of ITT); OS analysis in this subpopulation was not powered or alpha-controlled.[1,2]

Indication:
Early Breast Cancer
Verzenio® in combination with endocrine therapy is indicated for the adjuvant treatment of adult patients with hormone receptor (HR)-positive, human epidermal growth factor receptor 2 (HER2)-negative, node-positive early breast cancer at high risk of recurrence. In pre- or perimenopausal women, aromatase inhibitor endocrine therapy should be combined with a luteinising hormone-releasing hormone (LHRH) agonist.[1]

Abbreviations:
AI: aromatase inhibitor; CDK4/6: cyclin-dependent kinase 4 and 6; CI: confidence interval; EBC: early breast cancer; ET: endocrine therapy; HER2-: human epidermal growth factor receptor 2-negative; HR: hazard ratio; HR+: hormone receptor-positive; IDFS: invasive disease-free survival; ITT: intent-to-treat; OS: overall survival.

References:

1. Johnston S, Martin M, O'Shaughnessy J, et al. Overall Survival with Abemaciclib in Early Breast Cancer. Ann Oncol. 2025. doi:10.1016/j.annonc.2025.10.005.
2. Verzenio® Hong Kong Prescribing Information.

Lilly
A MEDICINE COMPANY

Eli Lilly Asia, Inc.
Unit 3203-3206, 32/F, Chubb Tower, Windsor House, 311 Gloucester Road, Causeway Bay, Hong Kong
Tel: (852) 2572 0160 Fax: (852) 2572 7893 http://www.lilly.com.hk/

PP-AL-HK-0588 11/2025

| © 2025 Eli Lilly Asia, Inc. All rights reserved.

Scan to access the full Prescribing Information of Verzenio®

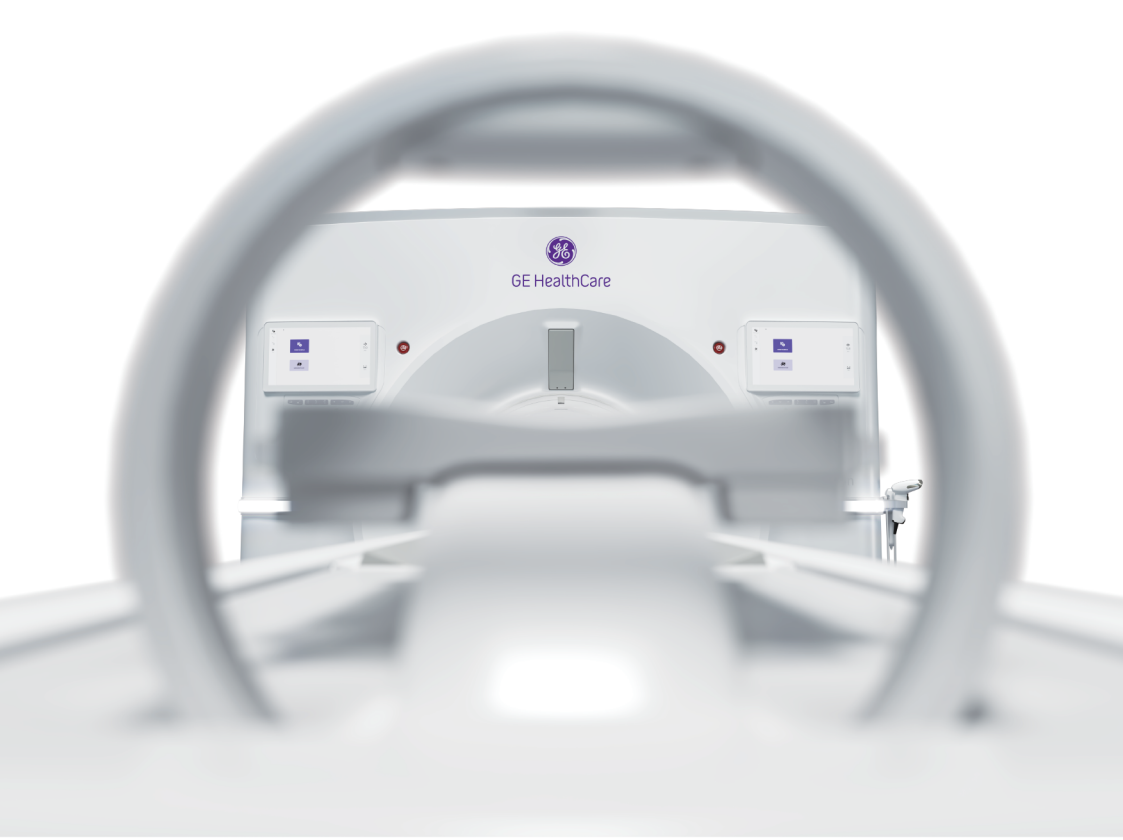

We’re committed to help solve healthcare’s toughest challenges

Delivering precision care through innovation

We're creating a world where healthcare has no limits. We believe the future of healthcare is precise, personal, and connected - and build integrated solutions to help solve for the industry's greatest challenges to enable better outcomes and improve the lives of patients and clinicians. With over 130 years of delivering innovative solutions and topping the FDA’s list of AI-enabled medical devices , we're helping transform the way hospitals and healthcare systems operate and empowering clinicians to make therapies more accurate and effective.

Visit our website https://www.gehealthcare.com
for more information

GE HealthCare

© 2026 GE HealthCare. GE is a trademark of General Electric Company used under trademark license.



5.6 MONTHS mPFS in 2L+ mTNBC patients^*†[2,3]

(95% CI, 4.3-6.3) with TRODELVY® vs. 1.7 months (95% CI, 1.5-2.6) with chemotherapy; HR=0.41 (95% CI, 0.32-0.52) P<0.001

Indications

TRODELVY® is indicated for the treatment of adult patients with unresectable locally advanced or metastatic triple-negative breast cancer (mTNBC) who have received two or more prior systemic therapies, at least one of them for metastatic disease.[1]

TRODELVY® is indicated for the treatment of adult patients with unresectable locally advanced or metastatic hormone receptor (HR)-positive, human epidermal growth factor receptor 2 (HER2)-negative (IHC 0, IHC 1+ or IHC 2+/ISH–) breast cancer who have received endocrine-based therapy and at least two additional systemic therapies in the metastatic setting.[1]

^without brain metastases *ASCENT was an international, Phase 3, multicentre, open-label, randomised trial of patients with unresectable locally advanced or metastatic TNBC (N=529). Patients were randomised 1:1 to receive TRODELVY® 10 mg/kg IV on Days 1 and 8 every 21 days, or single-agent chemotherapy of the physician's choice (eribulin, vinorelbine, gemcitabine, or capecitabine). The primary endpoint was PFS in patients without brain metastases at baseline (68% of the overall study population), as measured by BICR based on RECIST v1.1 criteria; secondary endpoints included PFS (ITT population), OS, objective response rate, duration of response, time to response, safety and quality of life.[2,3] †The primary analysis population consisted of patients without known brain metastases at baseline (n=468).[3]

2L+=second-line, 2L+=second-line and beyond; ADC=antibody-drug conjugate; BICR=blinded independent central review; CI=confidence interval; HER2-=human epidermal growth factor receptor 2-negative; HR=hazard ratio; HR+=hormone receptor-positive; IHC=immunohistochemistry; ISH=in situ hybridisation; ITT=intent-to-treat; IV=intravenous; mBC=metastatic breast cancer; mOS=median overall survival; mPFS=median progression-free survival; mTNBC=metastatic triple-negative breast cancer; OS=overall survival; PFS=progression-free survival; RECIST=Response Evaluation Criteria in Solid Tumors; TNBC=triple-negative breast cancer.

TROPiCS-02 was a global, randomised, open-label, multicentre, Phase 3 study of TRODELVY® (n=272) vs single-agent chemotherapy of physician's choice (eribulin, capecitabine, gemcitabine, or vinorelbine; n=271) randomized 1:1 in patients with locally recurrent inoperable or metastatic HR+/HER2- BC. Primary endpoint is PFS by masked independent central view per RECIST v1.1; key secondary endpoints included OS, objective response rate and patient-reported outcomes[4]

References: 1. TRODELVY® Hong Kong Full Prescribing Information (HK-SEP23-US-FEB23). **2.** Bardia, A. et al. *New England Journal of Medicine* 384, 1529–1541 (2021). **3.** Bardia, A. et al. Presented in American Society of Clinical Oncology Annual Meeting. Poster 1071 (2022). **4.** Ruga HS, *et al. Lancet* 2023; 402:1423-33.

TRODELVY® Abbreviated Prescribing Information (Version: HK-SEP23-US-FEB23)

Presentation: Each vial contains 180 mg of Sacituzumab govitecan. Off-white to yellowish lyophilized powder in a single-dose vial.
Indications: TRODELVY is indicated for the treatment of adult patients with (1) unresectable locally advanced or metastatic triple-negative breast cancer (mTNBC) who have received two or more prior systemic therapies, at least one of them for metastatic disease; (2) unresectable locally advanced or metastatic hormone receptor (HR)-positive, human epidermal growth factor receptor 2 (HER2)-negative (IHC 0, IHC 1+ or IHC 2+/ISH-) breast cancer who have received endocrine-based therapy and at least two additional systemic therapies in the metastatic setting.

Dosage: Adults: The recommended dosage of TRODELVY is 10 mg/kg administered as an intravenous infusion once weekly on Days 1 and 8 of 21-day treatment cycles. Continue treatment until disease progression or unacceptable toxicity. Do not administer TRODELVY at doses greater than 10 mg/kg. Withhold or discontinue TRODELVY to manage severe neutropenia or severe non-neutropenic toxicity. Elderly: (1) Patients with TNBC: No overall differences in safety and effectiveness were observed between these patients and younger patients; (2) Patient with HR+/HER2- breast cancer: No overall differences in effectiveness were observed between these patients and younger patients. There was a higher discontinuation rate due to adverse reactions in patients aged ≥ 65 years compared with younger patients. Renal impairment: Pharmacokinetic analyses in patients treated with TRODELVY did not identify an effect of mild to moderate renal impairment (CLcr 30-89 mL/min) on the pharmacokinetics of sacituzumab govitecan. Renal elimination is known to contribute minimally to the excretion of SN-38, the small molecule moiety of sacituzumab govitecan. There are no data on the pharmacokinetics of sacituzumab govitecan in patients with severe renal impairment (CLcr 15-29 mL/min) or end-stage renal disease (CLcr < 15 mL/min). Hepatic impairment: No adjustment to the starting dosage is required when administering TRODELVY to patients with mild hepatic impairment. The safety of TRODELVY in patients with moderate (total bilirubin > 1.5 to 3.0 × ULN) or severe (total bilirubin > 3.0 × upper limit of normal [ULN]) hepatic impairment has not been established. TRODELVY has not been tested in patients with AST or ALT > 3 ULN without liver metastases, or AST or ALT > 5 ULN with liver metastases. No recommendations can be made for the starting dosage in these patients. Paediatric population: The safety and efficacy in children and adolescents aged less than 18 years not yet been established.

Contraindications: severe hypersensitivity reaction to TRODELVY.

Warnings and Precautions: Neutropenia: Withhold TRODELVY for absolute neutrophil count below 1500/mm^3 on Day 1 of any cycle or neutrophil count below 1000/mm^3 on Day 8 of any cycle. Withhold TRODELVY for neutropenic fever. Monitor blood cell counts periodically during treatment. Consider granulocyte-colony stimulating factor for secondary prophylaxis. Initiate anti-infective treatment in patient with febrile neutropenia without delay. Dose modifications may be required due to neutropenia. Diarrhea: Withhold TRODELVY for Grade 3-4 diarrhea at the time of scheduled treatment administration and resume when resolved to ≤Grade 1. At the onset of diarrhea, evaluate for infectious causes and if negative, promptly initiate loperamide, 4 mg initially followed by 2 mg with every episode of diarrhea for a maximum of 16 mg daily. Discontinue loperamide 12 hours after diarrhea resolves. Additional supportive measures (e.g., fluid and electrolyte substitution) may also be employed as clinically indicated. Patients who exhibit an excessive cholinergic response to treatment with TRODELVY (e.g., abdominal cramping, diarrhea, salivation, etc.) can receive appropriate premedication (e.g., atropine) for subsequent treatments. Hypersensitivity and Infusion-Related Reactions: Premedication for infusion reactions in patients receiving TRODELVY is recommended. Have medications and emergency equipment to treat infusion-related reactions, including anaphylaxis, available for immediate use when administering TRODELVY. Closely monitor patients for hypersensitivity and infusion-related reactions during each TRODELVY infusion and for at least 30 minutes after completion of each infusion. Permanently discontinue TRODELVY for Grade 4 infusion-related reactions. Nausea and Vomiting: Premedicate with a two or three drug combination regimen (e.g., dexamethasone with either a 5-HT3 receptor antagonist or an NK1 receptor antagonist as well as other drugs as indicated) for prevention of chemotherapy-induced nausea and vomiting (CINV). Withhold TRODELVY doses for Grade 3 nausea or Grade 3-4 vomiting at the time of scheduled treatment administration and resume with additional supportive measures when resolved to ≤Grade 1. Additional antiemetics and other supportive measures may also be employed as clinically indicated. All patients should be given take-home medications with clear instructions for prevention and treatment of nausea and vomiting. Increased Risk of Adverse Reactions in Patients with Reduced Uridine Diphosphate-glucuronosyl Transferase 1A1 (UGT1A1) Activity: Closely monitor patients with known reduced UGT1A1 activity for adverse reactions. Withhold or permanently discontinue TRODELVY based on clinical assessment of the onset, duration and severity of the observed adverse reactions in patients with evidence of acute early-onset or unusually severe adverse reactions, which may indicate reduced UGT1A1 enzyme activity. Embryo-Fetal Toxicity: Advise pregnant women and females of reproductive potential of the potential risk to a fetus. Advise females of reproductive potential to use effective contraception during treatment with TRODELVY and for 6 months after the last dose. Advise male patients with female partners of reproductive potential to use effective contraception during treatment with TRODELVY and for 3 months after the last dose.

Adverse reactions: Refer to warning and precautions for Neutropenia, Diarrhea, Hypersensitivity and Infusion-related reactions and Nausea and Vomiting. In this pooled safety population, the most common (> 25%) adverse reactions including laboratory abnormalities were decreased leukocyte count, decreased neutrophil count, decreased hemoglobin, diarrhea, nausea, decreased lymphocyte count, fatigue, alopecia, constipation, increased glucose, decreased albumin, vomiting, decreased appetite, decreased creatinine clearance, increased alkaline phosphatase, decreased magnesium, decreased potassium, and decreased sodium.

Drug interactions: UGT1A1 inhibitors, UGT1A1 inducers.

Before prescribing, please consult full prescribing information which is available upon request.
TRODELVY is a registered trademark of Gilead Sciences, Inc., or its related companies.

GILEAD
Creating Possible

Gilead Sciences Hong Kong Limited
Room 2603, 26/F., Hysan Place, 500 Hennessy Road,
Causeway Bay, Hong Kong
Tel: +852 3129 2000 Fax: +852 2856 2611

TRODELVY®
sacituzumab govitecan
180 mg powder for concentrate for solution for infusion

HK-TRO-0153_V1 12/09/2025

Jemperli
(dostarlimab) Injection 500 mg

Let their light *Shine Longer*

All-comers indication now approved



16 months mOS improvement[1*]

Broad disease characteristics included in the trial[2†]

~1-year mPFS[3‡]

Manageable safety profile[1§]

INDICATION

- **JEMPERLI is indicated in combination with carboplatin and paclitaxel for the treatment of adult patients with primary advanced or recurrent endometrial cancer (EC) and who are candidates for systemic therapy.[3]**

*HR compared with CP alone, 0.69; 95% CI, 0.54–0.89; p=0.0002.[1] †Carcinosarcoma and serous adenocarcinoma were included in the trial. P53 subgroup analysis is also available.[2] ‡ HR compared with CP alone, 0.64; 95% CI, 0.51–0.80; p<0.0001.[3] §No new safety signals were observed with additional follow up.[1]
Abbreviations: **CP**, carboplatin + paclitaxel; **EC**, endometrial cancer; **HR**, hazard ratio; **mOS**, median overall survival; **mPFS**, median progression-free survival.

References: 1. Powell MA, et al. Overall survival in patients with primary advanced or recurrent endometrial cancer treated dostarlimab plus chemotherapy in Part 1 of the ENGOT–EN6-NSGO/GOC-3031/RUBY trial. Presented at the Society of Gynecologic Society (SGO) 2024 Annual Meeting on Women's Cancer; 16–18 March 2024; San Diego, US. **2.** Mirza MR, et al. Dostarlimab + Chemotherapy for the Treatment of Primary Advanced or Recurrent Endometrial Cancer: Analysis of Progression-Free Survival and Overall Survival Outcomes by Molecular Classification in the ENGOT-EN6-NSGO/GOG-3031/RUBY Trial. Presented at: ESMO Congress 2023; 20–24 October 2023; Madrid, Spain. **3.** JEMPERLI. Hong Kong Prescribing Information. Version: HK67364_Jemperli concentrate solution for infusion (clean)_20250529. GSK.

Safety information for Jemperli (Dostarlimab)
Immune-related adverse reactions, which may be severe or fatal, can occur. While immune-related adverse reactions usually occur during treatment with PD-1/PD-L1 blocking antibodies, symptoms can also manifest after discontinuation of treatment. Early identification and management of immune-related adverse reactions are essential to ensure use of PD-1/PD-L1 blocking antibodies. Monitor for symptoms and signs of immune-related adverse reactions. Evaluate clinical chemistries, including liver tests and thyroid function tests, at baseline and periodically during treatment.

Trademarks are owned by or licensed to the GSK group of companies.
The material is for the reference and use by Hong Kong healthcare professional only.

Safety Statement:
For adverse event reporting, please call GlaxoSmithKline Limited at (852) 3189 8989 (Hong Kong),
or report via online Patient safety reporting form: https://gsk.public.reportum.com/.

GSK

@2025 GSK group of companies or its licensor.
PM-HK-DST-LBND-250002 (06/2027)
Date of preparation: 07/2025

GlaxoSmithKline Limited
Suites 1004-10, 10/F, Tower 6, The Gateway,
9 Canton Road, Tsimshatsui, Kowloon,
Hong Kong
Tel: (852) 3189 8989

Please scan the QR code for the full Prescribing Information.

Please read the full prescribing information prior to administration.

Dotarem®

Gadoteric acid

Guerbet

THE 1ST MACROCYCLIC GBCA* ON THE MARKET[1]



STABILITY and experience

MORE THAN

170

MILLION DOSES

ADMINISTERED GLOBALLY

Scan here for Dotarem® (Gadoteric acid) Summary of Product Characteristics

Information on the product may vary from country to country, for more information, please refer to your local product information.

*Gadolinium Based Contrast Agent

1. Runge VM., *et al.* The developmental history of the gadolinium chelates as intravenous contrast media for magnetic resonance. *Invest Radiol.* 2011.Dec;46(12):807-16. **2.** Data on file, Guerbet internal data (2022, market research). **3.** Port M., *et al.* Efficiency, thermodynamic and kinetic stability of marketed gadolinium chelates and their possible clinical consequences: a critical review. *Biometals.* 2008.21(4):469-490. **4.** Frenzel T., *et al.* Stability of Gadolinium-Based Magnetic Resonance Imaging Contrast Agents in Human Serum at 37°C. *Invest Radiol.* 2008.Dec;43(12):817-288. **5.** Dotarem® CCDS -V3- February 2018. **6.** Data on file, Guerbet internal data (2024, Q1, Global sales data). Data based on sales estimation and annual results (1989-2024, Q1). **7.** Braun J., *et al.* Baseline characteristics, diagnostic efficacy, and peri-examinational safety of IV gadoteric acid MRI in 148,489 patients. *Acta Radiol.* 2020.Jul;61(7):910-920. **8.** Soyer P., *et al.* Observational study on the safety profile of gadoterate meglumine in 35,499 patients: The SECURE study. *J Magn Reson Imaging.* 2017.Apr;45(4):988–997. **9.** Chang DH., et al. Safety of gadoterate meglumine in over 1600 children included in the prospective observational SECURE study. *Acta Radio.* 2019. Nov;60(11):1450–1456. **10.** Maravilla K., *et al.* Comparison of Gadoterate Meglumine and Gadobutrol in the Diagnosis of Primary Brain Tumors: A Double-Blind Randomized Controlled Intraindividual Crossover Study (the REMIND Study). *AJNR Am J Neuroradiol.* 2017.Sept;38(9):1681-1688.

Trusted by radiologists[2], Dotarem® by Guerbet, a flagship brand known for its high stability[3,4] over 35 years of experience[1,5], with more than 170 million doses administered worldwide[6], delivering effective[7-10] MR contrast-enhanced examination.

P2400278B - April 2024

RYBREVANT® (amivantamab)
Injection for IV Use | 350 mg/7 mL (50 mg/mL)

+

LAZCLUZE® (lazertinib)
Tablets | 240 mg/80 mg

COMBINED TARGET* to Change the Game in 1L cEGFRm Advanced NSCLC[1]



NCCN (Category 1) :
RYBREVANT® + LAZCLUZE® is the Only Chemo Free Combination Preferred Regimen in 1L cEGFRm Advanced NSCLC[1]

In Ami+Laz arm, among participants who received 6 or more months of amivantamab (n=101)[2]

2%
Acquired MET amplifications[2]

0%
Acquired EGFR C797s Mutations[2]

*LAZCLUZE®, in combination with RYBREVANT®, is indicated for the first-line treatment of adult patients with locally advanced or metastatic non-small cell lung cancer (NSCLC) with epidermal growth factor receptor (EGFR) exon 19 deletions or exon 21 L858R substitution mutations

Abbreviation: 1L: First line; Ami+Laz: Amivantamab and Lazertinib; cEGFR: common EGFR mutation, MET: Mesenchymal-epidermal transition factor gene; NCCN: National Comprehensive Cancer Network

Reference: 1. NCCN Clinical Practice Guidelines in Oncology for Non-Small Cell Lung Cancer V.5.2026. **2.** Hayashi H, et al. Long-Term Impact of First-Line Amivantamab Plus Lazertinib Versus Osimertinib on Mechanisms of Acquired Resistance in MARIPOSA: A Brief Report, Journal of Thoracic Oncology. 10.894, April 28,2026

Scan to read RYBREVANT® & LAZCLUZE® Abbreviated Prescribing Information

CP-184733-Jun 2026

Johnson & Johnson (Hong Kong) Ltd.
13/F Tower 1, Grand Century Place, 193 Prince Edward Road West,
Mongkok, Hong Kong
Tel: 2736 1711 Fax: 2736 1926
©2026 Johnson & Johnson (HK) Ltd.

Johnson&Johnson

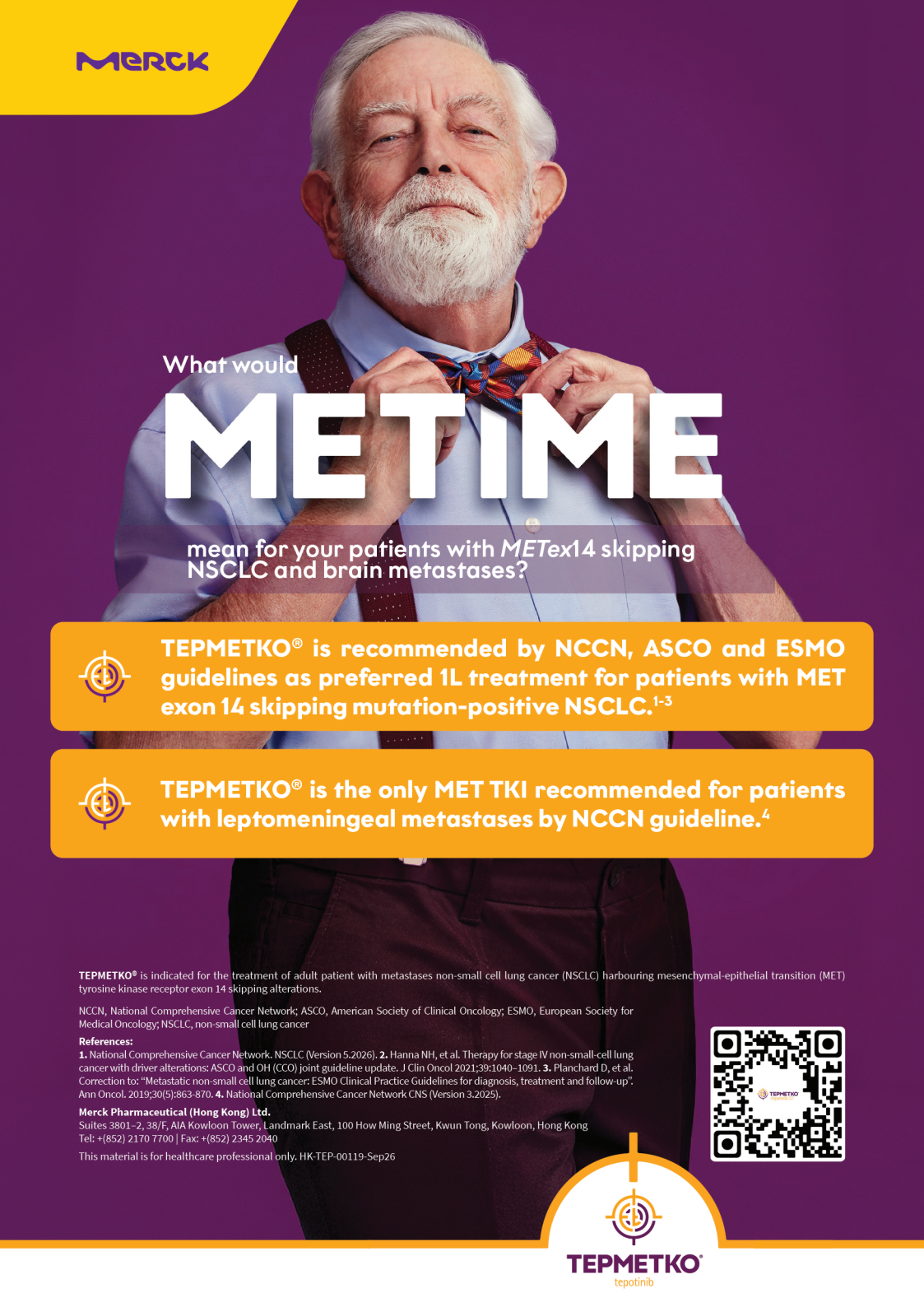

TEPMETKO® is indicated for the treatment of adult patient with metastases non-small cell lung cancer (NSCLC) harbouring mesenchymal-epithelial transition (MET) tyrosine kinase receptor exon 14 skipping alterations.

NCCN, National Comprehensive Cancer Network; ASCO, American Society of Clinical Oncology; ESMO, European Society for Medical Oncology; NSCLC, non-small cell lung cancer

References:
1. National Comprehensive Cancer Network. NSCLC (Version 5.2026). **2.** Hanna NH, et al. Therapy for stage IV non-small-cell lung cancer with driver alterations: ASCO and OH (CCO) joint guideline update. J Clin Oncol 2021;39:1040–1091. **3.** Planchard D, et al. Correction to: "Metastatic non-small cell lung cancer: ESMO Clinical Practice Guidelines for diagnosis, treatment and follow-up". Ann Oncol. 2019;30(5):863-870. **4.** National Comprehensive Cancer Network CNS (Version 3.2025).

Merck Pharmaceutical (Hong Kong) Ltd.
Suites 3801–2, 38/F, AIA Kowloon Tower, Landmark East, 100 How Ming Street, Kwun Tong, Kowloon, Hong Kong
Tel: +(852) 2170 7700 | Fax: +(852) 2345 2040

This material is for healthcare professional only. HK-TEP-00119-Sep26

KEYTRUDA®
(pembrolizumab) Injection 100 mg

A KEY TO ADVANCING CARE ACROSS CERTAIN WOMEN'S CANCERS



Treatment including KEYTRUDA® (pembrolizumab) is approved for **7 women's cancer** indications in Hong Kong[1]

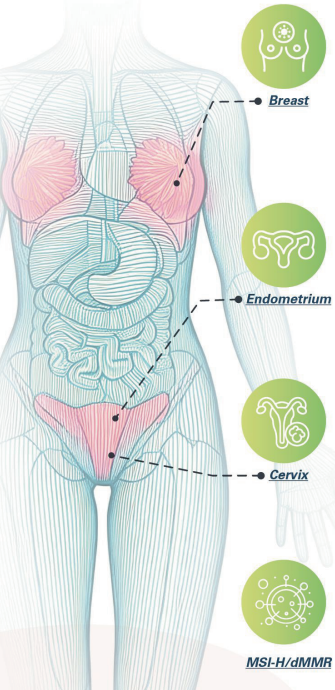

Triple-Negative Breast Cancer

KEYNOTE-522 Neoadjuvant/Adjuvant use

KEYTRUDA is indicated for the treatment of patients with **high-risk early-stage triple-negative breast cancer (TNBC)** in combination with chemotherapy as **neoadjuvant treatment**, and then continued as a single agent **as adjuvant treatment after surgery.**

KEYNOTE-355 1L use

KEYTRUDA, in combination with **chemotherapy**, is indicated for the treatment **of locally recurrent unresectable or metastatic TNBC** in adults whose tumors express **PD-L1 with a CPS ≥10** and who have not received prior chemotherapy for metastatic disease.

Endometrial Cancer

KEYNOTE-868 1L use

KEYTRUDA, in combination with **carboplatin and paclitaxel,** is indicated for the **first-line treatment** of primary advanced or recurrent endometrial carcinoma in adults who are candidates for systemic therapy.

KEYNOTE-775 for following prior system therapy in any setting

KEYTRUDA, in combination with **lenvatinib**, is indicated for the treatment of adult patients with advanced endometrial carcinoma that is **mismatch repair proficient (pMMR) or not MSI-H** as determined by a validated test, who have disease progression **following prior systemic therapy** in any setting and **are not candidates for curative surgery or radiation.**

Cervical Cancer

KEYNOTE-A18 for locally advanced cervical cancer

KEYTRUDA, in combination with **chemoradiotherapy** (external beam radiation therapy followed by brachytherapy), is indicated for the treatment of **FIGO 2014 Stage III-IVA locally advanced cervical cancer** in adults who have not received prior definitive therapy.

KEYNOTE-826 1L use

KEYTRUDA, in combination with **chemotherapy, with or without bevacizumab,** is indicated for the treatment of patients with **persistent, recurrent, or metastatic cervical cancer** whose tumors express **PD-L1 (CPS ≥1)** as determined by a validated test.

Microsatellite Instability-High or Mismatch Repair Deficient Cancer

KEYNOTE-158 2L use

KEYTRUDA, as **monotherapy**, is indicated for the treatment of adult patients with unresectable or **metastatic, microsatellite instability-high** (MSI-H) or **mismatch repair deficient** (dMMR) **solid tumors** that have progressed following prior treatment and who have no satisfactory alternative treatment options.

Abbreviations: 1L=first-line; 2L=second-line; CPS=combined positive score; dMMR=mismatch repair deficient; FIGO=International Federation of Obstetrics and Gynaecology; MSI-H=microsatellite instability-high; PD-L1=programmed death-ligand 1; pMMR=mismatch repair proficient; TNBC=triple-negative breast cancer.

References: 1. KEYTRUDA. Hong Kong Prescribing Information.

Selected Safety Information for KEYTRUDA (pembrolizumab):
Contraindications: None **Precautions:** •Immune-mediated pneumonitis •Immune-mediated colitis •Immune-mediated hepatitis and hepatotoxicity •Immune-mediated endocrinopathies •Immune-mediated nephritis and renal dysfunction •Immune-mediated Dermatologic Adverse Reactions •Other immune-mediated adverse reactions •Infusion-related reactions (including hypersensitivity and anaphylaxis) •Complications of allogeneic HSCT in patients after or prior to treatment with KEYTRUDA treatment •Increased mortality in patients with multiple myeloma when KEYTRUDA is added to a thalidomide analogue and dexamethasone •Embryo-fetal toxicity. **Adverse Events:** Most common adverse reactions (reported in ≥20% of patients) were: •KEYTRUDA as a single agent: fatigue, musculoskeletal pain, rash, diarrhea, pyrexia, cough, decreased appetite, pruritus, dyspnea, constipation, pain, abdominal pain, nausea and hypothyroidism; • KEYTRUDA in combination with chemotherapy or chemoradiotherapy: fatigue/asthenia, nausea, constipation, diarrhea, decreased appetite, rash, vomiting, cough, dyspnea, pyrexia, alopecia, peripheral neuropathy, mucosal inflammation, stomatitis, headache, weight loss, abdominal pain, arthralgia, myalgia, insomnia, palmar-plantar erythrodysesthesia, urinary tract infection, and hypothyroidism; •KEYTRUDA in combination with chemotherapy and bevacizumab: peripheral neuropathy, alopecia, anemia, fatigue/asthenia, nausea, neutropenia, diarrhea, hypertension, thrombocytopenia, constipation, arthralgia, vomiting, urinary tract infection, rash, leukopenia, hypothyroidism, and decreased appetite; •KEYTRUDA in combination with axitinib: diarrhea, fatigue/asthenia, hypertension, hepatotoxicity, hypothyroidism, decreased appetite, palmar-plantar erythrodysesthesia, nausea, stomatitis/mucosal inflammation, dysphonia, rash, cough, and constipation; •KEYTRUDA in combination with lenvatinib: hypothyroidism, hypertension, fatigue, diarrhea, musculoskeletal disorder, nausea, decreased appetite, vomiting, stomatitis, weight loss, abdominal pain, urinary tract infection, proteinuria, constipation, headache, hemorrhagic events, palmar-plantar erythrodysesthesia, dysphonia, rash, hepatotoxicity, and acute kidney injury; •KEYTRUDA in combination with enfortumab vedotin: rash, peripheral neuropathy, fatigue, pruritus, diarrhea, alopecia, weight loss, decreased appetite, dry eye, nausea, constipation, dysgeusia, and urinary tract infection.
For detailed precautions and adverse events, please consult the full prescribing information. HK-KEY-01117 Nov/2025

To access to full SSI, please scan the QR code

MERCK SHARP & DOHME (ASIA) LTD.
27/F Lee Garden Two, 28 Yun Ping Road, Causeway Bay, Hong Kong.
TEL: (852) 3971 2800 FAX: (852) 2834 0756
Copyright © 2026 Merck & Co., Inc., Rahway, NJ, USA and its affiliates. All rights reserved.
HK-KEY-01164 Jan/2026

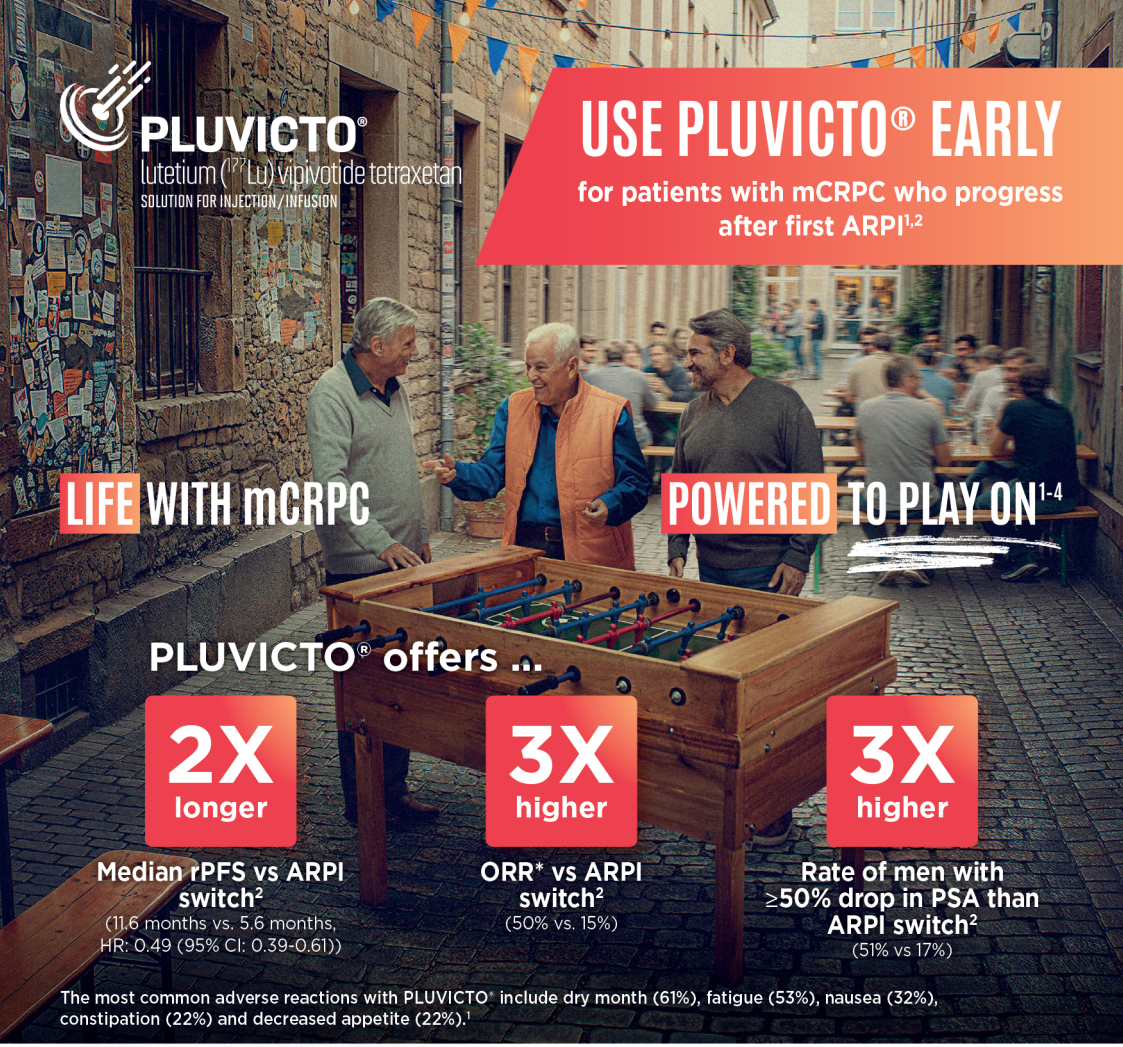

PLUVICTO® offers ...

2X longer

Median rPFS vs ARPI switch[2]
(11.6 months vs. 5.6 months, HR: 0.49 (95% CI: 0.39-0.61))

3X higher

ORR* vs ARPI switch[2]
(50% vs. 15%)

3X higher

Rate of men with ≥50% drop in PSA than ARPI switch[2]
(51% vs 17%)

The most common adverse reactions with PLUVICTO* include dry month (61%), fatigue (53%), nausea (32%), constipation (22%) and decreased appetite (22%).[1]

*Objective response rate was defined as the proportion of patients with measurable soft tissue disease at baseline who achieved either a complete soft tissue response or a partial soft tissue response, assessed per RECIST v1.1 and excluding bone lesion progression.[2]

Abbreviations: ARPI, androgen receptor pathway inhibitor; CI, confidence interval; HR, hazard ratio; mCRPC, metastatic castration-resistant prostate cancer; ORR, overall response rate; PSA, prostate-specific antigen; PSMA, prostate-specific membrane antigen; RECIST, Response Evaluation Criteria in Solid Tumors; rPFS, radiographic progression-free survival

References: 1. PLUVICTO Hong Kong Prescribing Information. Revision date: 15 Jun 2026. **2.** Morris MJ, et al. Lancet. 2024 Sep;404(10459):1227–1239. **3.** Sartor O, et al. N Engl J Med. 2021 Sep;385(12):1091–1103. **4.** Fizazi K, et al. Lancet Oncol. 2025 Jul;26(7):948–959.

Pluvicto Solution for Injection/ Infusion 1000 MBq/mL
Important note: Before prescribing, consult full prescribing information.
Presentation: One mL of solution contains 1 GBq (1,000 MBq) (27 mCi) of lutetium (177Lu) vipivotide tetraxetan at the date and time of calibration. The total amount of radioactivity per single-dose vial is 7.4 GBq (7,400 MBq) (200 mCi) at the date and time of administration. Indications: PLUVICTO is indicated for the treatment of adult patients with prostate-specific membrane antigen (PSMA)-positive metastatic castration-resistant prostate cancer (mCRPC) who have been treated with androgen receptor pathway inhibitor (ARPI) therapy, and are considered appropriate to delay taxane-based chemotherapy, or have received prior taxane-based chemotherapy. Dosage and administration: Adults: ♦ The recommended Pluvicto dose is 7.4 GBq (7,400 MBq) (200 mCi) intravenously every 6 weeks for a total of 6 doses. ♦ Perform hematology and kidney function tests before and during treatment with Pluvicto. Special populations: ♦ Renal impairment: No dose adjustment for patients with mild to moderate renal impairment. ♦ Hepatic impairment: No dose adjustment. ♦ Geriatric patients (65 years of age or older): No dose adjustment. ♦ Pediatric patients (below 18 years of age): Safety and effectiveness have not been established. Contraindications: None. Warnings and precautions: ♦ Risk from radiation exposure: Pluvicto contributes to patient's overall long-term radiation exposure. Long-term cumulative radiation exposure is associated with increased risk for cancer. Minimize radiation exposure to patients, medical personnel, and others during and after treatment. Encourage patients to increase oral fluids and void as often as possible. Explain necessary radioprotection precautions that patient should follow to minimize radiation exposure to others. ♦ Myelosuppression: Perform hematology laboratory tests. Withhold, dose reduce, or permanently discontinue and clinically manage as deemed appropriate based on severity. ♦ Renal toxicity: Advise patients to remain well hydrated and urinate frequently before and after administration. Perform kidney function laboratory tests. Withhold, dose reduce, or permanently discontinue based on severity. Pregnancy, lactation, females and males of reproductive potential: ♦ Pregnancy and Lactation: Safety and efficacy have not been established in females as Pluvicto is not indicated for use in females. Radioactive emissions, including those from Pluvicto, can cause fetal harm. ♦ Females and males of reproductive potential: Male contraception: Advise male patients not to father a child and to use condoms for intercourse during treatment with Pluvicto and for 14 weeks after the last dose. Infertility: Pluvicto may cause infertility. Adverse drug reactions: ≥10%: decreased lymphocytes, decreased hemoglobin, fatigue, dry mouth, decreased platelets, decreased estimated glomerular filtration rate, nausea, decreased neutrophils, decreased calcium, decreased sodium, increased aspartate aminotransferase, increased alkaline phosphatase, arthralgia, decreased appetite, increased potassium, constipation, back pain, vomiting, diarrhoea, increased magnesium, weight decreased, peripheral edema, abdominal pain, bone pain, urinary tract infection, increased sodium. <10%: dysgeusia, abdominal pain, peripheral edema, headache, acute kidney injury, weight decreased, urinary tract infection, dry eye, dizziness, dry skin, oral fungal infection, gastroesophageal reflux disease, pyrexia, vertigo, stomatitis, dysphagia, esophagitis, pancytopenia, and bone marrow failure, decreased potassium. Interactions: None. Packs: 1000 MBq of lutetium (177Lu) vipivotide tetraxetan Legal classification: P1S1S3 Reference: US PI Apr 2026 (including 2024-PSB/GLC-1429-s & CDS v2.3) Revision Date: 10 Aug 2026

This material for PLUVICTO® is approved for use only in Hong Kong. Prescribing information may vary depending on local approval in each country/location.
Before prescribing any product, always refer to local materials such as the prescribing information and/or the Summary of Product Characteristics (SPC).
For Hong Kong Healthcare Professionals' reference and sole use only.

FA-11804262 | OCT 2026

NOVARTIS

Novartis Pharmaceuticals (HK) Ltd
Suite 2303-08, 23/F, 1111 King's Road,
Taikoo Shing, Hong Kong
Tel: (852) 2882 5222 Fax: (852) 2577 0274

PLUVICTO®
lutetium (177Lu) vipivotide tetraxetan
SOLUTION FOR INJECTION / INFUSION

LORVIQUA®
LORLATINIB

Pfizer

>7 years of PFS in 1L *ALK*+ aNSCLC[1]

Beyond Survival Toward Chronic Care

LORVIQUA: Elevate your expectations



LORVIQUA is indicated for the treatment of adult patients with metastatic non-small cell lung cancer (NSCLC) whose tumours are anaplastic lymphoma kinase (ALK)-positive.[2]

*For a substantial fraction of patients.

Actor portrayal. Image for representation purposes only.

Pfizer

Pfizer Corporation Hong Kong Limited
21/F, Kerry Centre, 683 King's Road, Quarry Bay, Hong Kong
Tel: +852 2811 9711 | Fax: +852 2579 0599 | Website: www.pfizer.com.hk
Copyright @ 2026 Pfizer Corporation Hong Kong Limited.
All Rights Reserved.
PP-LOR-HKG-0146 SEP 2026

ww.pfi.sr/Jrn

PLEASE SCAN TO ACCESS FULL PRESC RIBING INFORMATION OF LORVIQUA
The QR code/URL links to the latest Prescribing Information approved by the Department of Health in Hong Kong and may not be effective and the same as presented in the actual product package.
For Healthcare Professionals Only.

PHILIPS



Smart. Simple.
Spectral.

Verida
Spectral CT

PHAROS Study: Updated OS, PFS and ORR With Braftovi®+ Mektovi® in NSCLC[1,*]



In **treatment naïve** patients (n=59)

median OS
47.6 MONTHS
(95% CI, 31.3-NE)

4-years OS
49%
(95% CI, 35-62)

median PFS by IRR
30.4 MONTHS
(95% CI, 15.7-NE)

In **previously treated** patients (n=39)

median OS
22.7 MONTHS
(95% CI, 14.1-32.6)

4-years OS
31%
(95% CI, 16-47)

median PFS by IRR
9.3 MONTHS
(95% CI, 6.2-24.8)

In **treatment naïve** patients (n=59)

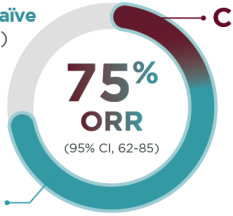

In **previously treated** patients (n=39)

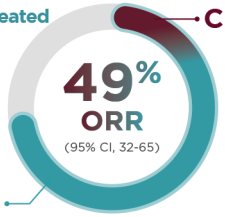

*Updated data (cutoff date March 14, 2025) with median follow-up for overall survival of 52.3 months in treatment naïve patients[1]

Study design: This was a single-arm, open-label, multicenter, phase II study included 98 patients with treatment-naïve or previously treated BRAF V600E-mutant mNSCLC received oral encorafenib 450 mg once daily plus oral binimetinib 45 mg twice daily in 28-day cycles.

Abbreviations: CI=confidence interval; CR=complete response; mNSCLC=metastatic non-small-cell lung cancer; NSCLC=non-small-cell lung cancer; ORR=objective response rate; OS=overall survival; PFS=progression-free survival; PR=partial response

Reference: 1. Johnson ML, et al. Updated Overall Survival Analysis From the Phase II PHAROS Study of Encorafenib Plus Binimetinib in Patients With BRAFV600E-Mutant Metastatic Non–Small Cell Lung Cancer. J Clin Oncol. 2025;JCO2502023.

Abbreviated Prescribing Information (PI) for BRAFTOVI BRAFTOVI CAPSULES 50 mg/ BRAFTOVI CAPSULES 75 mg. Approved name of the active ingredient: Encorafenib. Indications: BRAFTOVI is indicated 1) in combination with binimetinib for the treatment of adult patients with unresectable or metastatic melanoma with a BRAF V600 mutation or 2) in combination with cetuximab, for the treatment of adult patients with metastatic colorectal cancer (CRC) with a BRAF V600E mutation, who have received prior systemic therapy. Dosage and method of administration: Melanoma: For oral use, swallowed whole with water, with or without food. 450 mg once daily (6 x 75 mg capsules), using in combination with binimetinib. Colorectal Cancer: For oral use, swallowed whole with water, with or without food. 300 mg once daily (4 x 75 mg capsules) using in combination with cetuximab. Both: Continue treatment until patient no longer deriving benefit or development of unacceptable toxicity. To manage adverse reactions, consider dose reduction, temporary interruption or treatment discontinuation of encorafenib and/or binimetinib/ cetuximab according to respective full PI. Contraindications: Hypersensitivity to the active substance or to any of the excipients. Special warnings and precautions for use: BRAF mutation testing, left ventricular dysfunction (LVD), haemorrhages, ocular toxicities, QT prolongation, new primary malignancies (cutaneous and non-cutaneous), liver function abnormalities. Limited data: patients who previously progressed on a prior BRAF inhibitor for unresectable or metastatic melanoma with a BRAF V600 mutation; and patients with a BRAF V600 mutant melanoma with brain metastases. Moderate or severe hepatic impairment: not recommended. Severe renal impairment: use with caution. Children and adolescents aged <18 years: no data. Pregnancy: Category D. Use additional or alternative method to hormonal contraception. Lactation: consider benefit of breastfeeding for child versus benefit of drug to mother. Visual disturbances or other adverse effects may affect ability to drive or operate machinery. See full PI. Interactions: Avoid strong CYP3A4 inhibitors, including ritonavir, itraconazole, clarithromycin, telithromycin, posaconazole, grapefruit juice. Co-administer moderate CYP3A4 inhibitors with caution, including amiodarone, erythromycin, fluconazole, diltiazem, amprenavir, imatinib. Consider alternatives to moderate or strong CYP3A4 inducers, including carbamazepine, rifampicin, phenytoin, St. John's Wort. Co-administer CYP3A4 substrates (e.g., hormonal contraceptives), UGT1A1 substrates, and transporter substrates (OCT2, OAT1, OAT3, OATP1B1, OATP1B3 and BCRP) with caution. Undesirable effects: Encorafenib in combination with binimetinib (Melanoma): Most common adverse reactions (>25%): fatigue, nausea, diarrhoea, vomiting, retinal detachment, abdominal pain, arthralgia, blood CK increased and myalgia. Other very common: (≥10%–<25%): anaemia, neuropathy peripheral, dizziness, headache, visual impairment, haemorrhage, hypertension, constipation, hyperkeratosis, rash, dry skin, pruritus, alopecia, pain in extremity, back pain, pyrexia, peripheral oedema, GGT increased, transaminase increased. Encorafenib in combination with cetuximab (Colorectal Cancer): Most common adverse reactions (≥25%): fatigue, nausea, diarrhoea, dermatitis acneiform, abdominal pain, arthralgia/musculoskeletal pain, decreased appetite, rash and vomiting; other very common (≥10%–<25%): haemorrhage, headache, pyrexia, constipation, myopathy/muscular disorder, melanocytic naevus, dry skin, pruritus, neuropathy peripheral, insomnia, back pain, pain in extremity. Other adverse reactions: see full PI. Before initiating treatment with encorafenib-containing regimen for melanoma or colorectal cancer, please review PI for binimetinib or cetuximab respectively. Date of Revision: September 2022. Please refer to BRAFTOVI full PI dated March 2022 for more information. For healthcare professionals only.

Abbreviated Prescribing Information for MEKTOVI MEKTOVI TABLETS 15 mg. Approved name of the active ingredient: Binimetinib. Indication MEKTOVI is indicated in combination with encorafenib is indicated for the treatment of adult patients with unresectable or metastatic melanoma with a BRAF V600 mutation. Dosage and method of administration: For oral use, swallowed whole with water, with or without food. 45 mg (3 x 15 mg tablets) twice daily, corresponding to total daily dose of 90 mg approximately 12 hours apart. Continue treatment until patient no longer deriving benefit or development of unacceptable toxicity. To manage adverse reactions, consider dose reduction, temporary interruption or treatment discontinuation of binimetinib and/or encorafenib according to full PI. Contraindications: Hypersensitivity to the active substance or to any of the excipients. Special warnings and precautions for use: BRAF mutation testing, left ventricular dysfunction (LVD), haemorrhages, ocular toxicities (not recommended in patients with history of RVO), CK elevation and rhabdomyolysis, hypertension, venous thromboembolism, pneumonitis/ interstitial lung disease, new primary malignancies (cutaneous and non-cutaneous), liver function abnormalities, lactose intolerance. Limited data: patients who previously progressed on a prior BRAF inhibitor for unresectable or metastatic melanoma with a BRAF V600 mutation; and patients with a BRAF V600 mutant melanoma with brain metastases. Moderate or severe hepatic impairment: not recommended. Children and adolescents aged <18 years: no data. Pregnancy: Category D. Use additional or alternative method to hormonal contraception. Lactation: consider benefit of breastfeeding for child versus benefit of drug to mother. Visual disturbances or other adverse effects may affect ability to drive or operate machinery. See full PI. Interactions: Caution on binimetinib exposure when co-administering with UGT1A1 inducers (e.g., rifampicin and phenobarbital), UGT1A1 inhibitors (e.g., indinavir, atazanavir, sorafenib), CYP1A2 inducers (e.g., carbamazepine and rifampicin) and P-gp transporter inducers (e.g., St. John's wort or phenytoin). Caution on exposure of CYP1A2 (e.g., duloxetine, theophylline) or OAT3 (e.g., pravastatin or ciprofloxacin)-sensitive substrates when co-administering with binimetinib. Undesirable effects: Encorafenib in combination with binimetinib: Most common adverse reactions (>25%): fatigue, nausea, diarrhoea, vomiting, retinal detachment, abdominal pain, arthralgia, blood CK increased and myalgia. Other very common: (≥10%–<25%): anaemia, constipation, neuropathy peripheral, dizziness, headache, visual impairment, haemorrhage, hypertension, constipation, hyperkeratosis, rash, dry skin, pruritus, alopecia, pain in extremity, back pain, pyrexia, peripheral oedema, GGT increased, transaminase increased. Other adverse reactions: see full PI. Before initiating binimetinib treatment with encorafenib, please review full PI for encorafenib. Date of Revision: Oct 2022. Please refer to MEKTOVI full prescribing information dated March 2022 for more information. For healthcare professionals only.

HK_NSCLC_202512_03

Laboratoires Pierre Fabre
New ways to care

Pierre Fabre Dermo-Cosmetique Hong-Kong Limited
10/F, Luk Kwok Centre, 72 Gloucester Road, Wan Chai, Hong Kong
Tel: +852 3428 5310

BRAFTOVI® (encorafenib) + MEKTOVI® (binimetinib)

View Online Article

5 years
of real-world experience



TECENTRIQ®
atezolizumab

CONFIDENCE FOLLOWS EXPERIENCE

Reflect on how the trusted SoC for 1L uHCC, backed by 5 years of real-world experience, improves survival outcomes for a wide range of patients[1-11]

TECENTRIQ® + AVASTIN®

Indication:

TECENTRIQ, in combination with bevacizumab, is indicated for the treatment of patients with unresectable or metastatic hepatocellular carcinoma (HCC) who have not received prior systemic therapy

References:

1. Gordan JD, et al. (2024) J Clin Oncol, 42:1830–1850.
2. Singal AG, et al. (2023) Hepatology, 78(6):1922–1965.
3. Vogel A, et al. (2025) Ann Oncol. In press.
4. Reig M, et al. (2022) J Hepatol, 76:681–693.
5. ILCA (2020) Systemic Therapy Guidance.
6. Sangro B, et al. (2025) J Hepatol, 82:315–374.
7. Finn R, et al. (2020) N Engl J Med, 382:1894–1905.
8. Cheng A-L, et al. (2022) J Hepatol, 76:862–873.
9. Fulgenzi C, et al. (2022) Eur J Cancer, 175:204–213.
10. Manfredi, G. et al. (2025) JHEP Reports, https://doi.org/10.1016/ j.jhepr.2025.101431
11. D'Alessio A, et al. (2022) Hepatology, 76:1000–1012.

SoC = Standard of Care; 1L = first line; uHCC = unresectable hepatocellular carcinoma

M-HK-00002494 approved in April 2026 is valid for 2 years or until change is required in accordance with regulatory requirements, whichever comes first.

Roche Hong Kong Limited
Unit 1-2, 24/F, Central Plaza, 18 Harbour Rd, Wan Chai, Hong Kong
Tel: (852) 2723 2832

(C) 2026 Roche Hong Kong Limited. All rights reserved.

TECENTRIQ® IV Prescribing Information

TECENTRIQ® SC Prescribing Information

Avastin® Prescribing Information

SIEMENS Healthineers

NAEOTOM Alpha.Prime

The new benchmark



Built for versatile performance, NAEOTOM Alpha.Prime brings Quantum Technology and AI into clinical routine.

- A new imaging standard to support clinicians in lesion detection, characterization, and treatment planning
- AI-powered workflows speed up reading and scanning processes
- Quantum Spectral Imaging and Quantum HD resolution in single source CT in clinical routine for the first time

Scan the QR code to unlock more details!

SIEMENS Healthineers

MAGNETOM Flow. Platform

Empowering you.

Introducing MAGNETOM Flow. Platform – our next-generation 1.5T MRI platform that empowers you with a game-changing new flow for unparalleled imaging care.

- Ushering in a new sustainable era of AI-powered and helium-independent MRI
- Pioneering AI-enhanced imaging to bring high-quality results at high speed
- First fully scalable platform – with scanners in 60 and 70 cm bore sizes

Scan the QR code to unlock more details!



AuntMinnie.com THE BEST OF RADIOLOGY WINNER

DESIGN AWARD 2025

LOQTORZI®
toripalimab injection

LOQTORZI®

Unlocking More Possibilities in Oncology

First-Line Recurrent/Metastatic Nasopharyngeal Carcinoma (NPC)

The New Standard of Care

64.8 months
Median OS with LOQTORZI® + CT

33.7 months
Placebo + CT

NCCN GUIDELINES CATEGORY 1 RECOMMENDATION

NCCN **Category 1** Preferred Regimen

First-Line Advanced Esophageal Squamous Cell Carcinoma (ESCC)

Unlocking More Possibilities

29.7 %
3-Year Overall Survival Rate
LOQTORZI® + TP

19.9 %
Placebo + CT

EMA Approved Regardless of **PD-L1 Expression**

TORIPALIMAB

One Molecule. Expanding Evidence. More Possibilities for Patients.

References

Wang, Zi-Xian et al. Cancer cell vol. 40,3 (2022): 277-288.e3. doi:10.1016/j.ccell.2022.02.007
Chen YX, et al. Ann Oncol. 2026 Jul;37(7):986-998.
EMA product information (2022–2024); EMA/CHMP Loqtorzi opinion (Jul 2024) and EPAR (Sep 2024).
2025 ESMO Asia 669MO.
NCCN Clinical Practice Guidelines in Oncology, Head and Neck Cancers, v2.2026.

Abbreviations

CT, Chemotherapy; TP, Paclitaxel + Cisplatin; NPC, Nasopharyngeal Carcinoma; ESCC, Esophageal Squamous Cell Carcinoma; OS, Overall Survival; NCCN, National Comprehensive Cancer Network; EMA, European Medicines Agency; PD-1, Programmed Cell Death Protein 1; 1L, First-Line.
*CT = gemcitabine and cisplatin

TopAlliance Biosciences

Scan the QR code to learn more about TopAlliance Biosciences.

TopAlliance Biosciences Hong Kong Limited
35/F, Central Plaza, 18 Harbour Road, Wan Chai, Hong Kong
P-NPCESCC-HK-TOR-2026.10-01 valid till 2028.11

UNITED IMAGING



uAiFi · LIVE

uMR Ultra

From **Photography** to **Videography**.

Satellite Symposium:
'LIVE Imaging' MRI: Innovative Applications

Explore how real-time imaging innovation is transforming clinical possibilities, presented by a leading pioneer in the field.

Speaker:
Prof. LIANG Dong

Vice President, Shenzhen Institutes of Advanced Technology (SIAT)

🗓️ **Date:** 21 November 2026 (Sat)
⏰ **Time:** 9:10 AM – 9:30 AM
📍 **Location:** Function Room 2 (2/F)

Join us to stay at the cutting edge of medical imaging.

Hong Kong Journal of Radiology

HKJR

香港放射科醫學雜誌

Full-text articles are available at
www.hkjr.org

Online ISSN: 2307-4620

Why HKJR?

- Publishes review articles, original articles, perspectives, pictorial essays, case reports, brief communications, and letters to the Editor
- Indexed in Web of Science, EMBASE/*Excerpta Medica*, Index Copernicus and Scopus
- Publishes Chinese and English abstracts





Submit your manuscripts online
www.hkamedtrack.org/hkjr
Authors can now upload all submission components in a few easy steps and track the status of their manuscripts online.

Official Publication of
Hong Kong College of Radiologists

HKAM PRESS

AOCR 2028 HONG KONG 香港

26th Asian Oceanian Congress of Radiology

Hong Kong Welcomes You! 香港歡迎您 第26屆亞大放射學學會國際學術研討會

CONNECTING MINDS,
ADVANCING RADIOLOGY



1-4 June 2028
Thursday to Sunday

Hong Kong Convention & Exhibition Centre
Hong Kong SAR, China

www.AOCR2028.org

Organised by
Asian Oceanian Society of Radiology

Hosted by
Hong Kong College of Radiologists

Supported by
mehk Meetings & Exhibitions Hong Kong
A division of Hong Kong Tourism Board
政府資助計劃 Government-funded programme